

Anatomical Control of the Lower Nasal Width in Le Fort I Osteotomy

Control Anatómico del Ancho Nasal Inferior en Osteotomía Le Fort I

Heitor Fontes da Silva¹; Sergio Olate²; Luciana Asprino³ & Márcio de Moraes³

DA SILVA, F.; OLATE, S.; ASPRINO, L. & DE MORAES, M. Anatomical control of the lower width in Le Fort I osteotomy. *Int. J. Morphol.*, 39(2):533-537, 2021.

SUMMARY: The aim of this research is to show a simple technique to obtain control in the alar base width in Le Fort I osteotomy. The technique was used in eighteen patients submitted to maxillary impaction and/or advancements (≥ 3 mm). Inter-alar width, alar base width and right/left nostril were studied before surgery and 6 months of follow-up. Data were reported as means and standard deviations; statistical analysis was realized by t test considering a p-value <0.05 . Left nostril was modified 0.33 ± 1.03 mm, right nostril was modified 0.39 ± 0.98 mm after 6 months and inter-alar width show a decrease of 0.17 ± 1.15 mm. No statistical differences were observed between the preoperative and the postoperative measurements. Our results show this technique as effective in to obtain a stable position in nasal width.

KEY WORDS: Nasal width; Alar base; Le Fort I osteotomy; Orthognathic surgery.

INTRODUCTION

Le Fort I osteotomy (LFIO) modified the most of the facial muscle position around the nasal area and piriform rim (Ritto *et al.*, 2011). Some studies have shown significant changes in soft tissue and nasal morphology (Mansour *et al.*, 1983; Altman & Oeltjen, 2007; Tartaro *et al.*, 2008); nasal widening is commonly associated to maxillary osteotomies, being related, in some cases, to amount of skeletal movement (Rauso *et al.*, 2010).

Cinch alar suture has been used for more than 30 years to treat nasal widening; Millard Jt. *et al.* (1980) originally described the technique to correct nasal defects in the inter-alar tissue in patients with cleft lip and palate and later Collins & Epker (1982) described its use in noncleft patients. The aim of this report is to show a modified simple approach to obtain transversal control of the nasal width in LFIO osteotomy.

MATERIAL AND METHOD

Operative technique. Under nasal intubation, LFIO was

realized by intra oral approach (size between right to left second bicuspid). After LFIO fixation, was realized the width nose control as follow: a 2 mm incision in the inferolateral aspect of the nostril was performed with blade n° 15 and slightly approach with halstead tweezers (Fig. 1). After this, the submucosal tissue is identified by applying pressure on the alar area of the nose externally and observing tissue movement intraorally through the maxillary approach. Following this, the needle suture (3/0 non-absorbable nylon) is inserted from the intraoral approach through inferolateral area of nostril (the same point of the small incision) to the skin, exiting laterally to the nostril. After that, needle is reinserted into the intraoral incision through the same punctate site. The same procedure is done through the other side using the same suture. Traction is applied while the effect on the surface anatomy and the nasofacial groove is noted, to facilitate accurate placement of the cinch suture. The tension applied also varied according to the need to recreate the nasofacial groove and to ensure well-balanced facial and nasal proportion. After that, the alar base suture is judged to be adequate by a measurement realized with digital caliper and the vestibular incision was closed in a routine fashion, without performing a V-Y lip closure.

¹ Department of Oral and Maxillofacial Surgery, Piracicaba Dental School, State University of Campinas, Piracicaba (SP), Brazil.

² Department of Oral, Facial and Maxillofacial Surgery, Universidad de La Frontera, Temuco, Chile. Center of Excellence in Morphological and Surgical Studies (CEMyQ), Universidad de La Frontera, Temuco, Chile.

³ Department of Oral and Maxillofacial Surgery, Piracicaba Dental School, State University of Campinas, Piracicaba (SP), Brazil.

Case Series. Were included 18 subjects between 18 and 40 years old, under 1-piece LFIO with forward movement ≥ 3 mm, with no requirement for nasal width augmentation or reduction. Were excluded subjects with craniofacial malformations as cleft lip, subjects with facial asymmetry (≥ 5 mm chin deviation from the facial midline), subjects with facial trauma or other facial surgeries and subjects under corrective bone surgery in the nasal area (e.g. osseous recontouring at ANS) as requirement in the same surgical time. In the follow up period, patients under complication as infections or others also were excluded.

Clinical analysis and photographs (Nikon P500 digital camera Nikon, Japan) were obtained 1 week before surgery, 1 month and 6 months after the surgery; 140 cm patient-to-camera was achieved using an especial support for the camera (focal point for the picture was obtained on the tip of the nose in the frontal view). A trained operator aligned the head in normal position and the inter pupillary line was in horizontal position; no support on the head or the face was used during this process. Standardized conditions of time, light and camera was applied.

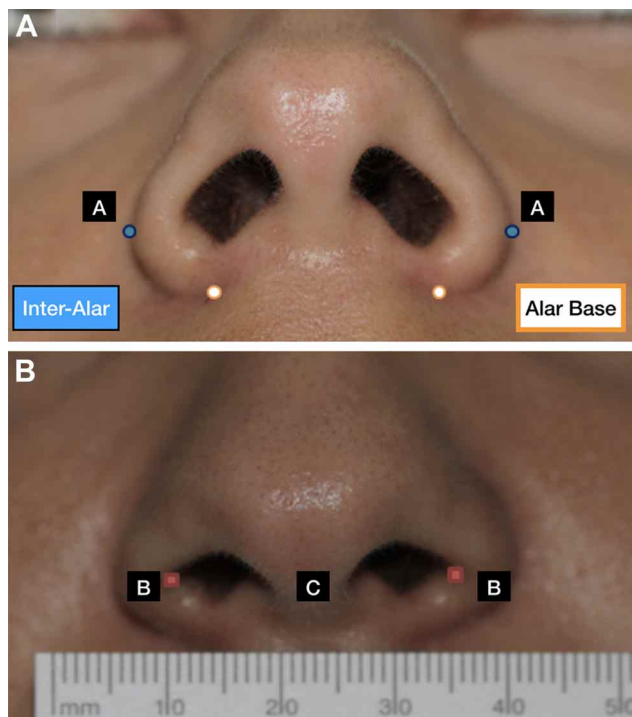


Fig 1. A) Anthropometric landmarks used for and measurements in inter-alar nasal width. "A" point in right and left side is the most lateral area of the nose. B) Landmark in the nostril and columella; "B" and "C" point is in the same line of A to A.

The transverse dimensions of the nose were measured before the surgery by an observer, and 1 month and 6 months after the surgery by another observer using sliding digital calipers. All patients were analyzed in two different positions using standardized submental oblique view and standardized frontal view (Fig. 1).

Anthropometric landmarks of the nose were selected: 1) Point A: the most lateral alar point in the left and right side, 2) the most medial alar point in the left and right side (in the same imaginary line from the point A), 3) Point C: the most lateral point of the columela in the same line that point A and B (right and left side in the same line than point A and B), and 4) Point D: the most lower and lateral point of the nose in contact with the upper lip in the right and left side (Fig. 2).

Using distance between point B to C was measured the right and left nostril; alar nasal width or inter-alar width was obtained using the distance between points left A to right A point and the alar base width was obtained using the distance between the left and right D point. Distribution of data was confirmed and statistical analysis was realized using t test considering a p value < 0.05 to obtain statistical significance

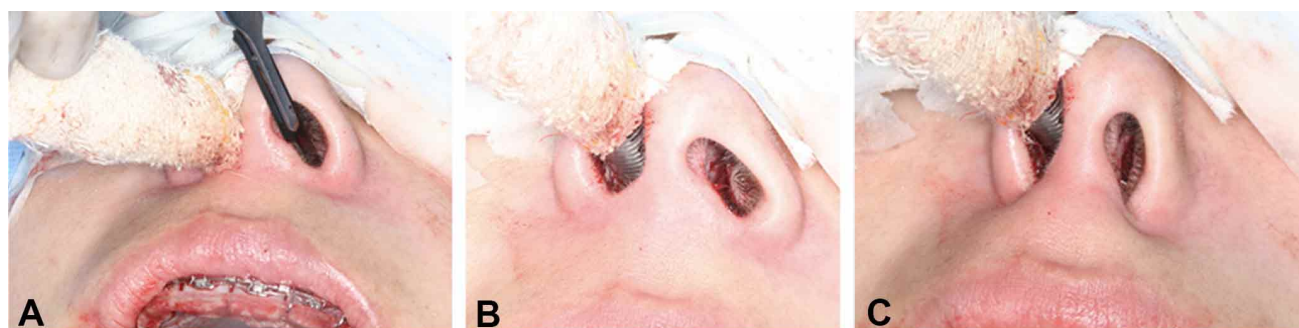

Fig 2. A) An incision in the inferolateral aspect of nostril, approximately 2 mm. This approach usually have little bleeding. B) Bilateral approach C) After bilateral approach, a traction in suture line is executed to take control of the nasal width. The knot and fixation is by intraoral approach.

RESULTS

Surgeries were planned and executed by bimaxillary approach with the aim to no change the nasal width (Table I). Symmetry in nostril was observed with 0.11 mm differences between the right and left nostril in the preoperative time; left nostril was modified 0.33 ± 1.03 mm and right nostril was modified 0.39 ± 0.98 mm after 6 months (2.7 % augmentation in the left nostril and 3.2 % augmentation in the right nostril) with no differences in the comparison ($p > 0.05$).

In term of width, the largest area of the alar zone (inter-alar width) show 0.17 ± 1.15 mm differences, showing 0.5 % augmentation from the preoperative evaluation; the alar base width showed -0.28 ± 1.13 differences, decreasing the width in -1.2 %. No statistical differences were observed between the preoperative and the postoperative measurements for inter alar or alar base width ($p > 0.05$ for the both).

DISCUSSION

The position of the facial muscles from the nasolabial area and the relations with the anterior nasal spine allows the muscles to retract laterally, which results in widening and asymmetry in some cases (Rauso *et al.*). The size of the LFIO approach, 1-piece or multiple piece maxillary osteotomy are not related to the inter-alar width, alar base width or upper lip length, however, the magnitude of the maxillary advancement is related to widening in the alar base and inter-alar (Paredes de Sousa Gil *et al.*, 2019) and nose projection show differences related to maxillary movement (Epker *et al.*, 1986; Rosen, 1988).

In case of forward maxillary movement, muscle tissue compression could be expected as well as change of the nostril size (Stella *et al.*, 1989); however, in our sequence no differences was observed in the preoperative and postoperative size of the nostril showing good results in this technique.

Table I. Distribution of 18 patients included, observing the inter-alar nasal width, nasal alar base and right and left nostril in the preoperative time

Patient	Preop		6mo FU		Difference		Preop		6mo FU		Difference		Preop		6mo FU		Difference	
	Left Nostril Width (mm)	Right Nostril Width (mm)	Left Nostril Width (mm)	Right Nostril Width (mm)	Left Nostril Width (mm)	Right Nostril Width (mm)	Left Nostril Width (mm)	Right Nostril Width (mm)	Inter Alar Width (mm)	Inter Alar Width (mm)	Inter Alar Width (mm)	Inter Alar Width (mm)	Alar Base Width (mm)	Alar Base Width (mm)	Alar Base Width (mm)	Alar Base Width (mm)	Alar Base Width (mm)	Alar Base Width (mm)
1	12	14	13	14	1	1	36	38	2	24	23	2	24	23	23	23	23	-1
2	11	11	10	11	1	1	31	31	0	21	21	0	21	21	21	21	21	0
3	9	9	10	10	0	0	34	34	0	26	25	0	26	25	25	25	25	-1
4	13	14	13	14	1	1	36	37	1	26	27	1	26	27	27	27	27	1
5	12	11	11	12	-1	1	36	37	1	22	22	1	22	22	22	22	22	0
6	13	13	13	13	0	0	35	34	-1	27	25	-1	27	25	25	25	25	-2
7	13	12	12	11	-1	-1	34	33	-1	20	20	-1	20	20	20	20	20	0
8	13	14	12	13	1	1	31	33	2	19	19	2	19	19	19	19	19	0
9	12	14	13	14	1	1	32	32	0	26	25	0	26	25	25	25	25	-1
10	12	11	11	11	0	0	30	30	0	21	22	0	21	22	22	22	22	1
11	14	15	16	15	-1	-1	33	31	-2	23	21	-2	23	21	21	21	21	-2
12	12	13	11	13	2	2	33	34	1	18	19	1	18	19	19	19	19	1
13	12	12	12	11	-1	-1	33	33	0	21	20	0	21	20	20	20	20	-1
14	11	13	11	13	2	2	32	32	0	17	19	2	17	19	19	19	19	2
15	14	13	14	13	-1	-1	34	33	-1	28	27	-1	28	27	27	27	27	-1
16	12	12	12	12	0	0	33	35	2	23	24	2	23	24	24	24	24	1
17	14	14	13	14	0	1	39	38	-1	23	22	-1	23	22	22	22	22	-1
18	14	14	14	14	0	0	28	28	0	21	20	-1	21	20	20	20	20	-1
Means	12,39	12,72	12,28	12,67	0,33	0,39	33,33	33,50	0,17	22,56	22,28	-0,28	22,56	22,28	22,28	22,28	22,28	-0,28
SD	1,29	1,53	20	-1	1,03	0,98	2,57	2,75	1,15	3,15	2,67	1,13	3,15	2,67	2,67	2,67	2,67	1,13
Difference (%)					2,7	3,2			0,5									-1,2

Type of surgery, level of the osteotomy, position of teeth, movement of the lower and/or upper jaw (Olate *et al.*, 2016; 2017), the amount of tension placed on the musculoaponeurotic suture (O’Ryan *et al.*, 1989) could affect the final position of the nose.

Subspinal osteotomy compared to routine LFI osteotomy show no differences, reporting that the most important reason for change in the nasal tip is the position of the alae (Mommaerts *et al.*, 1997). Alae position is related to the nasal width and the nasal tip projection. In our sequence, no increase in inter-alar width was observed as well as no widening of the nostril was observed.

The alar base cinch has been used for more than 30 years (Millard Jr. *et al.*; Collins & Epker); some adaptations or modifications has been proposed, but the original concepts is the same: control in the position of the nasal alae. van Loon *et al.* (2016) compared groups with our without alar cinch suture showing no differences in the postoperative evaluation. However, Raithatha *et al.* (2017) showing that the control in inter-alar width was more effective with cinch suture than no suture. Probably, its possible to speculate that alar cinch suture is sensible to the surgeon; the present technique could help surgeons to obtain safe capture of the alar tissue into the surgery being more predictable.

Stewart & Edler (2011) observed the efficacy and stability of the alar base cinch suture using submental intubation and the single V-Y closure for all the patients; the LFIO was related to 3.0mm increase (8.7 %) in the inter-alar width, and the cinch suture using single V-Y was reduced to 1.6mm (53.3 %); our experience in this 18 cases showed an increase 0.17 mm (0.5 %) in the inter-alar width and a reduction of 0.28mm (-1.2 %) in the alar base width; nostril size showed an increase of 2.7 % and 3.2 % with no statistical differences, showing control in the transversal relation of the nose.

CONCLUSION

This technique for transversal control of the nose in LFIO is effective in to maintain a stable position in the inter-alar nasal width, alar base width and nostril width in the medium-term follow-up.

DA SILVA, F.; OLATE, S.; ASPRINO, L. & DE MORAES, M. Control anatómico del ancho nasal inferior en osteotomía Le Fort I. *Int. J. Morphol.*, 39(2):533-537, 2021.

RESUMEN: el objetivo de esta investigación es presentar una técnica simple para obtener el control en el ancho de la base alar en la ejecución de una osteotomía de Le Fort I. La técnica fue usada en 18 sujetos sometidos a cirugía maxilar de ascenso y/o avance maxilar mayor (≥ 3 mm). El ancho inter-alar, el ancho de la base alar y el orificio nasal derecho e izquierdo fueron estudiados antes de la cirugía y seis meses después de la misma. Los datos fueron presentados en promedios y desviación estándar; el análisis estadístico fue realizado utilizando el t test considerando un valor de $p < 0,05$. El orificio izquierdo fue modificado en $0,33 \pm 1,03$ mm, el orificio izquierdo fue modificado en $0,39 \pm 0,98$ mm después de 6 meses y el ancho inter alar mostro una reducción de $0,17 \pm 1,15$ mm. No se observaron diferencias estadísticas entre las mediciones obtenidas previo a la cirugía y después de la cirugía. Nuestros resultados muestran que la técnica es efectiva para obtener una posición estable del ancho nasal.

PALABRAS CLAVE: Ancho nasal; Base alar; Osteotomía Le Fort I; Cirugía ortognática

REFERENCES

- Altman, J. I. & Oeltjen, J. C. Nasal deformities associated with orthognathic surgery: analysis, prevention, and correction. *J. Craniofac. Surg.*, 18(4):734-9, 2007.
- Collins, P. C. & Epker, B. N. The alar base cinch: a technique for prevention of alar base flaring secondary to maxillary surgery. *Oral Surg. Oral Med. Oral Pathol.*, 53(6):549-53, 1982.
- Epker, B. N.; Stella, J. P. & Fish, L. C. *Maxillary Deficiency. Chapter 11.* In: Epker, B. N. & Fish, L. C. (Eds.). *Dentofacial Deformities. Integrated Orthodontic and Surgical Correction.* St Louis (MO), Mosby, 1986. pp.492-538.
- Mansour, S.; Burstone, C. & Legan, H. An evaluation of soft-tissue changes resulting from Le Fort I maxillary surgery. *Am. J. Orthod.*, 84(1):37-47, 1983.
- Millard Jr., D. R. The alar cinch in the flat, flaring nose. *Plast. Reconstr. Surg.*, 65(5):669-72, 1980.
- Mommaerts, M. Y.; Abeloos, J. V.; De Clercq, C. A. & Neyt, L. F. The effect of the subspinal Le Fort I-type osteotomy on interalar rim width. *Int. J. Adult Orthodon. Orthognath. Surg.*, 12(2):95-100, 1997.
- O’Ryan, F. & Schendel, S. Nasal anatomy and maxillary surgery. II. Unfavorable nasolabial esthetics following the Le Fort I osteotomy. *Int. J. Adult Orthodon. Orthognath. Surg.*, 4(2):75-84, 1989.
- Olate, S.; Zaror, C. & Mommaerts, M. Y. A systematic review of soft-to-hard tissue ratios in orthognathic surgery. Part IV: 3D analysis - Is there evidence? *J. Craniomaxillofac. Surg.*, 45(8):1278-86, 2017.
- Olate, S.; Zaror, C.; Blythe, J. N. & Mommaerts, M. Y. A systematic review of soft-to-hard tissue ratios in orthognathic surgery. Part III: Double jaw surgery procedures. *J. Craniomaxillofac. Surg.*, 44(10):1599-606, 2016.
- Paredes de Sousa Gil, A.; Guijarro-Martínez, R.; Hass Jr., O. L.; Masià-Gridilla, J.; Valls-Ontañón, A.; de Oliveira, R. B. & Hernández-Alfaro, F. Nasolabial soft tissue effects of segmented and non-segmented Le Fort I osteotomy using a modified alar cinch technique—a cone beam computed tomography evaluation. *Int. J. Oral Maxillofac. Surg.*, 49(7):889-94, 2019.
- Raithatha, R.; Naïni, F. B.; Patel, S.; Sherriff, M. & Witherow, H. Long-term stability of limiting nasal alar base width changes with a cinch suture following Le Fort I osteotomy with submental intubation. *Int. J. Oral Maxillofac. Surg.*, 46(11):1372-9, 2017.

- Rauso, R.; Gherardini, G.; Santillo, V.; Biondi, P.; Santagata, M. & Tartaro, G. Comparison of two techniques of cinch suturing to avoid widening of the base of the nose after Le Fort I osteotomy. *Br. J. Oral Maxillofac. Surg.*, 48(5):356-9, 2010.
- Ritto, F. G.; Medeiros, P. J.; de Moraes, M. & Ribeiro, D. P. B. Comparative analysis of two different alar base sutures after Le Fort I osteotomy: randomized double-blind controlled trial. *Oral Surg. Oral Med. Oral Pathol. Oral Radiol. Endod.*, 111(2):181-9, 2011.
- Rosen, H. M. Lip-nasal aesthetics following Le Fort I osteotomy. *Plast. Reconstr. Surg.*, 81(2):171-82, 1988.
- Stella, J. P.; Streater, M. R.; Epker, B. N. & Sinn, D. P. Predictability of upper lip soft tissue changes with maxillary advancement. *J. Oral Maxillofac. Surg.*, 47(7):697-703, 1989.
- Stewart, A. & Edler, R. J. Efficacy and stability of the alar base cinch suture. *Br. J. Oral Maxillofac. Surg.*, 49(8):623-6, 2011.
- Tartaro, G.; Santagata, M.; Corzo, L. & Rauso, R. Tip upturning and maxillary advancement: the UT angle. *J. Craniofac. Surg.*, 19(5):1387-90, 2008.
- van Loon, B.; Verhamme, L.; Xi, T.; de Koning, M. J. J.; Bergé, S. J. & Maal, T. J. J. Three-dimensional evaluation of the alar cinch suture after Le Fort I osteotomy. *Int. J. Oral Maxillofac. Surg.*, 45(10):1309-14, 2016.

Correspondence to:
Prof. Sergio Olate, PhD
Universidad de La Frontera
Claro Solar 115
Temuco
CHILE

E-mail: sergio.olate@ufrontera.cl

Received: 16-12-2020

Accepted: 14-01-2021