

# Anatomical Study of the Latissimus Dorsi Muscle Flap

## Estudio Anatómico del Colgajo del Músculo Latísimo del Dorso

Amal Yousif Ahmed Alhaj Mustafa & Wardah Abdullah Alasmari

---

MUSTAFA, A. Y. A. A. & ALASMARI, W. A. Anatomical study of the latissimus dorsi muscle flap. *Int. J. Morphol.*, 40(3):562-565, 2022.

**SUMMARY:** The latissimus dorsi is a broad muscle that originates from the inferior thoracic spinous processes, thoracolumbar fascia, iliac crest, and inferior ribs. It inserts on the inferior aspect of the intertubercular groove of the humerus through a thin tendon. The study was conducted on 10 cadavers (7 male and 3 female). These specimens were dissected and examined to study the gross anatomical characteristics of the latissimus dorsi muscle. The dimensions of the latissimus dorsi muscle and its surface area were measured in all the cadavers. The branching pattern of the thoracodorsal vessels was recorded. The pedicle length and caliper were measured using Vernier calipers. On the 20 dissected sides, the thoracodorsal artery was found to be one of the terminal branches of the subscapular artery that originates in the axillary region. In 19 (95 %) cases, the thoracodorsal artery terminated in a bifurcation, giving off a medial and a lateral branch. The average size of the elevated flap of the latissimus dorsi muscle was 18 cm × 36 cm. The average pedicle length was 9.5 cm (range: 5 cm-14 cm), and the average diameter at its origin was 2.5 mm (range: 1.5 mm-3.5 mm). The average diameter of the vena comitans was 3.3 mm. The current study focuses on the anatomical features of the latissimus dorsi muscle and its blood supply to increase the success rate of operations in clinical practice.

**KEY WORDS:** latissimus dorsi muscle; thoracodorsal artery; thoracolumbar fascia.

---

## INTRODUCTION

The latissimus dorsi is a broad muscle that originates from the inferior thoracic spinous processes, thoracolumbar fascia, iliac crest, and inferior ribs. It inserts on the inferior aspect of the intertubercular groove of the humerus through a thin tendon. Functionally, it has been referred to as the back pec, serving to adduct the arm, largely assisting the teres major and pectoralis major muscles. The vascular supply to the latissimus dorsi muscle is classically described by Mathes & Nahai (1981) as a type V muscle, with a single dominant pedicle arising from the thoracodorsal system and smaller segmental perforators from the posterior intercostal and lumbar arteries. For the use of the pedicle latissimus dorsi flap in head and neck reconstruction, the terminal latissimus dorsi branch of the thoracodorsal artery serves as the primary pedicle. Although there can be significant variability in the relationship between take-offs for the angular and serratus anterior branches from the thoracodorsal artery, the terminal latissimus dorsi branch reliably enters the deep surface of the muscle approximately 6 cm distal to the inferior scapular margin (Heitmann *et al.*, 2003). In

addition, the thoracodorsal artery can be dissected out of the latissimus muscle to create a longer pedicle and ease the arc of rotation.

The use of the latissimus dorsi muscle or myocutaneous flap is considered an ideal solution in many conditions, as it provides reliable, well vascularized soft tissue coverage to an extensive surface area. Additionally, it could provide a functional unit to compensate for flexion and extension deficits of the elbow resulting from the traumatic loss of the effective muscle power for elbow flexion or extension (Quillen *et al.*, 1978; Ariyan, 1979; Bartlett *et al.*, 1981; Mathes & Nahai, 1981; Rowsell *et al.*, 1984, 1986; Stern & Carey, 1988; Al-Qattan, 2001; Heitmann *et al.*, 2003). The latissimus dorsi flap has the largest potential surface area and the greatest arc of rotation of any pedicled musculocutaneous flap used in head and neck reconstruction. Together, these factors make the pedicled latissimus dorsi flap unique, as well as its capacity to cover extremely large or distal defects. Additionally, it has a unique potential to be

two separately vascularized musculocutaneous paddles on one main vascular pedicle as provided by the early division of the thoracodorsal artery and the vein into superior and lateral branches within the latissimus muscle. The flap donor site is outside the radiation fields for head and neck cancer and thus provides no risk of irradiated tissue. The skin of this donor site often has less hair than the pectoralis flap donor site. The donor scar is less conspicuous than that of the pectoralis major for flaps of equal size. This is especially noteworthy in women who do not experience breast changes produced with the latissimus dorsi flap. The rate of latissimus dorsi muscle donor-site morbidity is acceptable and compares favorably with that of the pectoralis major or the trapezius muscles. Despite these benefits, the use of this flap as a donor site has failed to gain widespread acceptance largely because of concerns regarding patient positioning and flap survival. Modifications to the surgical technique can improve the reliability and versatility of this flap (Quillen *et al.*, 1978; Ariyan, 1979).

## MATERIAL AND METHOD

This study was conducted at the Department of Human Anatomy, Faculty of Medicine, Umm Al-Qura University, Makkah, Saudi Arabia, between October 2021 and January 2022. Ethical clearance was obtained from the Umm Al-Qura University Ethical Committee. There was no evidence of trauma, malformation, rotator cuff, or other pathology of the shoulder girdle. The study was conducted on 10 adult formalin-fixed cadavers (7 male and 3 female). Their ages ranged between 45 and 77 years old. These specimens were dissected and examined to study the gross anatomical characteristics of the latissimus dorsi muscle. Ten cadavers underwent total dissection, beginning with an oblique incision that was made in the axilla, following the lateral edge of the latissimus dorsi. Twenty latissimus dorsi muscles were extensively dissected and studied. Fascial connections between the latissimus and other muscles of the shoulder girdle were noted. The dimensions of the latissimus dorsi muscle and its surface area were measured in all the cadavers. The thoracodorsal artery was identified, and its course was studied and traced to its origin from the dorsal scapular artery. The branching pattern was recorded. The pedicle length and caliper were measured using Vernier calipers. The caliper was measured at the most suitable site for use in surgical anastomosis. All measurements and data obtained were registered, recorded and photographed.

## RESULTS

In all twenty dissected specimens, the thoracodorsal artery was found to be one of the terminal branches of the subscapular artery that originates in the axillary region. It runs inferomedial to the lateral margin of the scapula and then courses posteriorly, passing deep into the latissimus dorsi muscle (Fig. 1).

In this study, and along its course, the thoracodorsal artery gave rise to several cutaneous and muscular branches that supply the adjacent latissimus dorsi, serratus anterior, subscapularis and teres major muscles as well as the skin in the axillary region. In 19 (95 %) cases, the thoracodorsal artery terminated in a bifurcation, giving off a medial and a lateral branch (Fig. 2). The remaining specimen was divided into three branches. These branches run within the fascia of the latissimus dorsi muscle. The larger lateral branch ran parallel to the lateral margin of the muscle, while the medial branch coursed along its superior margin.

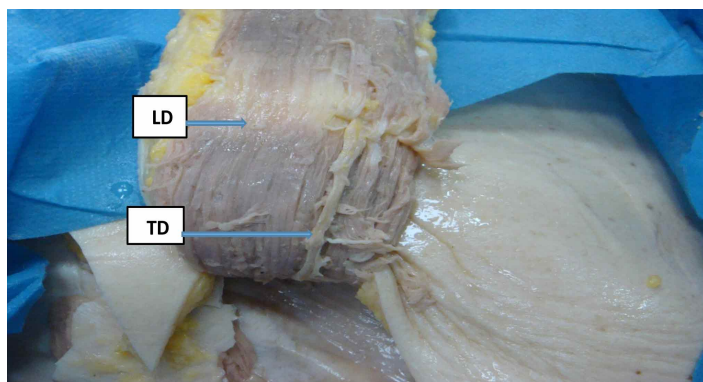


Fig. 1. The thoracodorsal artery (TD) courses deep into the latissimus dorsi (LD) muscle.

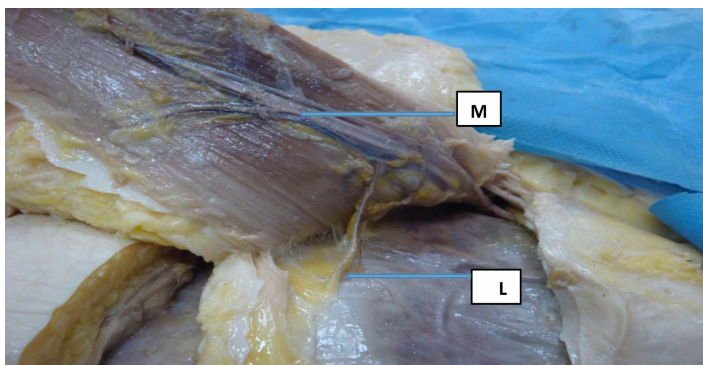


Fig. 2. Showing the lateral (L) and medial (M) branches of the thoracodorsal artery.

The blood supply to the latissimus dorsi flap was provided by the thoracodorsal artery and venae comitantes via perforators through the muscle (Fig. 3).

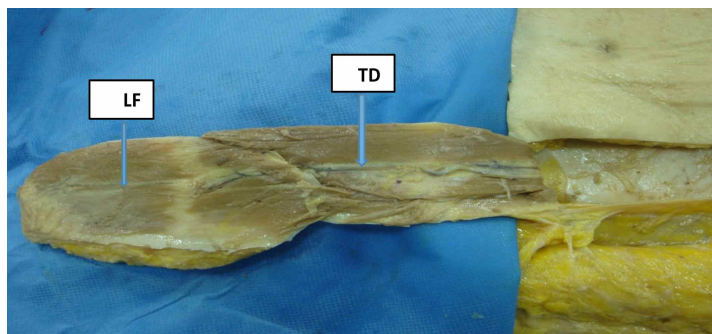


Fig. 3. Showing the latissimus dorsi flap (LF) with the thoracodorsal artery (LD).

In this study, the average size of the elevated flap of the latissimus dorsi muscle was 18 cm × 36 cm.

The pedicle length of the thoracodorsal artery was measured in 20 dissected cadavers. The average pedicle length was 9.5 cm (range: 5 cm-14 cm), and the average diameter of the thoracodorsal artery at its origin was 2.5 mm (range: 1.5 mm-3.5 mm).

In 18 (90 %) dissected cadavers, venous drainage was provided by a pair of venae comitantes that united to form a common vessel at their draining point on the subscapular vein (Fig. 4). The average diameter was 3.3 mm.

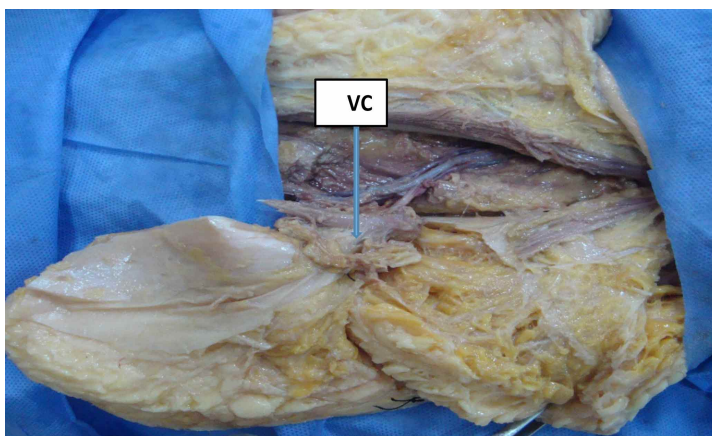


Fig. 4. Showing the thoracodorsal artery and the vena comitantes (VC).

## DISCUSSION

In our study, in all twenty dissected specimens, the thoracodorsal artery was found to be one of the terminal branches of the subscapular artery that originates in the axillary region. There is a slight discrepancy with the finding of Rowsell *et al.* (1984), who

found that in the majority of cases (94 %), the thoracodorsal artery was found to be a branch of the subscapular artery. In the remaining 6 % of cases, the thoracodorsal artery was a branch of either the axillary artery (5 %) or the lateral thoracic artery (1 %).

In this study, we found that in 19 (95 %) dissected specimens, the thoracodorsal artery terminated in a bifurcation, giving off a medial and a lateral branch. These branches run within the fascia of the latissimus dorsi muscle. The larger lateral branch ran parallel to the lateral margin of the muscle, while the medial branch coursed along its superior margin. This is consistent with the finding of Rowsell *et al.* (1984), who reported that in all 20 (100 %) dissections examined in his study, the thoracodorsal artery divided into two primary muscular branches immediately upon reaching the deep surface of the latissimus dorsi muscle; these branches remained on the deep surface of the muscle for the entire course, thus confirming the findings of Schusterman *et al.* (1980), Bartlett *et al.* (1981) and Tobin *et al.* (1981a).

In this study, the average size of the elevated flap of the latissimus dorsi muscle was 18 cm × 36 cm. The average pedicle length was 8.5 cm (range: 5 cm-14 cm), and the average diameter of the thoracodorsal artery at its origin was 2.8 mm (range: 1.5 mm-3.5 mm). Rowsell *et al.* (1984) reported that the mean length of the thoracodorsal artery is approximately 128 mm and that the proximal-distal diameter ratio is approximately  $3.44 \pm 1.49$ . In this study, our finding showed that the average length is shorter than that of Tansatit *et al.* (2007), who reported that the average length of the thoracodorsal artery, from the axillary artery to the inner surface of the muscle where the perforator disappeared, was  $16.2 \pm 2.0$  cm (range: 12.0-21.8 cm) (mean ± SD), and the average diameter of the thoracodorsal artery at its bifurcation was  $3.0 \pm 0.8$  mm (range: 2.0-5.0 mm).

In 18 (90 %) dissections, venous drainage was provided by a pair of venae comitantes that united to form a common vessel at their draining point on the subscapular vein. The average diameter was 3.3 mm. These values were slightly lower than those reported by Tansatit *et al.* (2007) who reported that the latissimus dorsi muscle is a thin, flat muscle measuring approximately 20 cm x 40 cm. The thoracodorsal artery and vein course superiorly along the thoracic wall on the deep surface of the latissimus

dorsi toward the axilla. The artery is 1.5-44 mm in diameter, and the vein is usually 2.5-4.5 mm in diameter. The muscular pedicle can be between 6-16 cm in length, with an average length of 9 cm (Tobin *et al.*, 1981b).

## CONCLUSION

This study focuses on the anatomical features of the thoracodorsal artery to increase the success rate of operations and increase the support of the clinical use of latissimus dorsi muscle flaps.

---

**MUSTAFA, A. Y. A. A. & ALASMARI, W. A.** Estudio anatómico del colgajo del músculo dorsal ancho. *Int. J. Morphol.*, 40(3):562-565, 2022.

El músculo latísimo del dorso se origina en los procesos espinosos de las vértebras torácicas inferiores, la fascia toracolumbar, la cresta ilíaca y las costillas inferiores y se inserta en el surco intertubercular del húmero a través de un delgado tendón. El estudio se realizó en 10 cadáveres (7 mujeres y 3 hombres). Estos especímenes fueron disecados y examinados para estudiar las características anatómicas macroscópicas del músculo latísimo del dorso. En todos los cadáveres se midieron las dimensiones del músculo y su superficie. Se registró el patrón de ramificación de los vasos toracodorsales. La longitud del pedículo y el calibre se midieron con paquímetro Vernier. En los veinte lados disecados, se encontró que la arteria toracodorsal era una de las ramas terminales de la arteria subescapular que se originaba en la región axilar. En 19 (95 %) casos, la arteria toracodorsal terminaba bifurcándose en dos ramas, una rama medial y otra lateral. El tamaño promedio del colgajo elevado del músculo latísimo del dorso era de 18 cm × 36 cm. La longitud promedio del pedículo era de 9,5 cm (rango: 5 cm-14 cm), y el diámetro promedio en su origen era de 2,5 mm (rango: 1,5 mm-3,5 mm). El diámetro medio de la vena comitans era de 3,3 mm. El estudio actual se centra en las características anatómicas del músculo latísimo del dorso y su irrigación para aumentar la tasa de éxito de las operaciones en la práctica clínica.

**PALABRAS CLAVE: Músculo latísimo del dorso; Arteria toracodorsal; Fascia toracolumbar.**

---

## REFERENCES

- Al-Qattan, M. M. Severe, traumatic soft-tissue loss in the antecubital fossa and proximal forearm associated with radial and/or median nerve palsy: nerve recovery after coverage with a pedicled latissimus dorsi muscle flap. *Ann. Plast. Surg.*, 46(2):125-9, 2001.
- Ariyan, S. The pectoralis major myocutaneous flap. A versatile flap for reconstruction in the head and neck. *Plast. Reconstr. Surg.*, 63(1):73-81, 1979.
- Bartlett, S. P.; May Jr, J. W. & Yaremchuk, M. J. The latissimus dorsi muscle: a fresh cadaver study of the primary neurovascular pedicle. *Plast. Reconstr. Surg.*, 67(5):631-6, 1981.
- Heitmann, C.; Guerra, A.; Metzinger, S. W.; Levin, L. S. & Allen, R. J. The thoracodorsal artery perforator flap: anatomic basis and clinical application. *Ann. Plast. Surg.*, 51(1):23-9, 2003.
- Mathes, S. J. & Nahai, F. Classification of the vascular anatomy of muscles: experimental and clinical correlation. *Plast. Reconstr. Surg.*, 67(2):177-87, 1981.
- Quillen, C. G.; Shearin Jr., J. C. & Georgiade, N. G. Use of the latissimus dorsi myocutaneous island flap for reconstruction in the head and neck area: case report. *Plast. Reconstr. Surg.*, 62(1):113-7, 1978.
- Rowell, A. R.; Davies, D. M.; Eisenberg, N. & Taylor, G. I. The anatomy of the subscapular-thoracodorsal arterial system: study of 100 cadaver dissections. *Br. J. Plast. Surg.*, 37(4):574-6, 1984.
- Rowell, A. R.; Eisenberg, N.; Davies, D. M. & Taylor, G. I. The anatomy of the thoracodorsal artery within the latissimus dorsi muscle. *Br. J. Plast. Surg.*, 39(2):206-9, 1986.
- Schusterman, M.; Tobin, G. R.; Peterson, G. H. & Nichols, G. Intramuscular neurovascular anatomy of the latissimus dorsi: the basis for splitting the flap. *Surg. Forum*, 31:559-60, 1980.
- Stern, P. J. & Carey, J. P. The latissimus dorsi flap for reconstruction of the brachium and shoulder. *J. Bone Joint Surg. Am.*, 70(4):526-35, 1988.
- Tansatit, T.; Chokrungrvaranont, P.; Wanichaphloi, S. & Sanguansit, P. The anatomy of the thoracodorsal artery in perforator flap for resurfacing shallow defect. *J. Med. Assoc. Thai.*, 90(5):947-55, 2007.
- Tobin, G. R.; Moberg, A. W.; DuBou, R. H.; Weiner, L. J. & Bland, K. I. The split latissimus dorsi myocutaneous flap. *Ann. Plast. Surg.*, 7(4):272-80, 1981a.
- Tobin, G. R.; Schusterman, M.; Peterson, G. H.; Nichols, G.; Bland, K. I.; The intramuscular neurovascular anatomy of the latissimus dorsi muscle: the basis for splitting the flap. *Plast. Reconstr. Surg.*, 67(5):637-41, 1981b.

Corresponding author  
Dr. Amal Yousif Ahmed Alhaj Mustafa  
Department of Anatomy  
Faculty of Medicine  
Umm Al-Qura University  
SAUDI ARABIA

E-mail: amalahmed50@yahoo.com