

# *Patella cubiti* – A Continuing Etiological Mystery

## *Patella cubiti*: Un Misterio Etiológico Continuo

Georgi P. Georgiev<sup>1</sup>; Lyubomir Gaydarski<sup>2</sup>; Lukasz Olewnik<sup>3</sup>; R. Shane Tubbs<sup>4,8</sup>;  
Iva N. Dimitrova<sup>9</sup>; Emilyan Emilov<sup>1</sup>; Vidin Kirkov<sup>10</sup> & Boycho Landzhov<sup>2</sup>

---

GEORGIEV, G. P.; GAYDARSKI, L.; OLEWNIK, L.; TUBBS, R. S.; DIMITROVA, I. N.; EMILOV, E.; KIRKOV, V. & LANDZHOV, B. *Patella cubiti* – a continuing etiological mystery. *Int. J. Morphol.*, 41(1):19-21, 2023.

**SUMMARY:** A sesamoid bone in the elbow joint is a rare anatomical variation described as a *Patella cubiti*. Although this variation has been known for centuries its exact etiology is still unclear. Congenital, developmental, and traumatic hypotheses have been proposed. It seldom causes clinical manifestations than elbow stiffness or hypomobility. Herein, we present a case of a 31-year-old patient admitted to our department with complaints of swelling and erythema in the right elbow. An X-ray image revealed a triangular accessory bone with rounded edges, which was diagnosed as a *Patella cubiti* in combination with olecranon bursitis. Knowledge of this rare elbow abnormality is paramount for orthopedic surgeons and roentgenologists in their daily medical practice.

**KEY WORDS:** *Patella cubiti*; Radiology; History; Etiology.

---

## INTRODUCTION

Elbow abnormalities are rarely described. One example is a sesamoid bone in the elbow joint known as *Patella cubiti* (PC) (Habbe, 1942). Other names used to describe this accessory bone are “*os epiphyseos olecrani*” (Kjelland, 1945), “*sesamum cubiti*” (Sachs & Degenshein, 1920), and *os sesamoideum tricipitale* (Habbe, 1942). PC occurs more commonly in males, usually unilaterally, but bilateral cases have also been described (Sachs & Degenshein, 1920). It is due to partial or complete detachment of the olecranon, and usually appears on an X-ray as an aberrant bone above the proximal ulna (Habbe, 1942). The anomalous bone appears with regular, smoothed edges and cortical outlining, which are essential criteria for differentiating PC from an elbow fracture (Habbe, 1942; Mittal *et al.*, 2014). The exact etiology of this rare anomaly is unknown (Mittal *et al.*, 2014). However, several explanatory hypotheses have been advanced:

- Congenital - proposes that the proximal part of the olecranon does not fuse with the proximal ulna during embryological development, leading to the birth of infants with a PC (Gunn, 1928; Kattan & Babcock, 1979).
- Developmental – suggests that epiphyseal disturbance during early childhood leads to separation of the olecranon above the level of the metaphysis plate, which afterwards ossifies and leads to the development of PC (Habbe, 1942; Van Demark & Anderson, 1967).
- Traumatic - implies that traumatic separation of the olecranon from the ulna, if untreated, leads to the formation of PC (Zeitlin, 1935; Ishikawa *et al.*, 1976).

Usually, PC produces no clinical manifestations and is diagnosed accidentally during an X-ray for a different

<sup>1</sup> Department of Orthopedics and Traumatology, University Hospital Queen Giovanna-ISUL, Medical University of Sofia, Sofia, Bulgaria.

<sup>2</sup> Department of Anatomy, Histology and Embryology, Medical University of Sofia, Sofia, Bulgaria.

<sup>3</sup> Department of Anatomical Dissection and Donation, Chair of Anatomy and Histology, Medical University of Lodz.

<sup>4</sup> Department of Anatomical Sciences, St. George's University, Grenada.

<sup>5</sup> Department of Neurosurgery, Tulane University School of Medicine, New Orleans, Louisiana, USA

<sup>6</sup> Department of Neurology, Tulane University School of Medicine, New Orleans, Louisiana, USA

<sup>7</sup> Department of Structural and Cellular Biology, Tulane University School of Medicine, New Orleans, Louisiana, USA

<sup>8</sup> Department of Surgery, Tulane University School of Medicine, New Orleans, Louisiana, USA

<sup>9</sup> Department of Cardiology, University Hospital “St. Ekaterina”, Medical University of Sofia, Bulgaria.

<sup>10</sup> Department of Health Policy and Management, Medical University of Sofia, Bulgaria.

reason. The most common symptoms of PC are stiffness in the elbow and restricted extension. Rarely does PC present with pain in the elbow and total inability to extend the forearm (Mittal *et al.*, 2014).

## CASE REPORT

A 31-year-old patient presented with complaints of a palpable mass and erythema in the area of the right elbow joint. He denied any recent trauma and provided no adequate explanation of the origin of his complaints. There was erythema in the elbow area and enlargement with evidence of inflammation of the olecranon bursa; full extension of the elbow joint was impossible, with an extension deficit of 30°. No circulatory or neurological disorders of the limb were found. He reported trauma to the elbow during childhood but did not recall how the injury was treated, nor did he provide any medical documentation. However, he stated that since that incident he had not been able to extend his elbow fully. Radiological examination revealed an additional bone with a maximal length 36.4 mm and maximal width 20.1 mm, with smooth edges, proximal and radial to the olecranon (Fig. 1). Thus, the diagnosis of olecranon bursitis with coincidence of *Patella cubiti* was made. The patient received NSAID and antibiotic AB therapy, and after ten days the complaints subsided completely. The patient declined further imaging studies in the elbow area and a possible treatment to increase elbow extension.

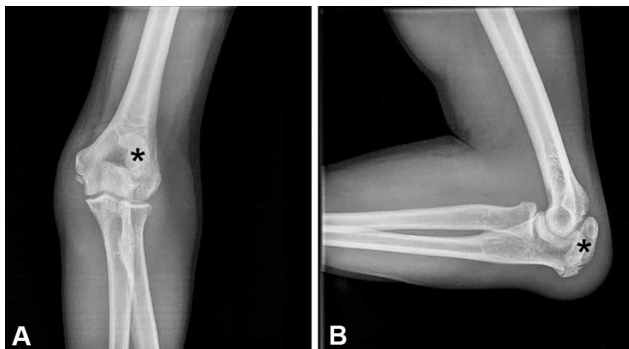


Fig. 1. (A) Antero-posterior view showing a patella cubiti (asterisk); (B) Lateral view showing the *Patella cubiti* (asterisk).

## DISCUSSION

PC is an anatomical abnormality seldom described in the literature. Its first description in European anatomy was by Vicq d' Azyr in 1774, then by Virchow in 1874, Tillesson in 1874 and Pftzner in 1892 (Jachs & Degenshein,

1920; Gunn, 1928). According to Hoernle (1907), Hindu anatomists of four or five hundred years B.C. had offered a similar description. Kienböck (1903) was the first to describe a bilateral PC case on X-ray. Later, Kienböck (1914) described a similar case but accepted it as a pseudoarthrotically-healed olecranon fracture. Pauly (1918) (cited by Kjelland, 1945), described a bilateral PC case in which the left side was recognized as a fracture and treated with osteosuture, while on the right there were no symptoms. However, a controlled X-ray showed an identical bony structure. In 1931, Rostock (1931) described the first operation on a PC. Kienböck & Desenfants (cited by Kjelland, 1945) were the first to describe hereditary PC, unilateral in the father and bilateral in the son. On an X-ray, the author described an aberrant bone with the form and size of a chestnut embedded in the ligament of the triceps in both father and son. No other relatives in the family had the condition.

The exact etiology and development of PC are not entirely understood. Since the first described PC cases there has been an ongoing debate about whether PC results from failed adhesion between the olecranon and the proximal ulna during embryo development, the so-called congenital hypothesis, first proposed by Gunn (1928). Later, this hypothesis was supported by the reports of Kattan & Babcock (1979) and Burge & Benson (1987) concerning approximately six-month-old infants with the typical X-ray finding for PC. Habbe (1942) explained PC development as "epiphysitis" (disturbance of epiphyseal growth). Van Demark & Anderson (1967) extended this idea and proposed the so-called developmental hypothesis, according to which the baby is not born with PC but develops it during early childhood. Kienböck (1903) first proposed a traumatic etiology of PC, ranging from minor trauma separating part of the still-developing olecranon in children to the more severe separation of the whole olecranon, which subsequently becomes embedded in the triceps tendon and ossifies. Such findings have also been reported in both children and adults by other authors (Zeitlin, 1935; Habbe, 1942; Ishikawa *et al.*, 1976).

Determining the etiology of the PC in our case is challenging. At first glance, a traumatic genesis seems most plausible considering the anamnesis of prior trauma. However, there was no evidence for traumatic separation of the proximal part of the olecranon on the X-ray, which excludes this explanation. On the other hand, if the abnormality was congenital, then the complaints of stiffness and extension limitation should have been present since birth and not noted by the patient only after a traumatic incident. Therefore, the developmental hypothesis seems the most reasonable explanation in this case.

In most cases, PC produces no clinical manifestations and is diagnosed accidentally during an X-ray for another reason. The most common symptoms are stiffness in the elbow and restricted extension. Seldom does PC present with pain and total inability to extend the elbow without prior trauma. It is of utmost importance for radiologists and traumatologists to distinguish PC from a new fracture of the olecranon; PC is visualized with round, ossified edges, in contrast to the edges in a fracture, which are sharp, irregular, and lacking compact bone (Mittal *et al.*, 2014). Ritchie & Rocke (1990) described a case of spontaneous rupture of the triceps in the presence of a *Patella cubiti*.

## CONCLUSION

Detailed knowledge of PC as one of the rarest elbow abnormalities is essential for correct diagnosis and treatment.

**Ethical approval and consent to participate.** The article was performed in accordance with the ethical standards, approved by the Medico-Legal Office and Local Ethics Committee, Medical University of Sofia.

---

**GEORGIEV, G. P.; GAYDARSKI, L.; OLEWNIK, L.; TUBBS, R. S.; DIMITROVA, I. N.; EMILOV, E.; KIRKOV, V. & LANDZHOV, B.** *Patella cubiti*: un misterio etiológico continuo. *Int. J. Morphol.*, 41(1):19-21, 2023.

**RESUMEN:** Un hueso sesamoideo en la articulación del codo es una rara variación anatómica descrita como *Patella cubiti*. Aunque esta variación se conoce desde hace siglos, su etiología exacta aún no está clara. Se han propuesto hipótesis congénitas, de desarrollo y traumáticas. Rara vez causa manifestaciones clínicas que no sean rigidez o hipomovilidad del codo. Presentamos el caso de un paciente de 31 años que ingresó en nuestro servicio por presentar tumefacción y eritema en el codo derecho. Una imagen de rayos X reveló un hueso accesorio triangular con márgenes redondeados, que se diagnosticó como una *Patella cubiti* en combinación con bursitis del olécranon. El conocimiento de esta rara anomalía del codo es fundamental para los cirujanos ortopédicos y los médicos radiólogos en su práctica médica diaria.

**PALABRAS CLAVE:** *Patella cubiti*; Radiología; Historia; Etiología.

---

## REFERENCES

- Burge, P. & Benson, M. Bilateral congenital pseudarthrosis of the olecranon. *J. Bone Joint Surg Br.*, 69(3):460-2, 1987.
- Gunn, G. *Patella cubiti*. *Br. J. Surg.*, 15(60):612-5, 1928.
- Habbe, J. E. *Patella cubiti*: report of 4 cases. *AJR Am. J. Roentgenol.*, 48:513-26, 1942.
- Hoernle, R. *Studies in the Medicine of Ancient India*. Oxford, Clarendon Press, 1907.
- Ishikawa, H.; Hirohota, K. & Kashiwagi, D. A case report of patella cubiti. *Z. Rheumatol.*, 35(11-12):407-11, 1976.
- Kattan, K. R. & Babcock, D. S. Case report 105. Bilateral patella cubiti. *Skeletal Radiol.*, 4(4):249-50, 1979.
- Kienböck, R. Ellbogenscheibe" ("Patella cubiti") und olecranonfraktur. *Fortschr. Röntgenstr.* 22:89-94, 1914.
- Kienböck, R. *Patella cubiti*. *Wien. Klin. Wchnschr.*, 16:634, 1903.
- Kjelland, P. M. A rare anomaly in the elbow; patella cubiti. *Acta Radiol.*, 26(6):491-6, 1945.
- Mittal, R.; Sampath Kumar, V. & Gupta, T. *Patella cubiti*: a case report and literature review. *Arch. Orthop. Trauma Surg.*, 134(4):467-71, 2014.
- Ritchie, A. J. & Rocke, L. G. Spontaneous rupture of the triceps in the presence of a patella cubiti. *Arch. Emerg. Med.*, 7(2):114-7, 1990.
- Rostock, P. *Patella cubiti*. *Arch. Orthop. Unfall. Chir.*, 29:291-3, 1931.
- Sachs, J. & Degenshein, G. *Patella cubiti*; a new method of treatment for its avulsion. *Arch. Surg. (1920)*, 57(5):675-80, 1948.
- Van Demark, R. E. & Anderson, T. R. Fractured patella cubiti: report of a case with pathologic findings. *Clin. Orthop. Relat. Res.*, 53:131-4, 1967.
- Zeitlin, A. Traumatic origin of accessory bones at the elbow. *J. Bone Joint Surg.*, 17(4):933-8, 1935.

Corresponding author:  
Georgi P. Georgiev, MD, PhD, DSc  
Department of Orthopedics and Traumatology  
University Hospital Queen Giovanna - ISUL  
Medical University of Sofia  
8 Bialo More St.  
BG1527 Sofia  
BULGARIA

<https://orcid.org/0000-0001-8343-0337>

E-mail: georgievgp@yahoo.com