

Prototyping and 3D Printing of Computed Tomography Images with an Emphasis on Soft Tissues, Especially Muscles, for Teaching Human Anatomy

Prototipado e Impresión 3D de Imágenes de Tomografía Computarizada con Énfasis en los Tejidos Blandos, Especialmente Músculos, para la Enseñanza de la Anatomía Humana

Adriano Ferreira da Silva^{1,2}; Mariane Cristina Donato^{3,4,5}; Mauricio oliveira da Silva^{7,8}; Severino Denicio Gonçalves de Sousa^{4,6,8}; Thelma Renata Parada Simão^{9,10,11}; Kátia Simone Kietzer^{12,13,14,15}; Edson Aparecido Liberti^{16,17} & Patrick William Frank¹⁸

DA SILVA, A. F.; DONATO, M. C.; DA SILVA, M. O.; DE SOUSA, S. D. G.; SIMÃO, T. R. P.; KIETZER, K. S.; LIBERTI, E. A. & FRANK, P. W. Prototyping and 3D printing of computed tomography images with an emphasis on soft tissues, especially muscles, for teaching human anatomy. *Int. J. Morphol.*, 41(1):73-78, 2023.

SUMMARY: The study on cadavers, although considered fundamental in the teaching of human anatomy, is limited in several universities, mainly due to the acquisition and manipulation of cadaveric material. Throughout history, several artificial anatomical models have been used to complement the real anatomical pieces. The present study offers a new alternative: the making of three-dimensional models from Computed Tomography (3D-CT) patient image acquisition. CT images from the USP University Hospital database were used. Patients underwent examinations for reasons other than the present study and were anonymized to maintain confidentiality. The CT slices obtained in thin cross-sections (approximately 1.0 mm thick) were converted into three-dimensional images by a technique named Volume Rendering for visualization of soft tissue and bone. The reconstructions were then converted to an STL (Standard Triangle Language) model and printed through two printers (LONGER LK4 Pro® and Sethi S3®), using PLA and ABS filaments. The 3D impressions of the thigh and leg muscles obtained better visual quality, being able to readily identify the local musculature. The images of the face, heart, and head bones, although easily identifiable, although seemed to present lower quality aesthetic results. This pilot study may be one of the first to perform 3D impressions of images from CT to visualize the musculature in Brazil and may become an additional tool for teaching.

KEY WORDS: 3D printing; Computed tomography; Anatomy; Teaching.

INTRODUCTION

One of the great challenges for teaching human anatomy in the 21st century, as in previous centuries, is obtaining adequate material. The dissection of fixed cadaveric material still presents itself as the best way of

¹ Radiologist at the University Hospital of the University of São Paulo (HU-USP)

² PhD in Sciences, Department of Anatomy of Domestic and Wild Animals, Faculty of Veterinary Medicine, University of São Paulo.

³ Physiotherapist from the City University of São Paulo (UNICID)

⁴ Master's in Sciences, Department of Anatomy of Domestic and Wild Animals, Faculty of Veterinary Medicine, University of São Paulo.

⁵ PhD student, Post-Graduate Program in Health Sciences at Hospital Sírio-Libanês.

⁶ Biologist from the Regional University of Cariri (URCA).

⁷ Veterinarian, University of Santo Amaro (UNISA), Specialist in Functional and Comparative Anatomy from the ICB-USP.

⁸ Doctoral student, Department of Anatomy of Domestic and Wild Animals, Faculty of Veterinary Medicine, University of São Paulo.

⁹ Dentist Graduate Universidade Cidade de São Paulo.

¹⁰ PhD in Anatomy, University of São Paulo.

¹¹ Coordinator of the Bodies Program for Anatomical Studies. for the Institute of Biomedical Sciences at USP.

¹² Graduated in Physiotherapy, Regional University of Blumenau – FURB.

¹³ PhD in Neurosciences and Cell Biology, Federal University of Pará.

¹⁴ Post-doctorate in Neurosciences at UFSC.

¹⁵ Human anatomy professor, UEPA (Universidade do Estado do Pará).

¹⁶ Full/Senior Professor, Institute of Biomedical Sciences at the University of São Paulo.

¹⁷ Coordinator, Cultural Development Center of the Butantan Institute, Brasil.

¹⁸ Doctor in Chiropractic. Assistant Professor Department of Medical Education/Neurosciences, University of Toledo - of Medicine & Life Sciences, Toledo, Ohio, U.S.A.

learning for students – Winkelmann (2007). According to Davis *et al.* (2014), 95 % of the students evaluated in their research considered the study of anatomy in the cadaver (dissection or prosection) important. The students stated that "seeing the dissected specimen is critical to understanding the anatomy". However, the scarcity of corpses in many faculties for various reasons (including those related to the SARS-COV2/COVID-19 pandemic), it is necessary to use other adjuvant forms for teaching.

The history of anatomical models as a substitute or complement to cadavers is long. At the end of the 17th century, the Sicilian artist Gaetano Zumbo produced several anatomical wax models. From it, the Italian school of wax -up was created in Florence, Italy, which lasted until the 19th century and today constitutes the museum "La Specola". In the 19th century, the French student Louis Thomas Jérôme Auzoux, produced several models in papier-mâché. Very popular, they were the prototype for the mass production of plaster and plastic models of the 20th century - Markovic *et al.* (2014).

Currently, alternatives are being sought that, at least, reduce some of the disadvantages related to traditional anatomical models. Of these, three-dimensional (3D) printing is one of the most promising (Suárez-Escudero *et al.*, 2020).

There are several ways to obtain 3D images for printing. Usually, a 3D scanner is used for digitizing the specimen and transforms them into prototyping files (STL - StereoLithography or Standard triangle language formats, AMF - additive manufacturing format, OBJ, FBX, COLLADA, 3DS, IGES, STEP and VRML/X3D), forming a model, which is processed and improved by specific software and sent to the printer. The material used in printing varies, and can be rigid polymer filaments (nylon, polyamide, ABS, PLA, PETG), flexible polymers (TPU, TPE and TPC), metals (steel, gold, silver and titanium), ceramics and biomaterials (Figueiredo & Cesar, 2022).

The 3D printing process was initially developed by the Massachusetts Technological University (MIT) and patented in 1989 by Emanuel Sachs and his fellow researchers. The functional principle is based on the deposition of an adhesive material (binder) under a layer of ceramic powder (generally plaster), generating an agglomerate. The layer thickness is approximately 0.089 to 0.2 mm, while the resolution is around 600 x 540 DPI (dots per inch). The overall accuracy is approximately 0.125 mm, and the deposition speed is up to four layers per minute (Figueiredo & Cesar, 2022).

The applications of this technique in the teaching of human anatomy still have a limited literature, with most studies being carried out through digital bone scanning (Thomas *et al.*, 2016; Bartikian *et al.*, 2019; Massari *et al.*, 2021), and more rarely, soft tissue (Anwari, 2020; Tan *et al.*, 2022).

An alternative for obtaining three-dimensional models in anatomy would be images from computed tomography (CT) and magnetic resonance imaging (MRI) exams. In this case, both images are obtained in DICOM (Digital Imaging and Communications in Medicine) and reconstructed in a 3D format (typically Volume Rendering technique) on the device workstation or in suitable software (Radiant™, Ozyrix™, among others). The software converts the DICOM images to a 3D model (e.g., STL), which is then sent to the printer. CT impressions are already used in Medicine to produce prostheses or orthopedic materials, and for the purpose of surgical programming (Filippou & Tsoumpas 2018; Lal & Patralkh, 2018), and for studies involving the heart and great vessels, mainly the aorta, to produce "stents" or endovascular prostheses suitable for each patient (Ripley *et al.*, 2016; Vukicevic *et al.*, 2017; Otton *et al.*, 2017).

The use of tomography to obtain 3D images was chosen by the author due to the following advantages: thin image thickness ("slices") performed by CT (up to 0.5 mm), relative ease of image acquisition, post-processing (3D reconstruction) when compared to MRI, good visualization of bone, vascular, thoracic structures, and most of the muscles. Disadvantages of 3D-CT include poor visualization of the nervous system, digestive system, ligaments and aponeuroses; tissues with a small amount of fat are difficult to differentiate, need for specific software to visualize DICOM images and to convert them into 3D models).

Objetives

General: 3D printed models from computed tomography (3D-CT) images for the study of human anatomy, with emphasis on soft parts, especially muscles.

Specifics:

- Obtain 3D CT reconstruction images that allow the observation of different soft parts;
- Produce scanned models from these images and assess their eligibility for further printing.
- Evaluate the quality of printed images in terms of anatomical precision and fidelity with respect to the digital model.
- Evaluate the need for additional treatment (polishing, painting) for the best presentation and teaching of the model.

MATERIAL AND METHOD

CT images were obtained from the image bank of the University Hospital of the University of São Paulo (HU-USP), between April and June 2022. The patients underwent these exams for reasons other than the present study, according to the protocols of the HU-USP Ethics Committee. Patient data were anonymized to avoid identification. The following images were obtained: CT of the chest to study the heart; CT of the skull and face (hemi heads) to study the bones and muscles of the head; CT of a thigh for muscle study; CT of a leg for muscle study.

The CT cross sections (axial) were obtained on a Phillips Brilliance @ apparatus with 64 rows of X-ray detectors (multislice), with slice thickness of 1.0 mm in DICOM format. These images, in turn, were reconstructed in the coronal, sagittal and three-dimensional planes (the latter using the Volume Rendering technique) using the DICOM image visualization software (Radiant DICOM Viewer 2021.1™) and adjusted and edited to visualize the desired soft tissues. The software allowed the conversion of the 3D reconstructions into a digital STL model.

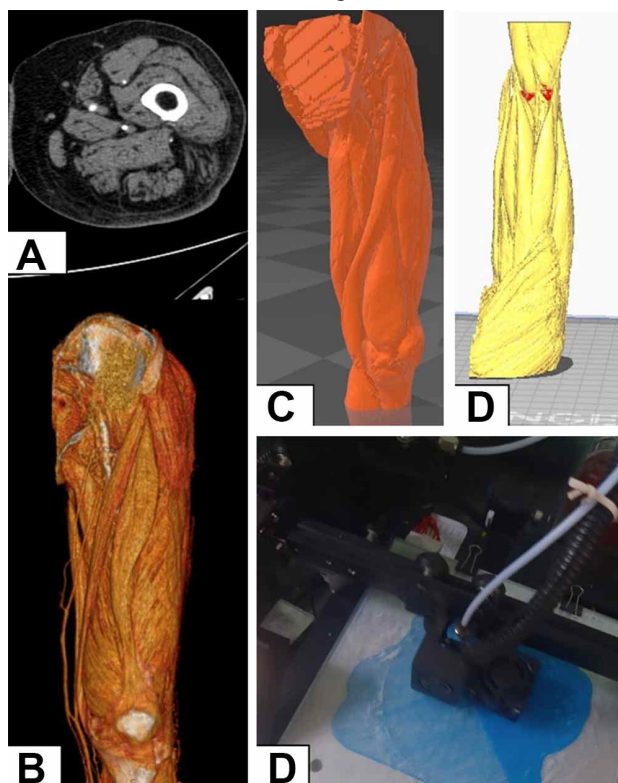


Fig. 1. Steps of 3D printing (thigh). A. CT cross-sectional source image (in DICOM language). B. 3D reconstruction of source images using the Volume Rendering technique. C. Creation of the STL Model. D. Processing the STL image by the printer software. D. Start of 3D printing. Source: author's personal file.

The models were printed using two printers (LONGER LK4 Pro™ and Sethi S3™), using PLA and ABS filaments. This resulted in rigid models measuring 15.0 cm high (heart), 18.0 cm high (thigh), 15.0 cm high (skull and face) and 20.0 cm high (leg). Some of the pieces were spray painted with Colorgin Arte Urbana™ acrylic to enhance the anatomical structures (Fig. 1).

RESULTS

Qualitatively, the following aspects were observed in relation to the acquisition and printing of images:

First, the 3D printing quality was directly linked to the quality of the image obtained by both the CT scan and the STL model. There is a remarkable loss on spatial resolution of the image (ability to see two points as separate and distinct) in the STL Image.

The STL model in turn resulted in 3D images of different qualities. In the present study, the models that represented muscles (thigh, leg, and face) presented better aesthetic results, with a good differentiation of the visualized muscles, within the possibilities of CT. Polishing and painting the parts ensured better fidelity with the TC-3D images. The identification of muscles was promptly performed, mainly in the thigh and leg. On the face, other structures, such as the parotid gland, were also visualized.

As for the heart, which was the first piece to be made, the quality was relatively inferior to the volume rendering image. Even so, several structures on the surface of the heart are identified, such as the great vessels of the base, the atria, and the anterior interventricular artery, among others. To reduce time and cost in preparation. The interior of the heart was not modeled in this piece.

Interestingly, the bones of the head presented the lowest image quality, with poor distinction between the bones, quite different from the Volume Rendering model and the STL model (Fig. 2).

DISCUSSION

This pilot study shows that the three-dimensional impression of soft tissues obtained by CT can have a promising result in the teaching of human anatomy. 3D CT models have the following advantages over conventional models:

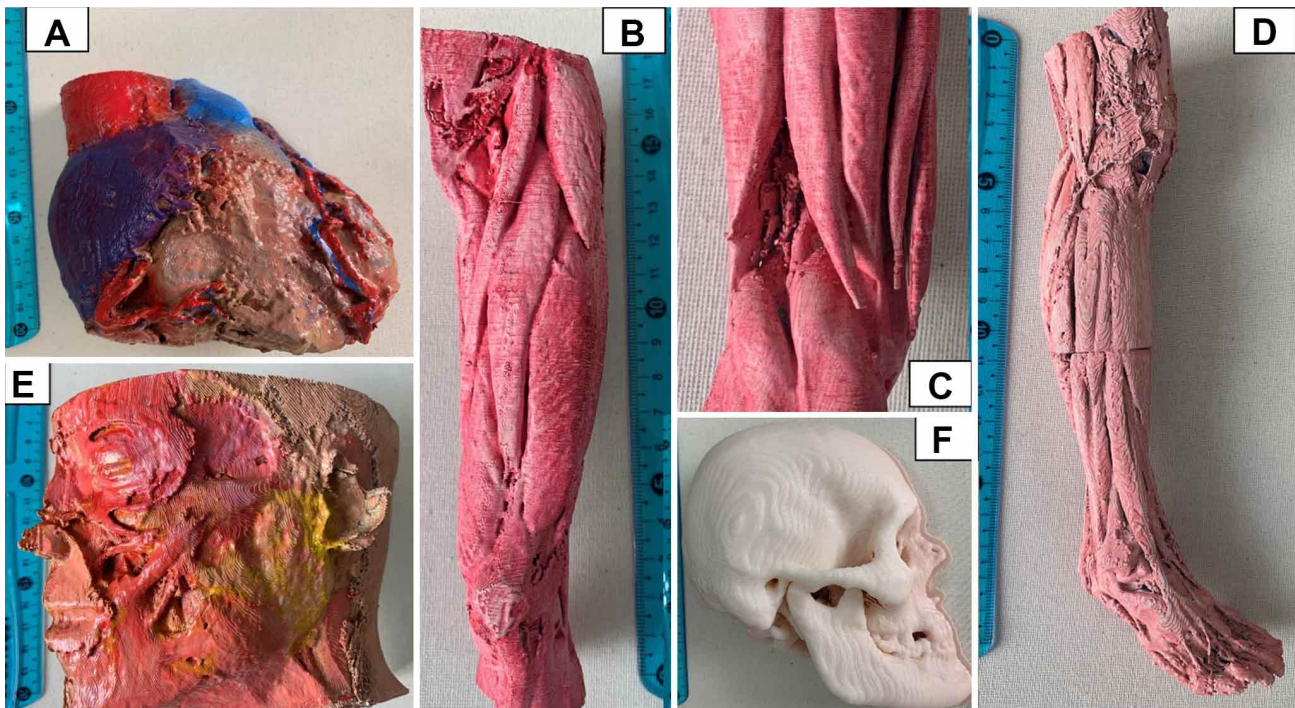


Fig. 2. 3D prints made for this job: A. Heart; B. Thigh; C. Same as B (detail, back face); D. Leg; E: hemi head; F: bones of the head (half). Source: author's personal file.

- Are obtained from real patients.
- May represent anatomical variations present in individuals.
- There is no need for cadaveric dissection.
- No need for 3D scanning.
- The original CT images (in DICOM) can be saved and reused for making new prints, in addition to being exchanged between institutions.
- The same image can be adjusted for different structures (vessels, bones, muscles), and images can also be obtained in different stratigraphic layers or transversal, coronal or sagittal sections.
- The print quality depends on the material and printer used; different layers of fabrics can be printed and in different colors (e.g., bones in rigid filaments and muscles in flexible filaments, and then glued), or painted (as in the case of this work) to give a more realistic look or for teaching purposes.
- Prints can be made in different sizes, facilitating transport and handling (remembering that large prints require time and cost).

As disadvantages, we have:

- It is not possible to dissect the printed pieces (although the images in Volume Rendering can be digitally manipulated, performing "virtual dissections");
- The printed parts will not have the tactile properties of a

- fresh or even fixed cadaver (limitation generally applied to all models, except for Syndaver® - models produced with artificial fabrics somewhat similar to natural ones, used in simulation of medical procedures), in high cost and not available in our environment (Syndaver, 2016).
- Requires an agreement with hospitals or radiological clinics to access the images, in addition to maintaining the ethical precepts of anonymization and confidentiality of patients.
- The cost of 3D printing can still be an impairment in some laboratories, but these prints can become popular over time.

Thus, the results obtained with the pieces produced are only initial. Depending on the STL model, software, material, and printer used, the resulting quality can be even higher. Obtaining 3D images by the Volume Rendering technique does not seem to be very suitable for some types of images, such as the heart, which is in accordance with the literature (Otton *et al.*, 2017). Perhaps obtaining higher resolution images of bones and using better software for image processing may allow for better spatial resolution of bone structures, as extensively cited in the literature (O'Reilly *et al.*, 2016; Lal & Patralekh, 2018; Haleem *et al.*, 2020).

Interestingly, the muscles, especially those of the lower limbs, were the ones that had the best result in 3D

printing. The greater separation of the muscle bellies by adipose tissue and their larger dimensions favored individualization of the bundles. On the face, the small muscles were not represented, but some, such as the zygomaticus major and the masseter, as well as the adjacent parotid gland, were well visualized.

CONCLUSION

The 3D impressions obtained in this work can open a new perspective for the use of CT in anatomy (commonly associated with cross-sections and the evaluation of bone parts). As they are obtained from real and living individuals, CT images seem to present a higher degree of realism than conventional models, in addition to the ease of transport, handling, reproducibility and absence of biological effects can be advantages in places where the availability of corpses is very low. The authors consider that the 3D printing of muscles from CT is among the first performed in the country.

ACKNOWLEDGEMENTS: We thank Mr. Marcus Vinícius Moura Gomes, who kindly made the prints at his company. More info at: <https://maiden3d.com/contact/>

DA SILVA, A. F.; DONATO, M. C.; DA SILVA, M. O.; DE SOUSA, S. D. G.; SIMÃO, T. R. P.; KIETZER, K. S.; LIBERTI, E. A. & FRANK, P. W. Prototipado e impressão 3D de imágenes de tomografía computarizada con énfasis en los tejidos blandos, especialmente músculos, para la enseñanza de la anatomía humana. *Int. J. Morphol.*, 41(1):73-78, 2023.

RESUMEN: El estudio en cadáveres, a pesar de considerarse un aspecto fundamental en la enseñanza de la anatomía humana, se encuentra limitado en varias universidades, principalmente por la adquisición y manipulación de material cadavérico. A lo largo de la historia se han utilizado varios modelos anatómicos artificiales para complementar las piezas anatómicas reales. El presente estudio ofrece una nueva alternativa: la elaboración de modelos tridimensionales a partir de la adquisición de imágenes de pacientes por Tomografía Computarizada (3D-CT). Se utilizaron imágenes de TC de la base de datos del Hospital Universitario de la USP. Los pacientes se sometieron a exámenes por razones distintas al presente estudio y fueron anonimizados para mantener la confidencialidad. Los cortes de TC obtenidos en secciones transversales delgadas (aproximadamente 1,0 mm de grosor) se convirtieron en imágenes tridimensionales mediante una técnica denominada Volume Rendering para la visualización de tejido blando y hueso. Luego, las reconstrucciones se convirtieron a un modelo STL (Standard Triangle Language) y se imprimieron a través de dos

impresoras (LONGER LK4 Pro® y Sethi S3®), utilizando filamentos PLA y ABS. Se obtuvo una mejor calidad visual de las impresiones 3D de los músculos del muslo y la pierna, pudiendo identificar fácilmente la musculatura local. Las imágenes de la cara, el corazón y los huesos de la cabeza, aunque fácilmente identificables, parecían presentar resultados estéticos de menor calidad. Este estudio piloto puede ser uno de los primeros en realizar impresiones 3D de imágenes de TC para visualizar la musculatura y podría ser en una herramienta adicional para la enseñanza.

PALABRAS CLAVE: Impresión 3D; Tomografía computarizada; Anatomía; Enseñanza.

REFERENCES

- Anwari, V.; Lai, A.; Ursani, A.; Rego, K.; Karasfi, B.; Sajja, S. & Paul, N. 3D printed CT-based abdominal structure mannequin for enabling research. *3D Print. Med.*, 6(1):3, 2020.
- Bartikian, B.; Ferreira, M.; Gonçalves-Ferreira, A. & Neto, L. L. 3D printing anatomical models of head bones. *Surg. Radiol. Anat.*, 41(10):1205-9, 2019.
- Davis, C. R.; Bates, A. S.; Ellis, H. & Roberts, A. M. Human anatomy: let the students tell us how to teach. *Anat. Sci. Educ.*, 7(4):262-72, 2014.
- Figueiredo, B. B. & Cesar, I. G. F. Um estudo da utilização da impressora 3D na Engenharia e na Medicina. *Recisatec*, 2(1):e2170, 2022.
- Filippou, V. & Tsoumpas, C. Recent advances on the development of phantoms using 3D printing for imaging with CT, MRI, PET, SPECT, and ultrasound. *Med. Phys.*, 45(9):e740-e760, 2018.
- Haleem, A.; Mohd, J.; Khan R. H. & Suman, R. 3D printing applications in bone tissue engineering. *J. Clin. Orthop. Trauma*, 11(Suppl. 1):S118-S124, 2020.
- Lal, H. & Patralekh, M. K. 3D printing and its applications in orthopaedic trauma: A technological marvel. *J. Clin. Orthop. Trauma*, 9(3):260-8, 2018.
- Massari, C. H.; Carvalho, Y. K. & Miglino, M. A. 3D printing of brachycephalic and dolichocephalic canine skulls and mandibles: a complement to traditional osteotechnique. *Acta Vet. Bras.*, 15(2):173-9, 2021.
- O'Reilly, M. K.; Reese, S.; Herlihy, T.; Geoghegan, T.; Cantwell, C. P.; Feeney, R. N. M. & Jones, J. F. X. Fabrication and assessment of 3D printed anatomical models of the lower limb for anatomical teaching and femoral vessel access training in medicine. *Anat. Sci. Educ.*, 9(1):71-9, 2016.
- Otton, J. M.; Birbara, N. S.; Hussain, T.; Greil, G.; Foley, T. A. & Pather, N. 3D printing from cardiovascular CT: a practical guide and review. *Cardiovasc. Diagn. Ther.*, 7(5):507-26, 2017.
- Ripley, B.; Kelil, T.; Cheezum, M. K.; Goncalves, A.; Di Carli, M. F.; Rybicki, F. J.; Steigner, M.; Mitsouras, D. & Blankstein, R. 3D printing based on cardiac CT assists anatomic visualization prior to transcatheter aortic valve replacement. *J. Cardiovasc. Comput. Tomogr.*, 10(1):28-36, 2016.
- Suárez-Escudero, J. C.; Posada-Jurado, M. C.; Bedoya-Muñoz, L.J.; Urbina-Sánchez, A.J.; Ferreira Morales, J. L. & Bohórquez-Gutiérrez, C. A. Enseñar y aprender anatomía. *Acta Med. Colomb.*, 45(4), 2020. Available from: <http://www.actamedicacolombiana.com/ojs/index.php/actamed/article/view/1898>
- SynDaver. WebSite, 2016. Available at: <https://syndaver.com/>

Tan, L.; Wang, Z.; Jiang, H.; Han, B.; Tang, J.; Kang, C.; Zhang, N. & Xu, Y. Full color 3D printing of anatomical models. *Clin. Anat.*, 35(5):598-608, 2022.

Thomas, D. B.; Hiscox, J. D.; Dixon, B. J. & Potgieter, J. 3D scanning and printing skeletal tissues for anatomy education. *J. Anat.*; 229(3):473-81, 2016.

Vukicevic, M.; Mosadegh, B.; Min, J. K. & Little, S. H. Cardiac 3D Printing and its Future Directions. *JACC Cardiovasc. Imaging*, 10(2):171-84, 2017.

Corresponding author:

Adriano Ferreira da Silva
Radiologist at the University
Hospital of the University of São Paulo
(HU-USP)
São Paulo
BRAZIL

E-mail: adrimesilva@gmail.com