

Classification of Sternocleidomastoid Muscle Variations and Comparison of Its Incidence among Populations

Clasificación de Variaciones del Músculo Esternocleidomastoideo y Comparación de su Incidencia entre Poblaciones

Chanwit Maneenin¹; Naowarat Maneenin²; Chananya Jirapornkul²; Chadaporn Chaimontri³ & Sitthichai Iamsaard³

MANEENIN, C.; MANEENIN, N.; JIRAPORNKUL, C.; CHAIMONTRI, C. & IAMSAARD, S. Classification of sternocleidomastoid muscle variations and comparison of its incidence among populations. *Int. J. Morphol.*, 41(1):175-180, 2023.

SUMMARY: This study aimed to classify and investigate anatomical variations of the sternocleidomastoid (SCM) muscle, which is commonly used as an anatomical landmark to indicate the correct position for central venous catheterization, in a Thai population. Thirty-five embalmed cadavers from the Northeast Thailand (19 females and 16 males) were systemically dissected to reveal the SCM muscles in both sides for gross human anatomy teaching. Variations in the SCM origin and insertion were observed and recorded. The prevalence of anatomical variations was approximately 11.4 % (4 of 35 cadavers) and was not different by sex. Such variations were classified into 5 types based on origin, insertion, and presence of additional heads, as follows: type I (n=31; 88.6 %), type II (n=1; 2.85 %), type III (n=1; 2.85 %), type IV (n=1; 2.85 %), and type V (n=1; 2.85 %). Clinical considerations and prevalence of variant SCM muscle have also been discussed. Since the incidence of this anatomical variations was more than 10 %, the cervical surgeons should seriously consider this issue before insertion of a central venous catheter to avoid complications.

KEY WORDS: Sternocleidomastoid muscle; Anatomical variation; Cadavers; Classification.

INTRODUCTION

The sternocleidomastoid (SCM) is the largest and longest muscle located superficially within the anterior compartment of the cervical muscles. Anatomically, the SCM is associated with many vital neurovascular structures of the neck and is an important surgical landmark for identifying the precise location for central venous catheter insertion (Drake *et al.*, 2010; Moore *et al.*, 2014). This muscle originates from the manubrium sterni (sternal head) and the medial third of the clavicle (clavicular head). Its insertion is the lateral surface of the mastoid process of the temporal bone and laterally to the nuchal line (Standring, 2008; Drake *et al.*, 2010). The terminal end of the SCM inserts at the mastoid process. The SCM contributes to various modalities of head and neck movement such as flexing of the neck and rotation of the head to the opposite side. Additionally, it also supports the normal breathing system (Hasan, 2011). It is possible that variations or abnormalities in SCM origin and insertion may cause abnormal neck and head movements

and complications during central venous catheterization. Abnormality of the SCM – especially in terms of its origin – has been reported in numerous populations including those in Brazil, Greek, India, Australia, South Korea, Turkey, Colombia, Pakistan, and the US (Natsis *et al.*, 2009; Amorim Júnior *et al.*, 2010; Mehta *et al.*, 2012; Raikos *et al.*, 2012; Saxena *et al.*, 2013; Goswami *et al.*, 2014; Saha *et al.*, 2014; Kim, 2015; Anil *et al.*, 2016; Arquez, 2017; Mansoor & Rathore, 2018; Dupont *et al.*, 2018; Oh *et al.*, 2019). Most of these previous studies were case reports using human embalmed cadavers. An incidence of anatomical variations is greater than 10 % in an individual population and demands clinical consideration. Previous studies in West Bengal and Columbia have shown the rates of 27.8 % 11.7 %, respectively (Saha *et al.*, 2014; Arquez, 2017). As that in the Thai population has yet to be documented, we systemically investigated the types and incidence of SCM abnormality in cadavers from Northeast Thailand.

¹ Department of Anatomy, College of Medicine and Public Health, Ubon Ratchathani University, Ubon Ratchathani 34190, Thailand.

² Department of Epidemiology and Biostatistics, Faculty of Public Health, Khon Kaen University, Khon Kaen 40002, Thailand.

³ Department of Anatomy and Unit of Human Bone Warehouse for Research (UHBWR), Faculty of Medicine, Khon Kaen University 40002, Thailand.

MATERIAL AND METHOD

Specimens. Our study was performed based on the Human Tissue Authority (HTA) guidelines on the handling of human materials. Soft tissues dissected and removed from neck specimens were disposed with respect to prestige of the body donors who have signed with their relatives on the Informed consent of body donation form before death. After decease, close relatives have signed again to consent the body for medical study and researches. This study has followed the Tenets of the Declaration of Helsinki. In addition, this research has also been approved by Ubon Ratchathani University's Ethics of Human Research Committee (code: UBU-REC-61/2562).

This cross-sectional descriptive study was conducted from 2019 to 2020 at the anatomical laboratory of the College of Medicine and Public Health at Ubonratchathani University in Thailand. The population size was calculated based on the comparative ratios described previously (Wayne, 1995) and a previous study reported by Saha and coworkers (2014), which found a rate of approximately 27.8 % in West Bengal. We determined that 35 embalmed cadavers would be suitable for the investigation. All cadavers were from residents of northeast Thailand who had voluntarily donated their bodies to be used for medical/gross anatomy education, including research conducted at the Khon Kaen University Faculty of Medicine Department of Anatomy.

The head and neck regions of 35 embalmed cadavers (19 female and 16 male) were dissected by second year medical students enrolled in an anatomy course. Skinning was performed to expose the superficial fascia on the anterior compartment of the neck. Before approaching to the sternocleidomastoid muscle (SCM), different layers of tissues consisting of the superficial cervical fascia, deep cervical fascia, and the platysma muscle were systemically dissected and removed as previously described Moore *et al.* (2014). Before classification, the SCM origins and insertions at each side (right and left) of all cadavers were recorded and photographed.

RESULTS

The sample consisted of 35 embalmed cadavers from northeast Thailand – 16 male (45.7 %) and 19 female (54.3 %). Thirty-one (88.6 %; 17 male [48.6 %] and 14 female [40.0 %]) were normal, while the remaining four (11.4 %; 2 [5.7 %] of each male and female) exhibited anatomical variations (Table I). We classified the specimens into five types based anatomical origin and insertion patterns of the SCM (Table II and Fig. 1). The heads of the left and the right SCM were clearly separated in all cadavers. Normal SCM muscles were classified as type I, and abnormal patterns were categorized into 4 types (II, III, VI, and V). As shown in Table II, the type I group

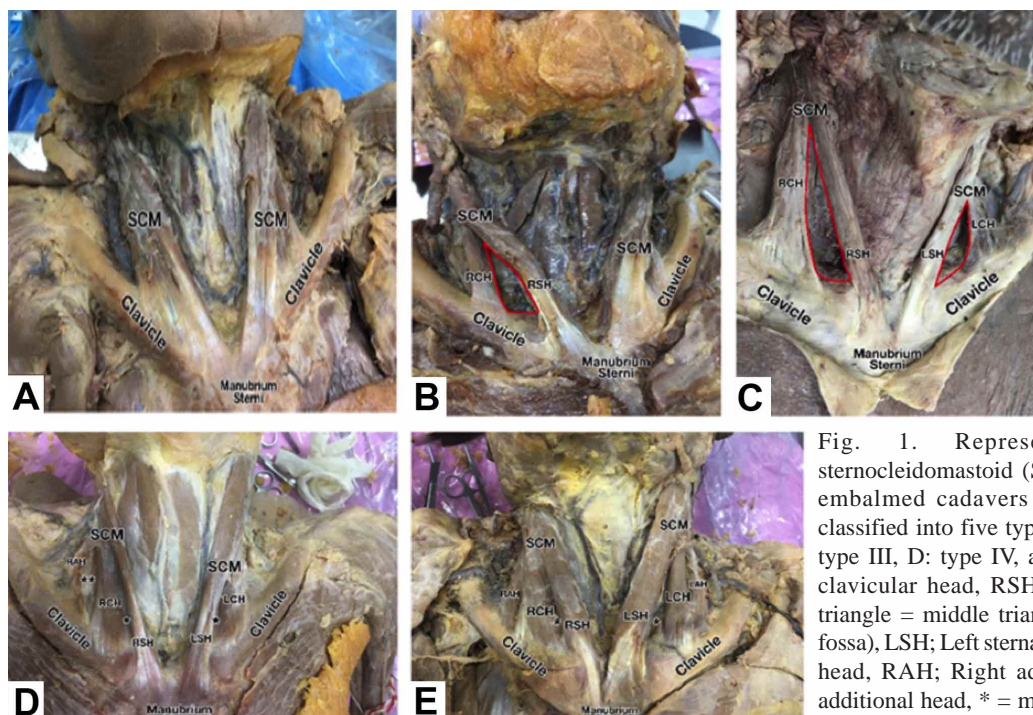


Fig. 1. Representative patterns of sternocleidomastoid (SCM) muscles observed in embalmed cadavers from northeast Thailand classified into five types. A: type I, B: type II, C: type III, D: type IV, and E: type V. RCH; Right clavicular head, RSH; Right sternal head, Red triangle = middle triangle (major supraclavicular fossa), LSH; Left sternal head, LCH; Left clavicular head, RAH; Right additional head, LAH; Left additional head, * = medial minor supraclavicular fossa, ** = lateral minor supraclavicular fossa.

consisted of 31 (88.6 %) samples while types II-V consisted of one (2.85 %) each. The anatomical features of each type

observed are demonstrated in Figure 1 and each side described in Table III.

Table I. Incidence of sternocleidomastoid abnormality observed in Northeastern Thais.

Parameter	Sternocleidomastoid muscle patterns observed from 35 specimens		
	Normality (%)	Anatomical variations (%)	Total (%)
Sex			
Male	14 (40.0)	2 (5.7)	16 (45.7)
Female	17 (48.6)	2 (5.7)	19 (54.3)
Total	31 (88.6)	4 (11.4)	35 (100 %)

Table II. Classification of sternocleidomastoid muscle types observed in Northeastern Thais.

Classifications (Types)	Numbers found (%)
I	31 (88.6 %)
II	1 (2.85 %)
III	1 (2.85 %)
IV	1 (2.85 %)
V	1 (2.85 %)
Total	35 (100 %)

Table III. Descriptions of sternocleidomastoid muscle (SCM) types by side observed in Northeastern Thais based on origin and insertion of the muscle (also shown in the Fig.1).

Types of SCM (corroborated with Fig. 1)	Origins	Insertions
I (Fig. 1A)	Left side: one head, anterior surface of the manubrium sterni bone and one third of superior surface of medial clavicular bone	Left side: mastoid process
	Right side: one head, anterior surface of the manubrium sterni bone and antero-superior surface of the medial third of the clavicular bone	Right side: mastoid process
II (Fig. 1B)	Left side: one head, anterior surface of the manubrium sterni bone and one-third of the superior surface of the medial clavicle bone	Left side: mastoid process
	Right side: two heads, 1 st origin: anterior surface of the manubrium sterni bone 2 nd origin: superior surface of the middle part of the clavicular bone	Right side: mastoid process
III (Fig. 1C)	Left side: two heads, 1 st origin: anterior surface of the manubrium sterni bone 2 nd origin: superior surface of the middle part of clavicular bone	Left side: mastoid process
	Right side: two heads, 1 st origin: anterior surface of the manubrium sterni bone 2 nd origin: superior surface of the middle part of the clavicular bone	Right side: mastoid process
IV (Fig. 1E)	Left side: two heads, 1 st origin: anterior surface of the manubrium sterni bone 2 nd origin: one-third of the superior surface of the medial area of the clavicular bone	Left side: mastoid process
	Right side: three heads. 1 st origin: anterior surface area of the manubrium sterni bone 2 nd origin: one-third of the superior surface of the medial area of the clavicular bone 3 rd origin: superior surface of the middle part of the clavicular bone	Right side: mastoid process
V (Fig. 1E)	Left side: three heads, 1 st origin: anterior surface of manubrium sterni bone 2 nd origin: one-third of the superior surface of the medial area of the clavicular bone 3 rd origin: superior surface of the middle part of the clavicular bone	Left side: mastoid process
	Right side: three heads. 1 st origin: anterior surface of the manubrium sterni bone 2 nd origin: one-third of the area in the superior surface of the medial area of the clavicular bone 3 rd origin: superior surface of the middle part of the clavicular bone	Right side: mastoid process

DISCUSSION

The initial part or origin of the sternocleidomastoid muscle (SCM) most commonly has two regular heads: the “medial” or “sternal” head, connected to the upper part of the anterior surface of the manubrium sterni bone, and the “lateral” or “clavicular” head, attached to the superior surface of the medial side of the clavicle bone. These long bilateral muscles commonly insert to the mastoid process of the temporal bone (Standring, 2008). The triangle formed between the base of the clavicular bone and the sterno-clavicular heads of the SCM is used as a surgical landmark for identifying the precise location at which to perform central venous catheterization because it is related to the neuro-vascular structures of the neck. Variations in SCM origin must thus be addressed to avoid complications during surgery. As summarized in Table IV, SCM abnormalities have been reported in many countries around the world including Greece, Brazil, India, Australia, Turkey, Columbia, Pakistan, the US, and Korea (Natsis *et al.*, 2009; Amorim Júnior *et al.*, 2010; Mehta *et al.*, 2012; Raikos *et al.*, 2012; Saxena *et al.*, 2013; Saha *et al.*, 2014; Kim, 2015; Anil *et al.*, 2016; Arquez, 2017; Dupont *et al.*, 2018; Mansoor & Rathore, 2018; Oh *et al.*, 2019). However, most were case reports observed during lessons on gross anatomy for medical or paramedical students, and few systematic studies have been published. SCM variation has been documented in India (27.8 %) and Columbia (11.7 %) (Saha *et al.*, 2014; Arquez, 2017).

This study was the first of its kind conducted in a Thai population and revealed an incidence of 11.4 %, comparable to that found in Columbia mentioned above (Table IV). Interestingly, previous studies have found higher incidences of SCM abnormality or anatomical variations

in males than in females (Natsis *et al.*, 2009; Amorim Júnior *et al.*, 2010; Mehta *et al.*, 2012; Raikos *et al.*, 2012; Saxena *et al.*, 2013; Saha *et al.*, 2014; Kim, 2015; Anil *et al.*, 2016; Arquez, 2017; Dupont *et al.*, 2018; Mansoor & Rathore, 2018). Moreover, abnormalities observed in a female specimen from South Korea differed from those in the female cadavers in our study (Oh *et al.*, 2019). In our study, the number of SCM muscles with abnormalities did not differ by sex (2 cases each), but each was of a different type (Fig 1). There were two cases of additional muscular heads observed in our study, both on the right side. The first was found in a female cadaver classified as SCM type IV (Fig. 1D) and the second in a male cadaver classified as type V (Fig. 1E). These findings were similar to those of previous studies (Natsis *et al.*, 2009; Amorim Júnior *et al.*, 2010; Hasan, 2011; Mehta *et al.*, 2012; Sirasanagandla *et al.*, 2012; Saha *et al.*, 2014; Kim, 2015; Anil *et al.*, 2016; Arquez, 2017; Dupont *et al.*, 2018; Oh *et al.*, 2019). The incidence of unilateral abnormality in our study was also similar to those previously reported (Mehta *et al.*, 2012; Sirasanagandla *et al.*, 2012; Saha *et al.*, 2014). The unilateral muscle abnormality we observed in two female cases was mostly on the right side of the neck. One was classified as SCM type II originating from right sternal head and right clavicular head. The origins were clearly separated by the middle triangle and the major supraclavicular fossa, as shown in Figure 1B. The other was SCM type IV and originated from the right sternal head clavicular head and additional head. The right sternal and clavicular heads were separated by the medial minor supraclavicular fossa, but its clavicular and additional heads were separated by the medial minor supraclavicular fossa, as shown in Figure 1D. The incidence and patterns of SCM bilateral abnormalities observed in this study were also similar to those previously described (Natsis *et al.*, 2009; Saha *et al.*, 2014; Kim, 2015; Anil *et al.*, 2016; Arquez, 2017;

Table IV. Comparison of previously documented abnormalities of the sternocleidomastoid muscle among populations (N.D., not determined).

References	Populations	Observation (male: female)	Percentage of abnormality reported
Natsis <i>et al.</i> (2009)	Greek	A case report (1:0)	N.D.
Amorim Júnior <i>et al.</i> (2010)	Brazilian	A case report (1:0)	N.D.
Mehta <i>et al.</i> (2012)	Indian (New Delhi)	A case report (1:0)	N.D.
Raikos <i>et al.</i> (2012)	Australian	A case report (1:0)	N.D.
Saxena <i>et al.</i> (2013)	Indian (Haryana)	A case report (1:0)	N.D.
Saha <i>et al.</i> (2014)	Indian (West Bengal)	Research article (5:0)	27.8 %
Goswami <i>et al.</i> (2014)	Indian	A case report (male)	N.D.
Kim (2015)	Soult Korean	A case report (1:0)	N.D.
Anil <i>et al.</i> (2016)	Turkish	A case report (1:0)	N.D.
Arquez (2017)	Colombian	Research article (0:2)	11.7 %
Mansoor & Rathore (2018)	Pakistani	A case report (1:0)	N.D.
Dupont <i>et al.</i> (2018)	American (US)	A case report (1:0)	N.D.
Oh <i>et al.</i> (2019)	South Korean	A case report (0:1)	N.D.
Present study (2022)	Thai (Northeastern region)	Research article (2:2)	11.4 %

Dupont *et al.*, 2018; Oh *et al.*, 2019). Such abnormalities were observed in two males. One was SCM type III with the right and left sternal heads separated from the right and left clavicular head by the middle triangle or major supraclavicular fossa. In addition, the right middle triangle was larger than its left counterpart. The other was classified as SCM type V and consisted of three heads: the right and left sternal heads, the clavicular head, and an additional head. Notably, the right and left sternal heads were separated from the right and left clavicular heads by the medial minor supraclavicular fossa.

The presence of both major and minor supraclavicular fossa can cause confusion when attempting to determine an anatomical landmark for central venous catheterization. Such an imprecise surgical landmark may also lead to errors in surgical planning for operations on the anterior neck area (Raikos *et al.*, 2012; Mansoor & Rathore, 2018). In addition, SCM abnormalities have been reported to cause torticollis in adults (Mansoor & Rathore, 2018).

In conclusions, we reported on anatomical variations of the sternocleidomastoid muscle, a crucial surgical landmark of neck, in Thai cadavers and classified them into 5 types based on the origin of muscles with same insertion to the mastoid process. The incidence of such variation was approximately 11.4 % and did not differ by sex.

ACKNOWLEDGEMENTS. We would like to acknowledge Dr. Dylan Southard for editing the manuscript via the KKU Publication Clinic (Thailand).

MANEENIN, C.; MANEENIN, N.; JIRAPORNKUL, C.; CHAIMONTRI, C. & IAMSAARD, S. Clasificación de variaciones del músculo esternocleidomastoideo y comparación de su incidencia entre poblaciones. *Int. J. Morphol.*, 41(1):175-180, 2023.

RESUMEN: El estudio tuvo como objetivo clasificar e investigar las variaciones anatómicas del músculo esternocleidomastoideo (MEM), que se usa comúnmente como un punto de referencia anatómico para indicar la posición correcta para el cateterismo venoso central, en una población tailandesa. Se diseccionaron sistemáticamente 35 cadáveres embalsamados del noreste de Tailandia (19 mujeres y 16 hombres) para observar los músculos MEM en ambos lados para la enseñanza de la anatomía humana macroscópica. Se observaron y registraron variaciones en el origen y la inserción de MEM. La prevalencia de la variación fue de aproximadamente 11,4 % (4 de 35 cadáveres) y no fue diferente por sexo. Dichas variaciones se clasificaron en 5 tipos según el origen, la inserción y la pre-

sencia de cabezas adicionales, de la siguiente manera: tipo I (n=31; 88,6 %), tipo II (n=1; 2,85 %), tipo III (n=1 ; 2,85 %), tipo IV (n=1; 2,85 %) y tipo V (n=1; 2,85 %). También se discutieron las consideraciones clínicas y la prevalencia de la variante del músculo MEM. Dado que la incidencia de esta variación fue superior al 10 %, los cirujanos de cabeza y cuello deben considerar este tema antes de la inserción de un catéter venoso central para evitar complicaciones.

PALABRAS CLAVE: Músculo esternocleidomastoideo; Variación anatómica; Cadáveres; Clasificación.

REFERENCES

- Amorim Júnior, A. A.; Lins, C. C. S. A.; Cardoso, A. P. S. & Damascena, C. G. Variation in clavicular origin of sternocleidomastoid muscle. *Int. J. Morphol.*, 28(1):97-8, 2010.
- Anil, M.; Ayyildiz-Tamis, D.; Tasdemir, S.; Sendemir-Urkmek, A. & Gulce-Iz, S. Bioinspired materials and biocompatibility. *Emerg. Res. Bioinspired Mat. Eng.*, 294-322, 2016.
- Arquez, H. F. Muscular variation in the neck region with narrowing of the minor and major supraclavicular fossa. *Int. Arch. Med.*, 10, 2017. Available from: <http://imedicalpublisher.com/ojs/index.php/iam/article/view/2328/2216>
- Drake, R. L.; Vogl, W. A. & Mitchell, A. W. M. *Gray's Anatomy for Students*. 2nd ed. Philadelphia, Churchill Livingstone Elsevier, 2010.
- Dupont, G.; Iwanaga, J.; Altafulla, J. J.; Lachkar, S.; Oskouian, R. J. & Tubbs, R. S. Bilateral sternocleidomastoid variant with six distinct insertions along the superior nuchal line. *Anat. Cell Biol.*, 51(4):305-8, 2018.
- Goswami, P.; Yadav, Y. & Chakradhar, V. Anatomical description and clinical significance of unilateral triheaded sternocleidomastoid muscle. *Int. J. Res. Med. Sci.*, 2(3):1161-4, 2014.
- Hasan, T. Variations of the sternocleidomastoid muscle: a literature review. *Internet J. Hum. Anat.*, 1(1), 2011. Available from: https://www.researchgate.net/publication/215632430_Variations_of_the_sternocleidomastoid_muscle_-_a_literature_review#:~:text=Download%20full%20text%20PDF
- Kim, M. S. Neck kinematics and sternocleidomastoid muscle activation during neck rotation in subjects with forward head posture. *J. Phys. Ther. Sci.*, 27(11):3425-8, 2015.
- Mansoor, S. N. & Rathore, F. A. Accessory clavicular sternocleidomastoid causing torticollis in an adult. *Prog. Rehabil. Med.*, 3:20180006, 2018.
- Mehta, V.; Arora, J.; Kumar, A.; Nayar, A. K.; Ioh, H. K.; Gupta, V.; Suri, R. K. & Rath, G. Bipartite clavicular attachment of the sternocleidomastoid muscle: a case report. *Anat. Cell Biol.*, 45(1):66-9, 2012.
- Moore, K. L.; Dalley, A. F. & Agur, A. M. R. *Clinically Orientated Anatomy*. 7th ed. Philadelphia, Wolters Kluwer Health/Lippincott Williams & Wilkins, 2014.
- Natsis, K.; Apostolidis, S.; Nikolaidou, E.; Nussios, G.; Totlis, T. & Lazaridis, N. Levator clavicular muscle: a case report. *Cases J.*, 2:6712, 2009.
- Oh, J. S.; Kim, C. E.; Kim, J. & Yoon, S. P. Bilateral supernumerary clavicular heads of sternocleidomastoid muscle in a Korean female cadaver. *Surg. Radiol. Anat.*, 41(6):699-702, 2019.
- Raikos, A.; Paraskevas, G. K.; Triaridis, S.; Kordali, P.; Psillas, G. & Brand-Saberi, B. Bilateral supernumerary sternocleidomastoid heads with critical narrowing of the minor and major supraclavicular fossae: clinical and surgical implications. *Int. J. Morphol.*, 30(3):927-33, 2012.

- Saha, A.; Mandal, S.; Chakraborty, S. & Bandyopadhyay, M. Morphological study of the attachment of sternocleidomastoid muscle. *Singapore Med. J.*, 55(1):45-7, 2014.
- Saxena, A.; Prasad, A. & Sood, K. Unilateral four heads of sternocleidomastoid muscle: a rare case report. *Eur. J. Anat.*, 17(3):186-9, 2013.
- Sirasnanagandla, S. R.; Bhat, K. M. R.; Pamidi, N. & Somayaji, S. N. Unusual third head of the sternocleidomastoid muscle from the investing layer of cervical fascia. *Int. J. Morphol.*, 30(3):783-5, 2012.
- Standring, S. *Gray's Anatomy*. 40th ed. Edinburgh, Churchill Livingstone, 2008. pp.435-6.
- Wayne, W. D. *Biostatistics: A Foundations of Analysis in the Health Sciences*. 6th ed. New York, John Wiley & Sons, 1995.

Corresponding authors:

Assist. Dr. Chanwit Maneenin
Department of Anatomy
College of Medicine and Public Health
Ubon Ratchathani University
Ubon Ratchathani 34190
THAILAND

E-mail: chanwit.m@ubu.ac.th

Assoc. Prof. Sitthichai Iamsaard
Department of Anatomy
Faculty of Medicine
Khon Kaen University 40002
THAILAND

E-mail: sittia@kku.ac.th