

Prospective Protective Effects of *Arthrospira platensis* Against Acetaminophen Induced Hepato-Renal Toxicity in Rats

Efectos Protectores Prospectivos de *Arthrospira platensis* Contra la Toxicidad Hepatorrenal Inducida por Paracetamol en Ratras

Salah, Abdel-Fatah¹ & Abdel-Aziz A. A. El-Sayed^{2,3}

SALAHA, A. F. & EL-SAYED, A. A. A. A. Prospective protective effects of *Arthrospira platensis* against acetaminophen induced hepato-renal toxicity in rats. *Int. J. Morphol.*, 40(5):975-984, 2022.

SUMMARY: The toxic effects of acetaminophen appear primarily in the liver and kidney. The protective effect of blue green alga *Arthrospira platensis* on hepato-renal toxicity caused by acetaminophen was evaluated in male rats. The obtained results showed that subcutaneous injection of acetaminophen at a dose 120 & 240 µl acetaminophen/kg by weight resulted in an observed elevation in the enzyme activities of aspartate aminotransferase (AST), alanine aminotransferase (ALT) and Alkaline phosphatase (ALP), serum total lipids, total cholesterol, creatinine, total bilirubin, urea, nitric oxide (NO), L- malondialdehyde (MDA) and interleukins (IL-2 & IL-6). However, there is a decrease in the serum total protein, albumin and loss in antioxidant enzyme activities in liver including; superoxide dismutase (SOD), catalase (CAT) and glutathione reductase (GSH). This effect was found to be dose and time dependent. In spite of, pre-oral administration of *Arthrospira platensis* 1000 mg/kg .b. wt. prior acetaminophen injection succeeded to modulate the effect of the observed abnormalities caused by acetaminophen. Moreover, there were no remarkable changes in serum biomarkers of rats received *Arthrospira platensis* only at a dose of 1000 mg/kg by weight (group 2). The histopathological findings confirm the biochemical results that indicates the safety use of *Arthrospira platensis* at the selected dose in this study. Therefore, the present results clarified the protective effect of blue green alga *Arthrospira platensis* on oxidative stress, hepatic and nephrotoxicity induced by acetaminophen in male Wister rats.

KEY WORDS: Acetaminophen; *Arthrospira platensis*; Hepatotoxicity; Nephrotoxicity.

INTRODUCCIÓN

N-acetyl-para-aminophenol (APAP); Acetaminophen is a drug of para-aminophenol group. The trade names of the drug are paracetamol or Panadol. It used as antipyretic and analgesic because it blocks the production of prostaglandins, making the body less aware of the pain or injury, when administered at recommended doses (Holownia & Braszko, 2004). The drug is pre-described, since it is cheap to buy and taken in over dose. The overdoses of analgesic drug induced hepatotoxicity after 24 and 72 h following overdoses ingestion (Larson *et al.*, 2005). Moreover, the main sites of acetaminophen toxicity usually appear primarily in the liver and kidney (Azab *et al.*, 2013).

Acetaminophen is activated by cytochrome P450 to form a reactive metabolite that detoxified by reduced glutathione (GSH) forming a harmless product known as mercapturic acid (Nashwa & Abu-Aita, 2014). Such reactive

metabolite synthesized by a direct two-electron oxidation (Adams *et al.*, 2001). However, following a toxic dose of acetaminophen, total hepatic GSH is depleted so the metabolite covalently binds to cysteine groups on protein, forming acetaminophen-protein adducts (Nashwa & Abu-Aita, 2014). The Free radicals generation, arising from oxidative stress (the formation of superoxide which lead to hydrogen peroxide and peroxidation reaction by Fenton reaction) is the mechanism of hepatotoxicity caused by acetaminophen (Deavall *et al.*, 2012). Moreover, the over-dose of acetaminophen induced an increase in the concentration of serum hepatic enzymes (AST, ALT and ALP) (Sabira & Rocha, 2008). In addition, the chronic doses of acetaminophen are usually accompanied with elevated serum total bilirubin level (Gosh *et al.*, 2010). Parallel, the oxidative stress led to damage in cell membrane structure and intracellular organelles, thus increasing protein permeability and loss in urine (Moawad, 2007). Moreover,

¹ Botany and Microbiology Department, Faculty of Science, Zagazig University, Zagazig 44519, Egypt.

² Biology Department, Faculty of Science, Islamic University of Madinah, Madinah42351, Saudi Arabia.

³ Zoology Department, Faculty of Science, Zagazig University, Zagazig 44519, Egypt.

the toxic per oxidative products cause widespread damage of macromolecules (Sinclair *et al.*, 1991). It is worth mentioned that, the decreased MDA levels in animals decrease the ongoing lipid peroxidation in normal liver cell. With regard to serum lipid profile Gini & Muraleedhara (2010) found that during acetaminophen toxicity, the lipid profile of serum and tissues increased, as well as membrane structure and function altered, this is shown by the increase in cholesterol with subsequent decreases in phospholipids concentrations, hence increased cholesterol to phospholipids ratio.

Arthrospira platensis a blue green alga of Oscillatoriaceae family. It has drawn more attention of pharmacologist and most promising aquatic plant, due to its ease of cultivation, its nutritional significance as it is a rich source of vitamins, minerals, essential fatty acids and antioxidant pigments such as carotenoids as well as it possesses a diverse biological activities, such as it reduces toxicity of liver, kidney and testes (Khan *et al.*, 2005), antioxidant (Dartsch, 2008), liver- protecting (Vadiraja *et al.*, 1998), anticancer (Zhang *et al.*, 2014), antiviral (Murugan & Radhamadhavan, 2011), anti-allergy, blood vessel-relaxing (Gur *et al.*, 2013) and lowering the blood lipid (Colla *et al.*, 2008).

The amount of phycocyanin in *Arthrospira* varies up to 15 % of the dry weight. Phycocyanin has been reported as a potent antioxidant and anti-inflammation (Gur *et al.*, 2013), beside it expressed liver-protective effects (Vadiraja, 1998). Moreover, Khan *et al.* (2005) shown that *Arthrospira* with antioxidant properties effectively attenuated the induced cardio toxicity in rat as evidenced from a significant elevation in plasma urea and creatinine levels. However, Pretreatment of rats with *Arthrospira* protect the rats from CsA-induced nephrotoxicity since; there was a significant increase in plasma and kidney tissue MDA. Moreover, Karadeniz *et al.* (2008) found that *Arthrospira platensis* elicited significant nephroprotective activity by decreasing lipid peroxidation (MDA) and elevated the levels of GSH, SOD, GPX, NO, creatinine and urea.

MATERIAL AND METHOD

Forty-two male albino rats weighting 150-160 g (age of 50-60 days) were used in the experimental investigation of this study. They were obtained from the animal house of Research Institute of Ophthalmology, El-Giza, Egypt. They were kept under observation for about 15 days before the onset of the experiment to exclude any inter current infection. The chosen animals were housed in plastic cages with good aerated covers at normal atmospheric temperature ($25\pm 5^\circ\text{C}$)

as well as 12 h daily normal light periods. Moreover, they were given access of water and supplied daily with standard pellet diet *ad libitum*. All procedures are in accordance with Canadian Council on Animal Care (Canadian Council on Animal Care, 1993).

Experimental design. The rats were randomly divided into six main groups, each one contains seven rats. Group I: injected by normal saline and act as a negative control. Group II: Receive oral dose of *Arthrospira platensis* at 1000 mg/kg by weight and act as a positive control. Group III: injected subcutaneously with a dose of 120 μl acetaminophen/kg by weight. Group IV: injected subcutaneously with a dose of 120 μl acetaminophen/kg by weight + *Arthrospira* at a dose of 1000 mg/kg by weight. Group V: injected subcutaneously with a dose of 240 μl acetaminophen/kg by weight. Group VI: injected subcutaneously with a dose of 240 μl acetaminophen/kg by weight + *Arthrospira* at a dose of 1000 mg/kg by weight. At the end of experimental period (three weeks), the rats were slightly anaesthetized by diethyl ether (Sigma Chem. Co St Louis, Mo. U.S.A) then sacrificed.

Determination of biochemical parameters. Blood samples were collected at the end of experimental period (21 days) from all animals groups (control and experimental groups) and put into coagulant bottles, left to clot for two h. Samples were obtained by centrifugation clotted blood at 3000 rpm to separate serum for analysis of serum alanine aminotransferase (ALT) and aspartate aminotransferase (AST) according to Reitman & Frankel (1957), alkaline phosphatase (ALP) according to Tietz *et al.* (1983). Cholesterol was measured according to Allain *et al.* (1974). Serum total protein was measured according to Lowry *et al.* (1951). Total bilirubin was determined according to Schmidt & Eisenburg (1975). Renal products; creatinine was determined according to Larsen (1972) and urea according to Coulombe & Favreau (1963).

Determination of tissue lipid peroxidation and antioxidant enzymes. Hepatic and renal lipid peroxidation content was evaluated by measurement of MDA according to Mihara & Uchiyama (1978). Oxidative stress markers were assessed by estimating superoxide dismutase (SOD) according to Nishikimi *et al.* (1972), catalase (CAT) according to Aebi (1984), reduced glutathione (GSH) according to Beutler *et al.* (1963). Serum IL-2 and IL-6 were determined by ELISA according method of Evereklioglu *et al.* (2002).

Histopathological study. Samples of liver and kidney from all treated groups were immediately fixed in 10 % neutral formalin, embedded in paraffin and routinely processed for sectioning. 4 μm paraffin sections were stained with hematoxylin and eosin stain then investigated and photographed under light microscope.

RESULTS

The influence of *Arthrospira platensis* on serum liver (AST, ALT, ALP, bilirubin) and kidney (urea, creatinine, total protein, albumin) and total glyceride and cholesterol concentration in acetaminophen-induced hepato-renal injury in rats.

In acetaminophen injected rats the activities of AST, ALT and ALP (Figs. 1a-c) clarified that there is an increase in serum liver enzymes (AST, ALP and ALT) as compared to untreated group. However, Pre-treatment with *Arthrospira* prior to acetaminophen intoxication, ameliorate the changes in most of the studied serum parameters in dose - and time - dependent manner. Since, the high percentages of decrease were 75.2 and 74.44 at third week in case of AST and ALT they were at dose of 120 µl acetaminophen/kg by weight, however, the decrease percentages were 77.8 and 77.56 at 240 µl acetaminophen/kg by weight, respectively.

Concerning the total bilirubin level (Fig. 1d) there is an increase in total bilirubin after administration of acetaminophen doses 120 and 240 µl/kg by weight. The highest percentage of increase were 60, 58.3 and 29.9, 35.5 % respectively. This may indicate that both doses are hepatotoxic and cause the liver injury. However, oral administration of *Arthrospira* at doses of 120 & 240 µl

acetaminophen /kg by weight reduced total bilirubin level as compared to non-treated group. The percentages of decrease were 29.29 and 35.5 % respectively.

The results in Figures 2a and 2b showed that exposure of rats to (120 and 240 µl acetaminophen/kg by weight) disturbed the kidney function tests; serum urea and creatinine leading to an increase in both fractions as compared with its corresponding untreated groups. The highest increase in urea and creatinine at 120 µl acetaminophen/kg by weight since they were 240.5 and 214.3 % while they were 296.4 and 257.14 % at dose 240 µl acetaminophen/kg by weight, respectively. This may indicate that both doses are nephrotoxic. On the other hand, supplementation of *Arthrospira* reversed these changes with a percentage of decrease reached 24.97 and 40.76 % in urea and 72.73 and 82 % in creatinine.

The results in Figure 2c and 2d showed that injection of rats with (120 and 240 µl acetaminophen/kg by weight) led to reduction in both total protein and albumin as compared with their corresponding untreated groups. The highest decrease were 17.21 and 24.3 % in total protein and 32.3 and 35.5 % in albumin respectively. It could be stated that hypoproteinemia and the decrease in albumin is a feature of liver injury due to significant fall in protein synthesis. However, pre-oral administration of *Arthrospira* increased serum total protein, with a percentage reached 15.6 and 57.14

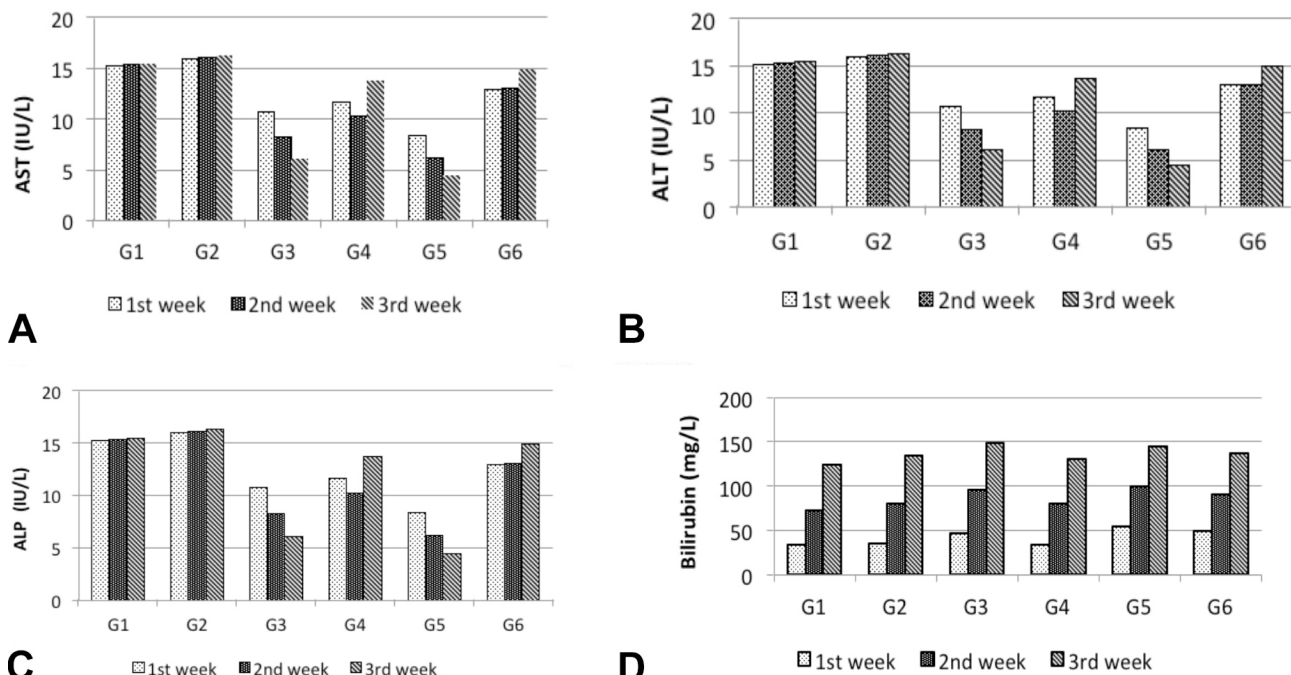


Fig. 1. A) The effect of *Arthrospira platensis* on acetaminophen-treated albino rats' serum AST (IU/L) activity. B) The effect of *Arthrospira platensis* on acetaminophen-treated albino rats' serum ALT (IU/L) activity. C). The effect of *Arthrospira platensis* on acetaminophen-treated albino rats' serum ALP (IU/L) activity. D) The effect of *Arthrospira platensis* on acetaminophen-treated albino rats' serum bilirubin (mg/L) concentration.

% and albumin with 36.7 & 70 % at 120 and 240 µl acetaminophen/kg by weight, respectively.

The total triglyceride and total cholesterol (Figs. 3a and 3b) were increased in rats treated with acetaminophen if compared with negative control. The highest percentages of increase were 38.24, 61.76 % in total triglyceride and

38.26, 37.17 % in total cholesterol at 120 and 240 µl acetaminophen/kg by weight, after incubation period one, third week respectively. On the other hand, pre-treatment with *Arthrospira* at dose of 1000 mg/kg by weight, prior to acetaminophen intoxication effectively reduced the two fractions, with a percentage (-26.59 and -9.64 %) in total triglyceride and (-24.63 and -25.4 %) in total cholesterol.

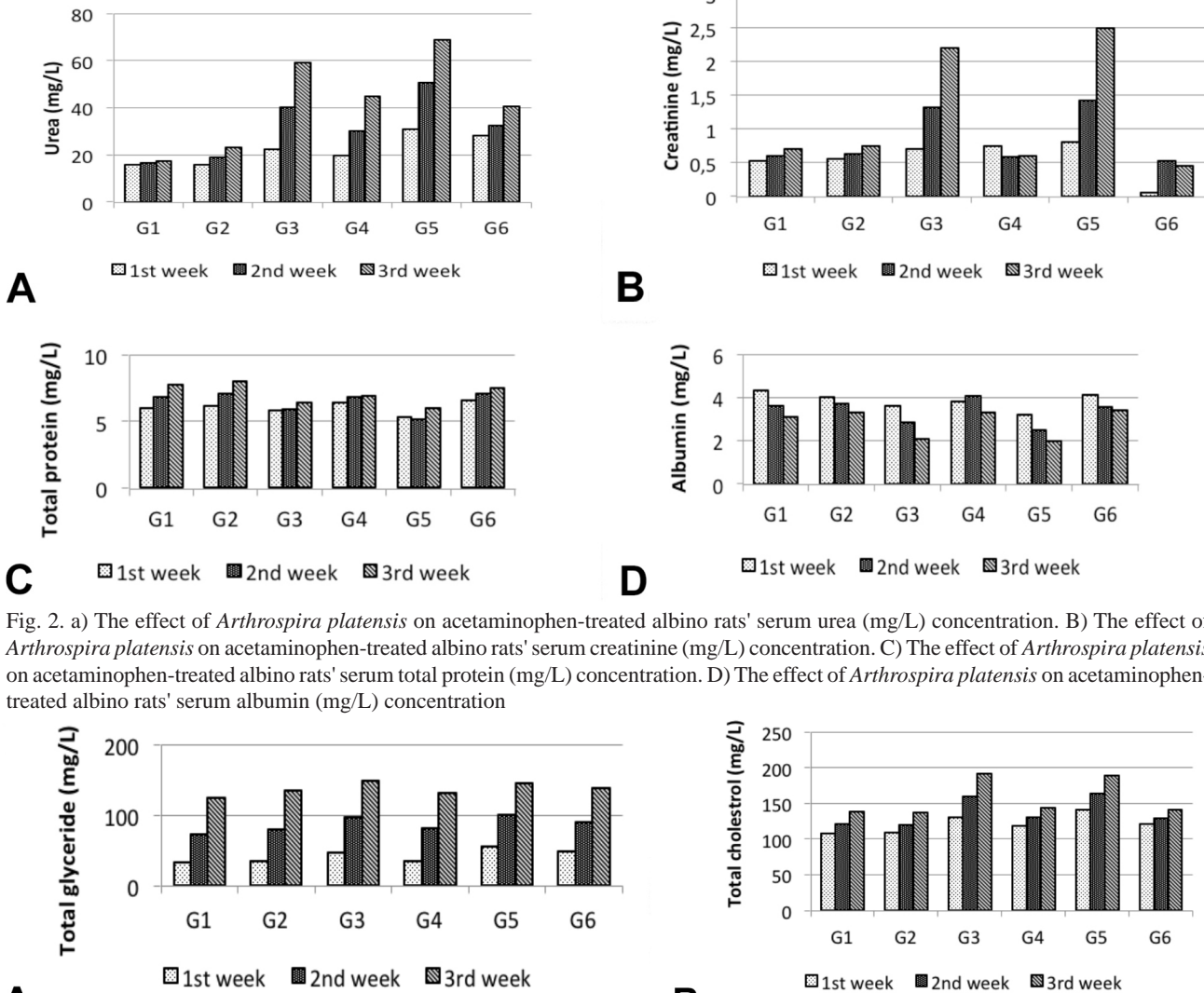


Fig. 2. a) The effect of *Arthrospira platensis* on acetaminophen-treated albino rats' serum urea (mg/L) concentration. B) The effect of *Arthrospira platensis* on acetaminophen-treated albino rats' serum creatinine (mg/L) concentration. C) The effect of *Arthrospira platensis* on acetaminophen-treated albino rats' serum total protein (mg/L) concentration. D) The effect of *Arthrospira platensis* on acetaminophen-treated albino rats' serum albumin (mg/L) concentration

Fig. 3. A) The effect of *Arthrospira platensis* on acetaminophen-treated albino rats' serum total glyceride (mg/L) concentration. B) The effect of *Arthrospira platensis* on acetaminophen-treated albino rats' serum total cholesterol (mg/L) concentration.

The influence of *Arthrospira platensis* on tissue lipid peroxidation, oxidative stress and antioxidant biomarkers in acetaminophen-induced hepato-renal injury in rats.

The results in Figures 4a, 4b and 4c revealed that there is a decrease in the activities of liver antioxidant enzymes (SOD, CAT and GSH) in the acetaminophen

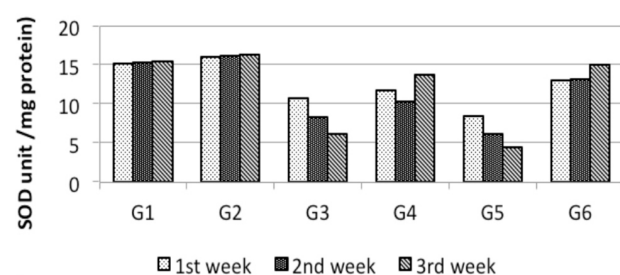
injected rats as compared with corresponding control especially at the last week. The highest percentages of decrease reached 60.83 and -71.43 % in SOD, 45.49 and -46.9 % in CAT, 53.77 and -56.95 % in GSH either at 120 or 240 µl acetaminophen/kg by weight injected rats respectively. This indicates the liver was damaged by acetaminophen application. On the other hand, pre-administration of *Arthrospira* either at (120 & 240 µl

acetaminophen/kg by weight) found to exhibit a hepatoprotective effect as demonstrated by enhanced activities of antioxidant enzymes with 126.5 and 238.4 % in SOD, 62.97 and 75.85 % in CAT, 99.9 and 139.39 % in GSH respectively, as well as tends to decrease in MDA level with a the percentages (51.67, 51.53 %) at 3rd week respectively when compared with non-treated group (Fig. 4d).

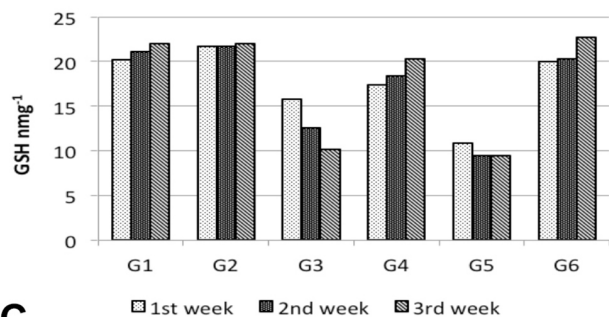
Contrarily, administration of (120 & 240 µl acetaminophen/kg by weight) to rats markedly increase in the lipid peroxidation of the liver tissues as indicated by increased level of malondialdehyde (MAD) in comparison

with the control (Fig. 4d), the highest percentage of increases were 16.57, 129.57 %, respectively.

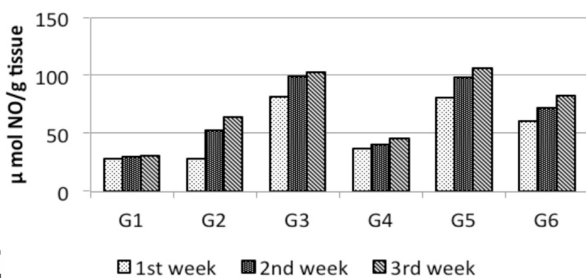
The serum nitric oxide (NO) level (Fig. 4e) showed that there is an increase in serum NO in acetaminophen injected rats either at 120 µl acetaminophen/kg by weight during 2nd week or 240 µl acetaminophen/kg by weight during 3rd, respectively. On the other hand, pre-treatment with *Arthrospira platensis* (G4 & G6) groups, led to decrease in serum NO content with a percentage reached to 59.5 and 26.79 % compared with acetaminophen either at 120 or 240 µl acetaminophen/kg by weight at 2nd week.



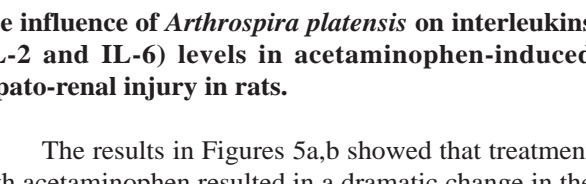
A



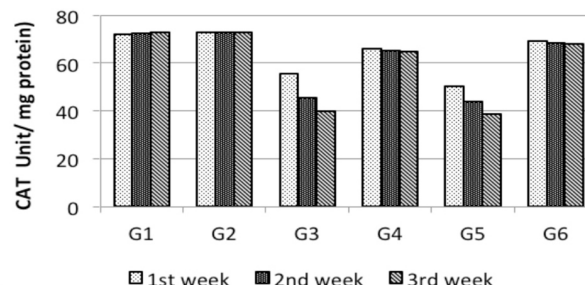
B



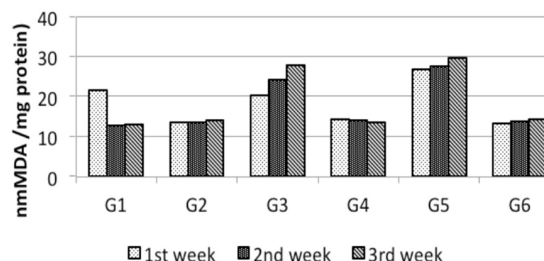
C



D



E



F

Fig. 4. A) The effect of *Arthrospira platensis* on acetaminophen-treated albino rats' serum SOD (unit/mg protein) concentration. B) The effect of *Arthrospira platensis* on acetaminophen-treated albino rats' serum CAT (unit/mg protein) concentration. C) The effect of *Arthrospira platensis* on acetaminophen-treated albino rats' serum GSH (nmng-1) concentration. D) The effect of *Arthrospira platensis* on acetaminophen-treated albino rats' serum MDA (nmol of MDA/mg protein) concentration. E) The effect of *Arthrospira platensis* on acetaminophen-treated albino rats' serum NO (µmol/g tissue) concentration.

The influence of *Arthrospira platensis* on interleukins (IL-2 and IL-6) levels in acetaminophen-induced hepato-renal injury in rats.

The results in Figures 5a,b showed that treatment with acetaminophen resulted in a dramatic change in the hepatic level of IL-2 and IL-6. Since the administered rats showed a highly increase in serum, IL-2 and IL-6 as

compared to normal control group. On the other hand, pre-treatment with *Arthrospira* (G4 and G6) reversed harmful side effect of the drug when compared with rats injected with acetaminophen only at 120 or 240 µl/kg by weight.

Histopathological examination of hepatic and renal tissues. The light microscopic observations revealed that

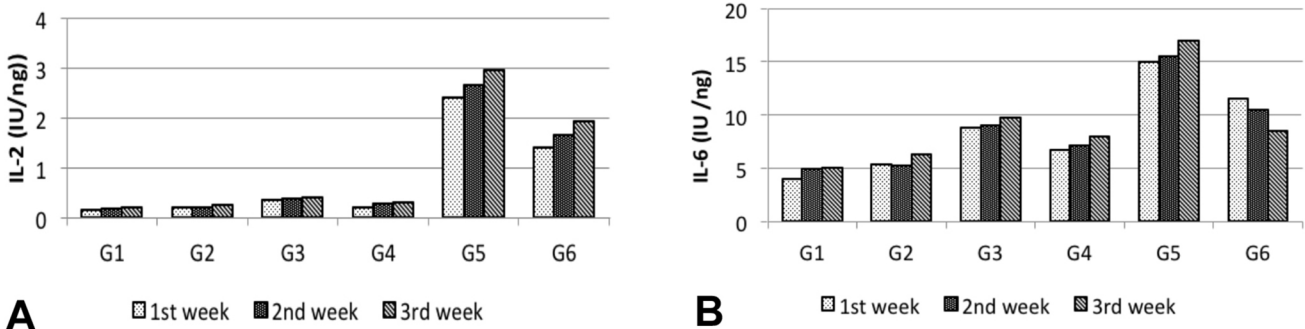


Fig. 5. A) The effect of *Arthrospira platensis* on acetaminophen-treated albino rats' serum IL-2 (IU/ng) level. B) The effect of *Arthrospira platensis* on acetaminophen-treated albino rats' serum IL-6 (IU/ng) level.

high dose of acetaminophen causes mild histopathological lesions as dilatation of the hepatic sinusoids with mild blood congestion and moderate necrosis of hepatocytes associated with lymphocytic infiltration (Fig. 6b). the hepatocytes attain their activity, architecture, and normal appearance in *Arthrospira platensis* treated group (Fig. 6c) where many cell appeared binucleated.

On the other hand, kidney of acetaminophen treated groups showed glomerular lobulation, slight widening of the proximal convoluted tubules losing their apical margins while their cells became edematous (Fig. 7b). Meanwhile, in *A. platensis* administered group, the kidney restored its normal structure with moderately dilatation of bowman's space (Fig. 7c).

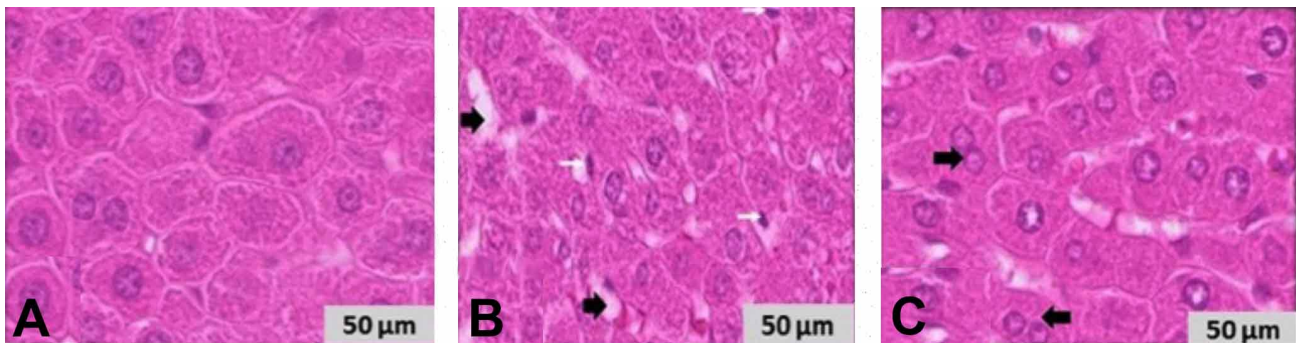


Fig. 6. H&E-stained photomicrographs of the livers sections of male rat (Group I, V, and VI) showing: A) Normal hepatocytes. B) Congestion and dilatation of hepatic sinusoid (black arrow) and mild lymphocytosis (white arrow), slight necrotic hepatocytes. C) Binucleated hepatocytes arrow. [H&E, X400]

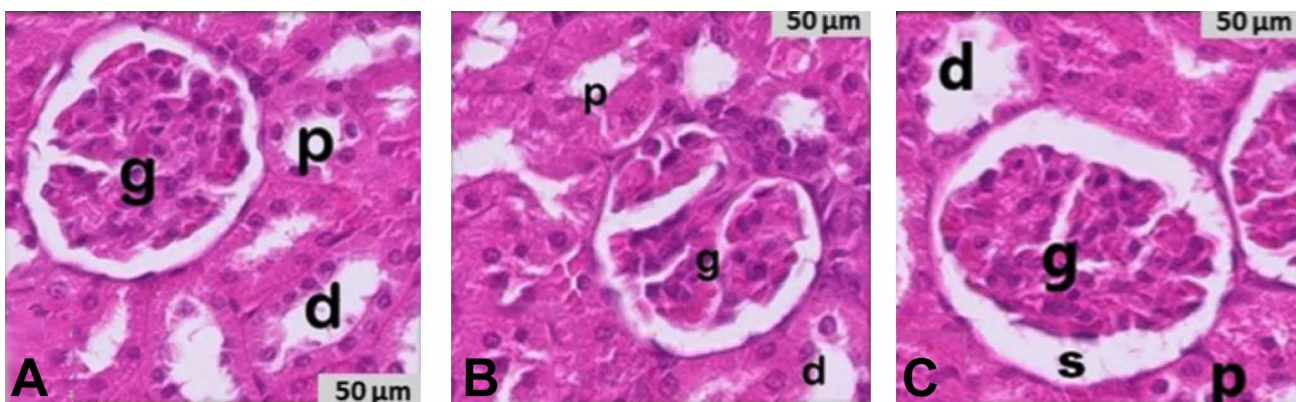


Fig. 7. H&E-stained photomicrographs of the kidneys sections of male rat (Group I, V, and VI) showing: A) Normal kidney with glomerulus (g); proximal (p) and distal (d) convoluted tubules. B) Lobulation of the glomerulus (g) and edematous renal tubules. C) Dilatation of the renal tubules and enlargement of bowman's space (s). [H&E, X400]

DISCUSSION

Acetaminophen (N-acetyl-para-aminophenol, paracetamol, APAP) has a good safety profile at therapeutic levels, but it can cause severe liver and kidney toxicity if taken in large amounts (Ye *et al.*, 2018; Hegazy *et al.*, 2021). Our results showed an increased in serum liver enzyme activities (AST, ALT and ALP) after injection with acetaminophen as compared to untreated group. These findings are in agreement with Molander *et al.* (1955) who stated that, these enzymes are considered as sensitive indicator of hepatic injury to the hepatocytes, alters their transport function and membrane permeability, leading to leakage of enzymes from the cells through the blood. This leakage causes an increase in the level of transaminases in serum (Yadav & Dixit, 2003). Also, indicate cellular leakage and loss of functional integrity of hepatocytes cell membrane (Rizk *et al.*, 2016), and may be an indication of liver damage as well as cell necrosis due to the formation of NAPQI in excess of GSH detoxification capacity (Iweala *et al.*, 2011). However, Pre-treatment with *Arthrospira* prior to acetaminophen intoxication, ameliorate the changes in most of the tested serum parameters in dose and time dependent manner. These findings run parallel to Iweala *et al.* (2011) claimed that a significant reduction in the enzyme activities of rats treated with *Arthrospira*. Moreover, the animals receiving *Arthrospira platensis* prior to the administration of diclofenac significantly counteracted the induced decrease in AST, ALT and ALP activities, total bilirubin, LDL and total cholesterol in serum and lipid peroxidation in liver tissue.

There is an increase in total bilirubin after administration of the two of acetaminophen (120 & 240 µl/kg by weight). These results are in concomitant with Gosh *et al.* (2010) who found that chronic doses of acetaminophen are usually associated with elevated serum total bilirubin level. Moreover, the observed hyperbilirubinemia may be attributed to excessive heme destruction and the block of biliary tract in acetaminophen treated rat (Adeneye & Benebo, 2008). This effect may be attributed to its vitamin c content. These are in agreement with other workers (Ajiboye *et al.*, 2010).

The increase in urea and creatinine upon rat exposure to (120 or 240 µl acetaminophen/kg by weight), are in accordance with those results of Sharoud (2015). Moreover, the induced renal damage by acetaminophen was evident by elevation of plasma creatinine levels (Abraham, 2004). This explained by the presence of strong correlation between nephrotoxicity and oxidative stress. The elevated H₂O₂ and O₂ – production due to inactivation of CAT,

alters the filtration surface area and modifies the filtration coefficient; both factors could decrease the glomerular filtration leading to accumulation of urea and creatinine in the blood (Ajami *et al.*, 2010).

Regarding total protein and albumin the reduction in both fractions because of injection of rats with 120 and 240 µl acetaminophen/kg by weight are in agreement with Sharoud (2015) showed that a significant decrease in total protein content in acetaminophen treated rats. In parallel, Aly & Aly (2006) attributed the decrease in total protein to increase in messenger RNA degradation, or due to protein shift toward catabolism and disability of the intoxicated liver to synthesize protein (el-Fakahany *et al.*, 1993). As well as, Soliman *et al.* (2014) reported that the decrease in serum total protein, albumin and globulin levels and the increase in serum urea concentration reflects kidney injury. This was reflected on its defective re-absorptive capacity of albumin and protein, which led to their appearance in high quantities in the urine (Abdel-Raheem *et al.*, 2009). Finally, Abdel-Zaher *et al.* (2008) reported that overdose of acetaminophen induced the nephrotoxicity was characterized by damage and necrosis in the proximal tubule. This may be attributed to antioxidant properties of *Arthrospira*. These results are in harmony with Abraham (2004) who stated that supplementation of *Arthrospira platensis* led to rise in protein and albumin levels, this suggests that the stabilization of endoplasmic reticulum leading to protein synthesis. The hepatotoxicity not due to acetaminophen itself, but result from one of its metabolites called, N- acetyl-benzoquinone imine (Nashwa & Abu-Aita, 2014).

The total triglyceride and total cholesterol were increased in rats treated with acetaminophen if compared with negative control. One can deduce that acetaminophen intoxication may lead to a hyperlipidemia that may reflect the impairment of liver cells to metabolize lipid (Sharoud, 2015). Moreover, the hepatotoxicity induced by acetaminophen is associated with high cholesterol and triglyceride levels (Abdel-Zaher *et al.*, 2008). Since the drug seems to cause impairment in lipoprotein mechanism (Gupta *et al.*, 2004). It could be stated that the elevation of triglycerides level may be due to increased availability of free fatty acids, decreased hepatic release of lipoprotein and increased esterification of free fatty acids (Kanchana & Sadiq, 2011). On the other hand, pre-treatment with *Arthrospira* at dose of 1000 mg/kg by weight prior to acetaminophen intoxication effectively reduced the two fractions.

The activities of antioxidant enzymes, SOD, CAT and GSH, were decreased in the acetaminophen injected rats compared with corresponding control especially at the

last week. These results are in concomitant with those of Sabina *et al.* (2009). Contrarily, administration of 120 and 240 µl acetaminophen/kg by weight increased markedly the lipid peroxidation in the liver tissues as indicated by increased level of (MDA) in comparison with the control. It could be stated that the increase in lipid peroxidation coupled with the decrease in the antioxidant enzymes activity induced hepatotoxicity (Gini & Muraleedhara, 2010). The increase in MDA level in the liver may enhanced lipid peroxidation, resulting in tissue damage and failure of antioxidant mechanisms to stop the formation of excessive free radicals as stated by Sabina *et al.* (2009).

Moreover, The overdose of acetaminophen administration caused a remarkable decrease in serum GSH content, as well as it will saturate the metabolic pathway, decreases the liver clearance of drug and allows higher amounts of the unmetabolized drug to come in contact with the kidney . It was documented that, the hepatotoxicity of acetaminophen is not due to the drug itself, but resulted from one of its metabolites called, N- acetyl-benzoquinone imine (NAPQI). NAPQI will also be formed in the kidneys, giving rise to toxicity but much later than in the liver. Acetaminophen cause renal damages as well as elevated levels of renal MDA, marked depletion of GSH levels and antioxidant enzyme activity; it deteriorated the renal functions as assessed by the increased plasma urea and creatinine levels as compared to control rats (Sabina *et al.*, 2009). On the other hand, pre-administration of *Arthrospira* either at 120 & 240 µl acetaminophen/kg by weight found to exhibit hepatoprotective by enhancement the activities of antioxidant enzymes (SOD , CAT & GSH) as well as decrease in MDA level. It can be deduced that *Arthrospira* seems to preserve the structural integrity of the hepatocellular membrane as evident from the significant reduction in acetaminophen-induced rise in serum enzymes and increase in MDA in rats (Sabina *et al.*, 2009). Parallel, C- phycocyanin of *Arthrospira* inhibited lipid peroxidation in liver cells of rats treated with acetaminophen (Gini & Muraleedharam, 2010). Finally, the treatment with *Arthrospira platensis* reversed these changes due to its free radical scavenging activity (Karadeniz *et al.*, 2008).

There is an increase in serum nitric oxide in acetaminophen injected rats either at 120 µl acetaminophen/kg by weight during 2nd week or 240 µl acetaminophen /kg .b. wt. during 3rd week respectively. This can be explained on the basis of the drug increases the serum levels of nitrate, nitrite in addition to enhances the generation of superoxide radical; in the presence of equimolar concentration of NO will lead to the formation of nitrating agent peroxynitrite which not only make nitration of tyrosine forming nitrotyrosine, but also attack a wide range of biological

targets as oxidation of lipid, proteins or DNA (Michael *et al.*, 2001). Peroxynitrite is normally detoxified by GSH/ GSH peroxidase, this preventing protein nitration *in vitro*. So, GSH peroxidase is a key enzyme in this defense mechanism (Michael *et al.*, 2001). On the other hand, pre-treatment with *Arthrospira platensis* G4 and G6, led to decrease in serum NO content. These results are in agreement with those of Karadeniz *et al.* (2008) found that *Arthrospira platensis* at dose of 1000 mg/kg elicited significant nephroprotective activity by decreasing NO and elevating GSH, SOD, GSH-Px level, indicating the therapeutic potential of *Arthrospira* against acetaminophen induced nephrotoxicity and ROS production.

The treatment with acetaminophen resulted in dramatic changes in the serum level of IL-2 & IL-6. Since the administered rats showed a highly increase in serum IL-2 and IL-6 compared to normal control group. These results run parallel to (Bauer *et al.*, 2000; James *et al.*, 2003) they claimed that acetaminophen toxicity was associated with a release of multiple cytokines. On the other hand, pre-treatment with *Arthrospira* (G4 and G6) reversed harmful side effect of the drug when compared with rats injected with acetaminophen only at 120 or 240 µl/kg by weight These results run parallel to those of Trushina *et al.* (2007) who reported that *Arthrospira* may have an immune-enhancing effect and theoretically may interfere with immunosuppressive therapy and significantly decreased immune response. Moreover, Blinkova *et al.* (2001) stated that *Arthrospira platensis* produces an immune-stimulating effect by enhancing the resistance of human, mammals, chickens and fishes to infections and its capacity of influencing hemopoiesis, stimulating the production of antibodies and cytokines. In this context, our histological findings support the biochemical results and, the supplementation of *Arthrospira platensis* prevented acetaminophen-induced liver and kidney dysfunction. These findings showed that *Arthrospira platensis* mediated suppression of inflammation plays a central role in their hepato-renal protective effects.

CONCLUSION

In conclusion, our results clarified that *Arthrospira platensis* has elicited both hepatic and nephroprotective activity on acetaminophen-induced damage to liver and kidney in male Wistar rat. This protective effect may be due to the presence of antioxidant compounds as flavonoids, triterpenes or its free radicals scavenging activities, it has diverse biological activities as well as nutritional significance and an immune-enhancing effect.

ACKNOWLEDGMENTS. The authors would like to thank Dr. Sayed Nasr, Department of Zoology, Faculty of Science, Zagazig University, Zagazig, Egypt, for his support. Authors also acknowledge the efforts of all staff members of Zoology and Botany Departments, Faculty of Science, Zagazig University, Zagazig, Egypt for their assistance during the research work.

FUNDING STATEMENT. This research did not receive any specific grant from funding agencies in the public, commercial, or not-for-profit sectors.

SALAHA, A. F. & EL-SAYED, A. A. A. Efectos protectores prospectivos de *Arthrospira plantensis* contra la toxicidad hepatorenal inducida por paracetamol en ratas. *Int. J. Morphol.*, 40(5):975-984, 2022

RESUMEN: Los efectos tóxicos del paracetamol aparecen principalmente en el hígado y el riñón. Se evaluó en ratas macho Wistar el efecto protector del alga verde azulada *Arthrospira platensis* sobre la toxicidad hepatorenal causada por paracetamol. Los resultados obtenidos mostraron que la inyección subcutánea de paracetamol a dosis de 120 y 240 µl de paracetamol/kg, resultó en una elevación en las actividades enzimáticas de la aspartato aminotransferasa (AST), alanina aminotransferasa (ALT) y fosfatasa alcalina (ALP), lípidos séricos totales, colesterol total, creatinina, bilirrubina total, urea, óxido nítrico (NO), L-malondialdehído (MDA) e interleucinas (IL-2 e IL-6). Sin embargo, hay una disminución en la proteína sérica total, albúmina y pérdida en las actividades de las enzimas antioxidantes en el hígado, incluyendo; superóxido dismutasa (SOD), catalasa (CAT) y glutatión reductasa (GSH). Se encontró que este efecto era dependiente de la dosis y el tiempo. A pesar de la administración preoral de *Arthrospira platensis* 1000 mg/kg, la inyección previa de acetaminofeno logró modular el efecto de las anomalías observadas causadas por el acetaminofeno. Además, no hubo cambios notables en los biomarcadores séricos de ratas que recibieron *Arthrospira platensis* solo a una dosis de 1000 mg/kg (Grupo 2). Los hallazgos histopatológicos confirman los resultados bioquímicos que indican la seguridad del uso de *Arthrospira platensis* a la dosis seleccionada en este estudio. Por lo tanto, los presentes resultados aclararon el efecto protector del alga verde azulada *Arthrospira platensis* sobre el estrés oxidativo, la toxicidad hepática y la nefrotoxicidad inducida por paracetamol en ratas Wistar macho.

PALABRAS CLAVE: Acetaminofeno; *Arthrospira platensis*; Hepatotoxicidad; Nefrotoxicidad.

REFERENCES

Abdel-Raheem, I. T.; Abdel-Ghany, A. A. & Mohamed, G. A. Protective effect of quercetin against gentamicin-induced nephrotoxicity in rats. *Biol. Pharm. Bull.*, 32(1):61-7, 2009.

Abdel-Zaher, A. O.; Abdel-Hady, R. H.; Mahmoud, M. M. & Farrag, M. M. Y. The potential protective role of alpha-lipoic acid against acetaminophen-induced hepatic and renal damage. *Toxicology*, 243(3):261-70, 2008.

Abraham, P. Oxidative stress in paracetamol-induced pathogenesis: (I). Renal damage. *Indian J. Biochem. Biophys.*, 42(1):59-62, 2004.

Adams, M. L.; Pierce, R. H.; Vail, M. E.; White, C. C.; Tonge, R. P.; Kavanagh, T. J.; Fausto, N.; Nelson, S. D. & Bruschi, S. A. Enhanced acetaminophen hepatotoxicity in transgenic rat over expressing Bcl-2. *Mol. Pharmacol.*, 60(5):907-15, 2001.

Adeneye, A. A. & Benebo, A. S. Protective effect of the aqueous leaf and seed extract of *Phyllanthus amarus* on gentamicin and acetaminophen-induced nephrotoxic rats. *J. Ethnopharmacol.*, 118(2):318-23, 2008.

Aebi, H. Catalase *in vitro*. *Methods Enzymol.*, 105:121-6, 1984.

Ajami, M.; Eghtesadi, S.; Pazoki-Toroudi, H.; Habibey, R. & Ebrahimi, S. A. Effect of Crocus sativus on gentamicin induced nephrotoxicity. *Biol Res.*, 43(1):83-90, 2010.

Ajiboye, T. O.; Salau, A. K.; Yakubu, M. T.; Oladiji, A. T.; Akanji, M. A. & Okogun, J. I. Acetaminophen perturbed redox homeostasis in Wistar rat liver: protective role of aqueous *Pterocarpus osun* leaf extract. *Drug Chem. Toxicol.*, 33(1):77-87, 2010.

Allain, C. C.; Poon, L. S.; Chan, C. S.; Richmond, W. & Fu, P. C. Enzymatic determination of total serum cholesterol. *Clin. Chem.*, 20(4):470-5, 1974.

Aly, H. F. & Aly, S. A. Essential role of Citrus reticulate and mirazid in treatment of *Schistosoma mansoni* infected rat: biochemical and paracytological studies. *Pol. J. Food Nutr. Sci.*, 56(4):461-7, 2006.

Azab, S. S.; Abdel-Daim, M. & Eldahshan, O. A. Phytochemical, cytotoxic, hepatoprotective and antioxidant properties of *Delonix regia* leaves extract. *Med. Chem. Res.*, 22:4269-77, 2013.

Bauer, I.; Vollmar, B.; Jaeschke, H.; Rensing, H.; Kraemer, T.; Larsen, R. & Bauer, M. Transcriptional activation of heme oxygenase-1 and its functional significance in acetaminophen-induced hepatitis and hepatocellular injury in the rat. *J. Hepatol.*, 33(3):359-406, 2000.

Beutler, E.; Duron, O. & Kelly, B. M. Improved method for the determination of blood glutathione. *J. Lab. Clin. Med.*, 61:882-8, 1963.

Blinkova, L. P.; Gorobets, O. B. & Baturo, A. P. Biological activity of Spirulina. *Zh. Mikrobiol. Epidemiol. Immunobiol.*, (2):114-8, 2001.

Canadian Council on Animal Care (CCAC). *Guide to the Care and Use of Experimental Animals*. Volume 1. 2nd ed. Ottawa, Canadian Council on Animal Care, 1993. pp.1-298.

Colla, L. M.; Muccillo-Baisch, A. L. & Vieira Costa, J. A. Spirulina platensis effects on the levels of total cholesterol, HDL and triacylglycerols in rabbits fed with a hypercholesterolemic diet. *Braz. Arch. Biol. Technol.*, 51(2):405-11, 2008.

Coulombe, J. J. & Favreau, L. A new simple semimicro method for colorimetric determination of urea. *Clin. Chem.*, 9:102-8, 1963.

Dartsch, P. C. Antioxidant potential of selected *Arthrospira platensis* preparations. *Phytother. Res.*, 22(5):627-33, 2008.

Deavall, C. D.; Martin, E. A.; Horner, J. M. & Roberts, R. Drug-induced oxidative stress and toxicity. *J. Toxicol.*, 2012:645460, 2012.

el-Fakahany, A. F.; Abdalla, K. F.; el-Hady, H. M.; Abd el-Aziz, S.M. & Afifi, L. M. The effect of praziquantel treatment on the liver functions, worm burden, and granuloma size using two drug regimen in murine *Schistosoma mansoni* infection. *J. Egypt. Soc. Parasitol.*, 23(3):877-86, 1993.

Evereklioglu, C.; Er, H.; Türköz, Y. & Cekmen, M. Serum levels of TNF-alpha, sIL-2R, IL-6, and IL-8 are increased and associated with elevated lipid peroxidation in patients with Behçet's disease. *Mediators Inflamm.*, 11(2):87-93, 2002.

Gini, C. K. & Muraleedhara, G. K. Hepatoprotective effect of *Arthrospira lonar* on acetaminophen-induced liver damage in rats. *Asian J. Exp. Biol. Sci.*, 1:614-23, 2010.

Gosh, J.; Das, J.; Manna, P. & Sil, P. C. Acetaminophen induced renal injury via oxidative stress and TNF-alpha production: therapeutic potential of arjunolic acid. *Toxicology*, 2688(1-2):8-18, 2010.

- Gupta, A.; Gupta, V.; Thapar, S. & Bhansali, A. Lipid-lowering drug atrovastatin as an adjunct in the management of diabetic macular edema. *Am. J. Ophthalmol.*, 137(4):675-82, 2004.
- Gur, C. S.; Erdogan, D. K.; Onbasilar, I.; Atilla, P.; Cakar, N. Gurhan, I. D. *In vitro* and *in vivo* investigations of the wound healing effect of crude *Arthrospira* extract and C-phycoerythrin. *J. Med. Plants Res.*, 7:425-33, 2013.
- Hegazy, A.; Abd Al Hameed, E. A.; El-Wafaey, D. & Khorshed, O. Effect of paracetamol administration on the rat kidney structure: a morphological study. *Zagazig Univ. Med. J.*, 27(4):567-76, 2021.
- Holownia A. & Braszko, J. J. Acetaminophen alters microsomal ryanodine Ca²⁺ channel in HepG2 cells overexpressing CYP2E1. *Biochem. Pharmacol.*, 68(3):513-21, 2004.
- Iweala, E. E. J.; Obichi, I. C. & Omotosho, O. E. Biochemical and histological responses of Hepatotoxic rats fed *Musa paradisiaca* L. supplemented diet. *Int. J. Pharmacol.*, 7(4):471-7, 2011.
- James, L. P.; McCullough, S. S.; Lamps, L. W. & Hinson, J. A. Effect of N-acetylcysteine on acetaminophen toxicity in mice: relationship to reactive nitrogen and cytokine formation. *Toxicol. Sci.*, 75(2):458-67, 2003.
- Kanchana, N. & Sadiq, A. M. Hepatoprotective effect of *Plumbago zeylanica* on acetaminophen-induced liver damage in rats. *Int. J. Pharm. Pharm. Sci.*, 3(1):151-4, 2011.
- Karadeniz, A.; Yildirim, A.; Simsek, N.; Kalkan, Y. & Celebi, F. *Spirulina platensis* protects against gentamicin-induced nephrotoxicity in rats. *Phytother. Res.*, 22(11):1506-10, 2008.
- Khan, Z.; Bhadouria, P. & Bisen, P. S. Nutritional and therapeutic potential of *Spirulina*. *Curr. Pharm. Biotechnol.*, 6(5):373-9, 2005.
- Larsen, K. Creatinine assay in the presence of protein with LKB 8600 Reaction Rate Analyser. *Clin. Chim. Acta*, 38(2):475-6, 1972.
- Larson, A. M.; Polson, J.; Fontana, R. J.; Davern, T. J.; Lalani, E.; Hynan, L. S.; Reisch, J. S.; Schiødt, F. V.; Ostapowicz, G.; Shakil, A. O.; et al. Acetaminophen-induced acute liver failure: results of a United States multicenter, prospective study. *Hepatology*, 42(6):1364-72, 2005.
- Lowry, O. H.; Rosebrough, N. J.; Farr, A. L. & Randall, R. J. Protein measurement with the Folin phenol reagent. *J. Biol. Chem.*, 193(1):265-75, 1951.
- Michael, S. L.; Pumford, N. R.; Mayeux, P. R.; Niesman, M. R. & Hinson, J. A. Pretreatment of mice with macrophage inactivators decreases acetaminophen hepatotoxicity and the formation of reactive oxygen and nitrogen species. *Hepatology*, 30(1):186-95, 2001.
- Mihara, M. & Uchiyama, M. Determination of malonaldehyde precursor in tissues by thiobarbituric acid test. *Anal. Biochem.*, 86(1):271-8, 1978.
- Moawad, K. M. Possible prophylactic effects of vitamin E. or lichen treatment on renal
- Molander, D. W.; Wroblewski, F. & La Due, J. S. Transaminase compared with cholinesterase and alkaline phosphatase an index of hepatocellular integrity. *Clin. Res. Proc.*, 3:20-4, 1955.
- Murugan, T. & Radhamadhavan, L. Screening for Anti-fungal and Antiviral activity of C-phycoerythrin from *Arthrospira platensis*. *J. Pharm. Res.*, 4(11):4161-3, 2011.
- Nashwa, A. & Abu-Aita. Hepatoprotective effect of *Arthrospira platensis* against aluminum chloride induced liver damage in rats. *Glob. Vet.*, 13:552-9, 2014.
- Nishikimi, M.; Appaji, N. & Yagi, K. The occurrence of superoxide anion in the reaction of reduced phenazine methosulfate and molecular oxygen. *Biochem. Biophys. Res. Commun.*, 46(2):849-54, 1972.
- Reitman, S. & Frankel, S. A colorimetric method for the determination of serum glutamic oxalacetic and glutamic pyruvic transaminases. *Am. J. Clin. Pathol.*, 28(1):56-63, 1957.
- Rizk, M. Z.; Aly, H. F.; Abo-Elmatty, D. M.; Desoky, M. M.; Ibrahim, N. & Younis, E. A. Hepatoprotective effect of *Caesalpinia gilliesii* and *Cajanus cajan* proteins against acetaminophen overdose-induced hepatic damage. *Toxicol. Ind. Health*, 32(5):877-907, 2016.
- Sabina, E. P.; Samuel, J.; RajappaRamy, S.; Patel, S.; Mandal, N.; Pranatharthiharan, P.; Mishra, P. P. & Rasool, M. Hepatoprotective and antioxidant potential of *Arthrospira fusiformis* on acetaminophen-induced hepatotoxicity in rat. *Int. J. Integr. Biol.*, 6(1):1-5, 2009.
- Sabira, S. M. & Rocha, J. B. T. Antioxidant and hepatoprotective activity of aqueous extract of *Solanum fastigiatum* (false "Jurubeba") against paracetamol-induced liver damage in mice. *J. Ethnopharmacol.*, 120(2):226-32, 2008.
- Schmidt, M. & Eisenburg, J. Serum bilirubin determination in newborn infants. A new micromethod for the determination of serum of plasma bilirubin in newborn infants. *Fortschr. Med.*, 93(30):1461-6, 1975.
- Sharoud, M. N. M. Protective effect of *Spirulina* against paracetamol-induced hepatic injury in rats. *J. Exp. Biol. Agric. Sci.*, 3(1):44-53, 2015.
- Sinclair, A. J.; Barnett, A. H. & Lunec, J. Free radicals and antioxidant systems in health and disease. *Br. J. Hosp. Med.*, 43(5):334-44, 1991.
- Soliman, H. A. E.; Ahmed, R. R. & Ali, A. T. Assessment of the chemopreventive effects of various plant constituents against doxorubicin-induced toxicity in rats. *J. Am. Sci.*, 10(9):153-64, 2014.
- Tietz, N. W.; Burtis, C. A.; Duncan, P.; Ervin, K.; Petitclerc, C. J.; Rinker, A. D.; Shuey, D. & Zygowicz, E. R. A reference method for measurement of alkaline phosphatase activity in human serum. *Clin. Chem.*, 29(5):751-61, 1983.
- toxicity induced by CCl₄ administration in Albino rats. *World J. Zool.*, 2(2):19-28, 2007.
- Trushina, E. N.; Gladkikh, O. I.; Gadzhieva, Z. M.; Mustafina, O. K. & Pozdniakov, A. L. The influence of *Spirulina* and Selen-*Spirulina* on some indexes of rat's immune status. *Vopr. Pitan.*, 76(2):21-5, 2007.
- Vadiraja, B. B.; Gaikwad, N. W. & Madyastha, K. M. Hepatoprotective effect of C-phycoerythrin: protection for carbon tetrachloride and R-(+)-pulegone-mediated hepatotoxicity in rats. *Biochem. Biophys. Res. Commun.*, 249(2):428-31, 1998.
- Yadav, N. P. & Dixit, V. K. Hepatoprotective activity of leaves of *Kalanchoe pinnata* Pers. *Pers. J. Ethnopharmacol.*, 86(2-3):197-202, 2003.
- Ye, H.; Nelson, L. J.; Gómez Del Moral, M.; Martínez-Naves, E. & Cubero, F. J. Dissecting the molecular pathophysiology of drug-induced liver injury. *World J. Gastroenterol.*, 24(13):1373-85, 2018.
- Zhang, W.; Yu, J.; Dong, Q. Zhao, H.; Li, F. & Li, H. A mutually beneficial relationship between hepatocytes and cardiomyocytes mitigates doxorubicin-induced toxicity. *Toxicol. Lett.*, 227(3):157-63, 2014.

Corresponding author:

Abdel-Aziz A

Botany and Microbiology Department

Faculty of Science

Zagazig University

Zagazig 44519

EGYPT

Email: abdelaziz.a.elsayed@gmail.com

aaelsayed@iu.edu.sa