

Preliminary Study on Application of Combined Monitoring of Neuroelectrophysiology-Intracranial Pressure-Cerebral Perfusion Pressure in Craniotomy for Intracranial Aneurysm Clipping: An Anatomical and Clinical Study

Estudio Preliminar sobre la Aplicación de la Monitorización Combinada de Neuroelectrofisiología- Presión Intracraneal-Presión de Perfusión Cerebral en Craneotomía para Clipaje de Aneurisma Intracraneal: Un Estudio Anatómico y Clínico

Qiang Li; Yuhao He; Chunmiao Wu; Shengming Liu & Sunfu Zhang

LI, Q.; HE, Y.; WU, C.; LIU, S. & ZHANG, S. Preliminary study on application of combined monitoring of neuroelectrophysiology-intracranial pressure-cerebral perfusion pressure in craniotomy for intracranial aneurysm clipping: An anatomical and clinical study. *Int. J. Morphol.*, 42(1):348-355, 2024.

SUMMARY: Intracranial aneurysm is a common cerebrovascular disease with high mortality. Neurosurgical clipping for the treatment of intracranial aneurysms can easily lead to serious postoperative complications. Studies have shown that intraoperative monitoring of the degree of cerebral ischemia is extremely important to ensure the safety of operation and improve the prognosis of patients. Aim of this study was to probe the application value of combined monitoring of intraoperative neurophysiological monitoring (IONM)-intracranial pressure (ICP)-cerebral perfusion pressure (CPP) in craniotomy clipping of intracranial aneurysms. From January 2020 to December 2022, 126 patients in our hospital with intracranial aneurysms who underwent neurosurgical clipping were randomly divided into two groups. One group received IONM monitoring during neurosurgical clipping (control group, n=63), and the other group received IONM-ICP-CPP monitoring during neurosurgical clipping (monitoring group, n=63). The aneurysm clipping and new neurological deficits at 1 day after operation were compared between the two groups. Glasgow coma scale (GCS) score and national institutes of health stroke scale (NIHSS) score were compared before operation, at 1 day and 3 months after operation. Glasgow outcome scale (GOS) and modified Rankin scale (mRS) were compared at 3 months after operation. All aneurysms were clipped completely. Rate of new neurological deficit at 1 day after operation in monitoring group was 3.17 % (2/63), which was markedly lower than that in control group of 11.11 % (7/30) ($P<0.05$). At 1 day after operation, in monitoring group, GCS score was remarkably higher while NIHSS score was lower than that of control ($P<0.05$). At 3 months of postoperative follow-up, 5 cases were lost to follow-up in control group and 4 cases were lost in monitoring group. Excellent and good rate of GOS grading in control group was 89.65 % (52/58), and 93.22 % (55/58) in monitoring group. In addition, the excellent and good rate of mRS grading in control group was 91.38 % (53/58), and 94.92 % (56/58) in monitoring group, there was no remarkable difference in the excellent and good rate of GOS and mRS grading between the two groups at 3 months after operation ($P>0.05$). Combined monitoring of IONM-ICP-CPP can monitor the cerebral blood flow of patients in real time during neurosurgical clipping, according to the monitoring results, timely intervention measures can improve the consciousness state of patients in early postoperative period and reduce the occurrence of early postoperative neurological deficits.

KEY WORDS: Neuroelectrophysiology; Intracranial pressure; Cerebral perfusion pressure; Neurosurgical clipping.

INTRODUCTION

Intracranial aneurysm, an abnormal bulge of an intracranial artery, is a common cerebrovascular disease with high mortality (Fig. 1) (Sharma *et al.*, 2020; Rahmani *et al.*, 2022). The surgical methods of intracranial aneurysms mainly include neurosurgical clipping and interventional embolization, both of which have the risk of ischemic

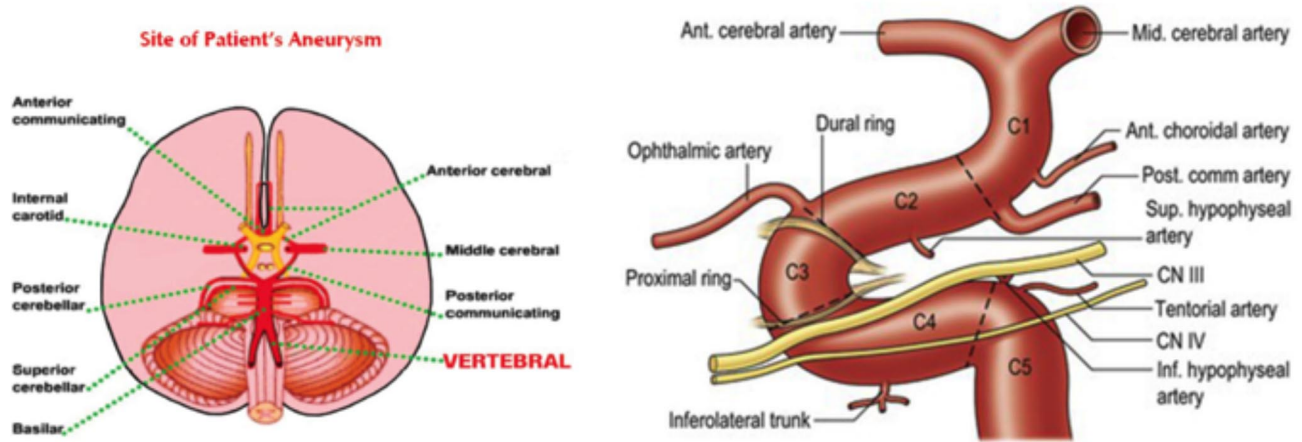
complications (Jiang *et al.*, 2020; Lee *et al.*, 2022). In neurosurgical clipping, temporary occlusion of the parent artery, misclamping of important blood vessels, vasospasm, stenosis, thrombosis, excessive traction of brain tissue and injury of small perforating arteries usually result in intraoperative cerebral ischemia or severe brain tissue injury,

Department of Neurosurgery, The Third People's Hospital of Chengdu Chengdu, Sichuan 610000.

FUNDING. This study was supported by the Sichuan Provincial Department of Science and Technology ,code 2023NSFSC0677

Received: 2023-10-16 Accepted: 2023-11-14

Anatomical representation of intracranial aneurysms



Circulus arteriosus cerebri (Willis)

View of C1-C5 segments of internal carotid artery

Fig. 1. Schematic view of intracranial aneurysms of the brain base.

which leads to severe neurological dysfunction and even death after operation (Meling & Lavé, 2019; Xu *et al.*, 2020a). How to take effective measures to reduce the occurrence of complications has always been a difficult problem faced by neurosurgeons. Intraoperative neurophysiological monitoring (IONM) can reflect the function of cerebral cortex and nerve conduction in functional areas, the range of warning values can be used to judge whether there is ischemia and remind the surgeon to make timely adjustments to ensure the safety of operation. However, the monitoring results are mostly prediction, without specific quantitative values, so the degree of cerebral ischemia cannot be accurately determined (Xiao *et al.*, 2020; Lv *et al.*, 2020). Studies have shown that the changes of intracranial pressure (ICP) and cerebral perfusion pressure (CPP) are related to patient's condition, increase of ICP leads to the decrease of cerebral blood flow and CPP, thus brain tissue was accelerated damaged during operation (Schizodimos *et al.*, 2020; Hawryluk *et al.*, 2022). At present, few studies have investigated the role of combined monitoring

of IONM-ICP-CPP in neurosurgical clipping. Therefore, in this study, IONM-ICP-CPP monitoring was used in neurosurgical clipping, timely intervention measures were taken according to the monitoring results, which is to explore its effect on improving the consciousness state of patients in the early postoperative period and reducing the early postoperative neurological deficit, so as to provide reference for clinical implementation of neurosurgical clipping. The report as follows.

MATERIAL AND METHOD

General information. From January 2020 to December 2022, a total of 126 patients in our hospital with intracranial aneurysms, who underwent neurosurgical clipping were selected, were randomly divided into control and monitoring group (n=63/each). Hunt-Hess grading criteria were shown in Table I. There was no prominent difference between the two groups ($P < 0.05$) (Table II), which was comparable.

Table I. Hunt-Hess grading.

Grade	Symptom
I	There were no obvious symptoms or mild headache and mild nuchal rigidity
II	Moderate/severe headache, neck rigidity or cranial nerve palsy
III	Drowsiness, confusion, and mild focal neurologic deficits were noted
IV	Moderate/severe hemiparesis, early decerebellar rigidity and autonomic nervous system dysfunction
V	Moderate/severe hemiparesis, early desencephalic rigidity and autonomic nervous system dysfunction, agonal state

Table II. General data of the two groups.

Group	Control Group (N=63)	Monitoring Group (N=63)	X ² /T Value	P value	
Male/Female (cases)	28/35	30/33	0.128	0.721	
Mean age (years)	56.87±7.32	57.26±7.43	0.297	0.767	
Mean aneurysm size (cm)	1.50±2.60	1.40±2.70	0.212	0.833	
Hunt-Hess grading	I	12 (19.05)	0.050	0.823	
	II	21 (33.33)	0.311	0.577	
	III	23 (36.51)	0.318	0.573	
	IV	6 (9.52)	7 (11.11)	0.086	0.770
Single aneurysm	Internal carotid artery aneurysm	7 (11.11)	0.076	0.783	
	Anterior cerebral aneurysm	5 (7.94)	6 (9.52)	0.099	0.752
	Anterior communicating aneurysms	14 (22.22)	12 (19.05)	0.194	0.660
	Middle cerebral aneurysm	17 (26.98)	18 (28.57)	0.040	0.842
	Posterior communicating aneurysms	11 (17.46)	13 (20.63)	0.206	0.650
	Vertebrobasilar aneurysms	2 (3.17)	3 (4.76)	0.208	0.648
	Others	1 (1.59)	0 (0.00)	1.008	0.315
Multiple aneurysms	5 (7.94)	4 (6.35)	0.120	0.729	
Aneurysm rupture and hemorrhage	27 (42.86)	29 (46.03)	0.129	0.720	
Unruptured aneurysm	36 (57.14)	34 (53.97)	0.129	0.720	

Inclusion and exclusion criteria. Inclusion criteria: (1) Diagnosed as intracranial aneurysm (Yoshimoto *et al.*, 1978); (2) Meet the indications of craniotomy; (3) Preoperative Hunt-Hess grading was I~IV; (4) Multiple aneurysms were clipped at one time; (5) Informed consent was obtained; (6) Age of 18~80 years old; (7) Tolerance to operation; (8) No other underlying diseases.

Exclusion criteria: (1) Subarachnoid hemorrhage; (2) Complicated with obstructive hydrocephalus and cerebral hernia; (3) Electrode placement failure and stimulator malfunction; (4) With intracranial metallic implants and a history of seizures; (5) With pacemaker, severe craniocerebral injury; (6) History of cerebrovascular disease and skull defect; (7) Endovascular intervention; (8) Previous history of lumbar operation and lumbar fracture.

Surgical methods. Pterional craniotomy and extended pterional craniotomy were adopted, and aneurysm clips were used to clip the aneurysm. Control group was treated with aneurysm clipping combined with IONM monitoring, and monitoring group was treated with aneurysm clipping combined with IONM-ICP-CPP monitoring. According to the monitoring results, once abnormal indicators were found during the operation, targeted measures were taken immediately to promote the indicators return to normal.

Monitoring methods

IONM. After anesthesia was completed, the same neuroelectrophysiological monitoring doctor installed the probe electrodes on the limbs and scalp, connected the monitors and set the parameters. The probes were located in accordance with the requirements of motor evoked potential

(MEP) and somatosensory evoked potential (SEP) monitoring. The probes were firmly fixed and avoided the surgical incision. A Cadwell Cascade 32 electrodes intraoperative evoked potential monitoring system was used, according to the international EEG 10/20 standard, the electrodes were placed, and the parameters were set. SEP, MEP, scalp electroencephalogram (EEG) and brainstem auditory evoked potential (BAEP) were monitored according to the location of aneurysm and the related blood supply area, the baseline of various monitoring waveforms was set after the guiding catheter was placed, and the changes of various indicators during the operation were observed. SEP warning criteria (Seidel *et al.*, 2021): early warning is carried out according to the internationally recognized "50/10" standard, and the early warning standard is a decrease in amplitude by more than 50 % or an increase in latency by more than 10 %. MEP warning criteria (Asimakidou *et al.*, 2021): when the amplitude of compound muscle action potential decreased by 20 %~30 %, neuroelectrophysiological monitoring physicians should be alert, when the amplitude decreased by more than 50 % or the latency prolonged by more than 10 %, the alarm should be immediately raised. BAEP warning criterion (Sprengers *et al.*, 2022): mainly recorded ?, ?, ? waves and interpeak latency. A latency of 1.5 ms greater than baseline or a change in amplitude of more than 50 % was considered an alarm. EEG warning criterion (Al-Salman *et al.*, 2022): a 50 % reduction in overall EEG amplitude and/or a 50 % reduction in ab wave activity.

ICP monitoring. The ICP detector probe was placed in the brain parenchyma of all patients, and the detector was zero set and adjusted before implantation. After careful

observation, the ICP value was recorded. $ICP \leq 15$ mmHg was defined as normal range, $15 < ICP \leq 20$ mmHg as mild increase, $20 < ICP \leq 40$ mmHg as moderate increase and $ICP > 40$ mmHg as severe increase.

CPP monitoring. Blood pressure was monitored with an electrocardiogram monitor (HP, HPM-1205A, USA), $CPP = \text{mean arterial pressure (MAP)} - ICP$, $MAP = \text{diastolic blood pressure} + 1/3 (\text{systolic blood pressure} - \text{diastolic blood pressure})$.

Indicators of observation. Aneurysm clipping and new neurological deficits at 1 day after operation were compared between the two groups. That is, cerebral artery CT angiography was performed at 1 week after operation to evaluate the aneurysm clipping. At 1 day after operation, as long as the patient's language function and consciousness level decreased, and any limb sensation as well as muscle strength were lower than those before operation, new neurological deficits were considered.

The Glasgow coma scale (GCS) and national institutes of health stroke scale (NIHSS) were compared before operation, 1 day and 3 months after operation. The highest GCS score was 15 points, the higher the score, the better the state of consciousness. The highest NIHSS score was 42 points, the higher the score, the more severe the neurological deficit.

The Glasgow outcome scale (GOS) and modified Rankin scale (mRS) were compared between the two groups at 3 months after operation, and the postoperative recovery and limb function were evaluated. According to the GOS grading, grade 5 was rated as excellent, grade 4 as good and grade 1~3 as poor. According to the mRS grading, grade 0~1 was excellent, grade 2~3 was good, grade 4~6 was poor, the excellent and good rate = $(\text{excellent} + \text{good}) / \text{total cases} \times 100\%$.

Statistical analysis. SPSS 25.0 software was used for data processing. Normal distribution measurement data were expressed as $\bar{x} \pm s$, t test was used for comparison, count data were expressed as $n(\%)$, χ^2 test was used, $P < 0.05$ was considered statistically significant.

Ethical Approval. It was approved by the Ethics Committee of the Third People's Hospital of Chengdu. Approval number: 2023-S-30.

RESULTS

Comparison of aneurysm clipping and new neurological deficits on the 1 day after operation between the two groups. Complete aneurysm clipping was achieved in

both groups. There were 7 cases of new neurological deficits in control group and 2 cases in monitoring group at 1 day after operation, the rate of new neurological deficits in monitoring group was 3.17 % (2/63), which was markedly lower than 11.11 % (7/63) in control group ($P < 0.05$). In monitoring group, intraoperative monitoring indicators changed in 11 cases, and ischemic potential changes of SEP occurred in 4 cases, which recovered to the baseline level before the end of operation, and no neurological dysfunction occurred after operation. Ischemic potential changes of MEP occurred in 6 cases, 2 cases recovered to the baseline level before the end of operation, while 4 cases did not recover to the baseline level, and 2 cases had mild neurological dysfunction after operation. Potential changes of EEG occurred in 1 patient, which did not return to the baseline level before the end of operation, and no neurological dysfunction occurred after operation (Table III).

The GCS and NIHSS score were compared between the two groups. At the follow-up of 3 months after operation, 5 cases in control group and 4 cases in monitoring group were lost to follow-up. The postoperative GCS score of the two groups were markedly higher than those before operation, while the NIHSS score were markedly lower than those before operation ($P < 0.05$). No remarkable difference in GCS and NIHSS score before and 3 months after operation between the two groups ($P > 0.05$). In monitoring group, GCS score was higher while NIHSS score was lower than that of control group at 1 day after operation ($P < 0.05$) (Table IV).

The excellent and good rate of GOS grading was compared between the two groups. The GOS grading of control group was "excellent" in 25 cases, "good" in 27 cases, and "poor" in 6 cases, with excellent and good rate of GOS grading was 89.65 % (52/58). In monitoring group, the GOS grading was "excellent" in 28 cases, "good" in 27 cases, and "poor" in 4 cases, with excellent and good rate of GOS grading was 93.22 % (55/58). There was no prominent difference in the excellent and good rate of GOS grading between the two groups at 3 months after operation ($P > 0.05$) (Table V).

The excellent and good rate of mRS grading was compared between the two groups. In control group, the mRS grading was "excellent" in 26 cases, "good" in 27 cases, and "poor" in 5 cases, with excellent and good rate of mRS grading was 91.38 % (53/58). The mRS grading of monitoring group was "excellent" in 28 cases, "good" in 28 cases, and "poor" in 3 cases, with excellent and good rate of mRS grading was 94.92 % (56/58). There was no prominent difference in the excellent and good rate of mRS grading between the two groups at 3 months after operation ($P > 0.05$) (Table VI).

Table III. Abnormal changes of neuroelectrophysiological signals in monitoring group.

Case	Aneurysm location	Operation	Intraoperative monitoring indicators				Intraoperative interventions	Neurological dysfunction occurred 1 day after operation
			SEP	MEP	EEG	BAEP		
1	Middle cerebral aneurysm	The parent artery was blocked	Amplitude disappeared, fully recovered	—	—	/	Remove the temporary clamp	No
2	Middle cerebral aneurysm	Small perforator artery injury	—	Amplitude disappeared, did not fully recovered	—	/	Stop the separation	Yes
3	Middle cerebral aneurysm	Excessive stretching of brain tissue	Amplitude disappeared, fully recovered	—	—	/	Reduce brain stretch	No
4	Posterior communicating aneurysms	The parent artery was blocked	—	Amplitude disappeared, did not fully recovered	—	/	Remove the temporary clamp	Yes
5	Aneurysms of ophthalmic artery segment	Small perforator artery injury	Amplitude disappeared, fully recovered	—	—	/	Stop the separation	No
6	Posterior communicating aneurysms	The parent artery was blocked	Amplitude disappeared, fully recovered	—	—	/	Remove the temporary clamp	No
7	Middle cerebral aneurysm	Excessive stretching of brain tissue	—	Amplitude disappeared, fully recovered	—	/	Reduce brain stretch	No
8	Aneurysms of ophthalmic artery segment	Small perforator artery injury	—	—	Waveform disappeared, did not recovered	/	Stop the separation	No
9	Middle cerebral aneurysm	Vasospasm	—	Amplitude disappeared, fully recovered	—	/	Wet compress with papaverine	No
10	Aneurysms of ophthalmic artery segment	Vasospasm	—	Amplitude disappeared, did not fully recovered	—	/	Wet compress with papaverine	No
11	Posterior communicating aneurysms	Small perforator artery injury	—	Amplitude disappeared, did not fully recovered	—	/	Stop the separation	No

"—" means that no positive changes were detected, and "/" means that no monitoring was performed. These 11 patients were all anterior circulation aneurysms, so BAEP monitoring was not performed.

Table IV. Comparison of GCS and NIHSS score between the two groups (Score, $\bar{x} \pm s$).

Group	GCS score			NIHSS score		
	Before operation	1 day after operation	3 months after operation	Before operation	1 day after operation	3 months after operation
Control group (n=58)	8.27±0.73	9.25±1.02 [#]	13.29±0.51 [#]	7.79±1.28	6.32±0.77 [#]	3.21±0.54 [#]
Monitoring group (n=59)	8.31±0.66	10.14±0.83 [#]	13.22±0.63 [#]	7.75±1.36	5.37±0.62 [#]	3.38±0.64 [#]
t value	0.323	5.372	0.660	0.170	7.627	1.551
P value	0.747	<0.001	0.511	0.865	<0.001	0.123

Note: When the GCS and NIHSS score at 3 months after operation were statistically analyzed, there were 58 patients in control group and 59 patients in monitoring group. Compared with the same group before operation, [#]P<0.05.

Table V. Comparison of excellent and good rate of GOS grading between the two groups [n(%)].

Group	GOS grading			
	Excellent	Good	Bad	Excellent and good rate
Control group (n=58)	25 (43.10)	27 (46.55)	6 (10.34)	52 (89.65)
Monitoring group (n=59)	28 (47.46)	27 (45.76)	4 (6.78)	55 (93.22)
χ^2 value				0.476
P value				0.490

Table VI. Comparison of excellent and good rate of mRS grading between the two groups [n(%)].

Group	mRS grading			
	Excellent	Good	Bad	Excellent and good rate
Control group (n=58)	26 (44.83)	27 (46.55)	5 (8.62)	53 (91.38)
Monitoring group	26 (44.83)	27 (46.55)	5 (8.62)	56 (94.92)
χ^2 value				0.574
P value				0.449

DISCUSSION

With the development of bad living habits of people, the incidence of intracranial aneurysms is increasing, which seriously threatens human physical and mental health (Ward Fuller *et al.*, 2017; Chalos *et al.*, 2020; Cook, 2021; Haggag & Hodgson, 2022; Hr *et al.*, 2022). The clinical treatment of this disease is mostly surgical treatment, such as craniotomy, and various adverse reactions will occur during the treatment process, including hypotension and vascular rupture, etc (Chen *et al.*, 2019). How to improve the success rate of operation is an urgent problem to be solved. Studies have shown that the changes of hemodynamic and neuroelectrophysiological indexes during craniotomy for clipping intracranial aneurysms are closely related to the changes of postoperative neurological function. It is extremely important to monitor the abnormal conditions of each index during operation and give targeted interventions to improve the prognosis (Kang *et al.*, 2020; Xu *et al.*, 2020b). At present, IONM technology has become an important monitoring method in neuro-operation, which can not only monitor cerebral blood flow in real time accurately, but also determine the collateral compensation ability of cerebral vessels, greatly improving the safety of operation. However, IONM is easily affected by the patient's position, blood pressure, body temperature, anesthesia, and other factors, leading to false positive results (Yuan *et al.*, 2022). In recent years, ICP monitoring has achieved good results in the application of cerebrovascular disease and brain tumor operation. Studies have shown that ventricular drainage combined with ICP monitoring can reduce cerebral vasospasm and hydrocephalus after ruptured aneurysm operation and reduce the incidence of adverse reactions (Konovalov *et al.*, 2021; Addis *et al.*, 2023). In addition, stable hemodynamic parameters are also the key to ensure the success of craniotomy. Studies have found that anesthesia can cause sympathoadrenal axis response in patients with brain tumors, resulting in increased ICP and decreased CPP. The instability of ICP and CPP can affect the safety of operation and increase the risk of surgical failure. Fluctuations in hemodynamic parameters can also adversely affect the patient's recovery (Mierzwa *et al.*, 1999). Therefore, simultaneous monitoring of ICP and CPP by IONM can detect abnormalities in time, in the case of ineffective adjustment of surgical procedures, drugs, release of cerebrospinal fluid, elevation of the head of the bed or anesthesia techniques can be used to regulate hemodynamic indexes, improve cerebral ischemia, and provide further guarantee for the safety and efficacy of intracranial aneurysm operation.

The results of this study showed that the aneurysms of both groups were completely clipped. The rate of new

neurological deficit in monitoring group was markedly lower than that in control at 1 day after operation, indicating that combined monitoring of IONM-ICP-CPP can reduce the occurrence of early neurological deficit after intracranial aneurysm clipping. SEP, MEP and EEG monitoring are important to predict whether patients will have new neurological dysfunction after the operation, which can effectively reflect the blood perfusion of brain tissue and avoid permanent neurological deficit (Horvath *et al.*, 2015). During aneurysm operation, dynamic monitoring of ICP and CPP changes can evaluate the vascular occlusion time, provide the operator with the time limit information of temporary vascular occlusion, which play an important role in early warning of postoperative cerebral infarction (Doron *et al.*, 2022). In this study, NIHSS score of monitoring group was lower while GCS score was higher than that of control group on the 1 day after operation, indicating that IONM combined with monitoring of ICP and CPP improved the early postoperative consciousness state of patients. IONM can reflect the damage of nerve function during the operation in real time. When the operator is performing the operation, different reactions of the patient such as traction, ischemia, and thermal coagulation, can cause the corresponding changes of the potential map, remind the operator to stop the operation and adjust the surgical strategy in time, so that the patient's nerve function can return to normal or basically normal, and facilitate the recovery of early consciousness (Harper & Nelson, 1992; Strommen *et al.*, 2022). In addition, ICP monitoring can also reflect real-time brain edema and help to guide the use of dehydrating drugs, simultaneous monitoring of CPP can determine the cerebral blood flow of patients, avoid the blind use of mannitol, and reduce the risk of electrolyte disturbances (Kirkman & Smith, 2014; Hawryluk *et al.*, 2022).

Although intraoperative combined detection of IONM-ICP-CPP was beneficial to improve the early postoperative neurological function, while the follow-up results showed that there was no remarkable difference in the excellent and good rate of GOS and mRS grading between the two groups at 3 months after operation. The reason was considered that after discharge, the individual differences of patients were large, and there were many interference factors, like patient's active exercise routine, medication compliance and complications had great influence on the results.

At the same time, this study also has some limitations, the sample size of this study was small. In order to reduce the loss rate of follow-up, at least 3 family members' phone calls were left after the patients were admitted to the hospital, and the specific conditions of the patients may be biased through the family members, there were still cases lost when

follow-up at 3-month after operation, which may cause bias in the research data. Therefore, it is necessary to increase the number of cases in subsequent studies and improve the methods of follow-up. Besides, the intraoperative electrophysiological monitoring results of some cases were normal, but ICP and CPP changed, whether the changes was caused by fluctuation of circulatory blood pressure or anesthesia intervention was still uncertain. Also, to what extent can the electrophysiological monitoring indicators be reduced to cause abnormal changes in ICP and CPP, and the causes of postoperative new neurological deficits need further explore.

CONCLUSIONS

In conclusion, combined monitoring of IONM-ICP-CPP during intracranial aneurysm clipping and timely intervention measures was taken in time according to the monitoring results are of great significance for improving the consciousness state of patients at early time after operation and reducing the occurrence of early neurological deficits, which is worthy of clinical application.

LI, Q.; HE, Y.; WU, C.; LIU, S. & ZHANG, S. Estudio preliminar sobre la aplicación de la monitorización combinada de neuroelectrofisiología-presión intracraneal-presión de perfusión cerebral en craneotomía para clipaje de aneurisma intracraneal: un estudio anatómico y clínico. *Int. J. Morphol.*, 42(1):348-355, 2024.

RESUMEN: El aneurisma intracraneal es una enfermedad cerebrovascular común con alta mortalidad. El clipaje neuroquirúrgico para el tratamiento de aneurismas intracraneales puede provocar complicaciones posoperatorias graves. Los estudios han demostrado que la monitorización intraoperatoria del grado de isquemia cerebral es extremadamente importante para garantizar la seguridad de la operación y mejorar el pronóstico de los pacientes. El objetivo de este estudio fue probar el valor de la aplicación de la monitorización combinada de la monitorización neurofisiológica intraoperatoria (IONM), la presión intracraneal (PIC) y la presión de perfusión cerebral (CPP) en el clipaje de craneotomía de aneurismas intracraneales. Desde enero de 2020 hasta diciembre de 2022, 126 pacientes de nuestro hospital con aneurismas intracraneales que se sometieron a clipaje neuroquirúrgico se dividieron aleatoriamente en dos grupos. Un grupo recibió monitorización IONM durante el clipaje neuroquirúrgico (grupo de control, n=63) y el otro grupo recibió monitorización IONM-ICP-CPP durante el clipaje neuroquirúrgico (grupo de monitorización, n=63). Se compararon entre los dos grupos el recorte del aneurisma y los nuevos déficits neurológicos un día después de la operación. La puntuación de la escala de coma de Glasgow (GCS) y la puntuación de la escala de accidentes cerebrovasculares de los institutos nacionales de salud (NIHSS) se compararon antes de la operación, 1 día y 3 meses después de la operación. La escala de resultados de Glasgow (GOS) y la escala

de Rankin modificada (mRS) se compararon 3 meses después de la operación. Todos los aneurismas fueron cortados por completo. La tasa de nuevo déficit neurológico 1 día después de la operación en el grupo de seguimiento fue del 3,17 % (2/63), que fue notablemente inferior a la del grupo de control del 11,11 % (7/30) ($P < 0,05$). Un día después de la operación, en el grupo de seguimiento, la puntuación GCS fue notablemente más alta, mientras que la puntuación NIHSS fue más baja que la del control ($P < 0,05$). A los 3 meses de seguimiento posoperatorio, se perdieron 5 casos del grupo de control y 4 casos del grupo de seguimiento. La tasa excelente y buena de calificación de GOS en el grupo de control fue del 89,65 % (52/58) y del 93,22 % (55/58) en el grupo de seguimiento. Además, la tasa excelente y buena de calificación de mRS en el grupo control fue del 91,38 % (53/58) y del 94,92 % (56/58) en el grupo de seguimiento, no hubo diferencias notables en la tasa excelente y buena de GOS y mRS en la clasificación entre los dos grupos a los 3 meses después de la operación ($P > 0,05$). La monitorización combinada de IONM-ICP-CPP puede controlar el flujo sanguíneo cerebral de los pacientes en tiempo real durante el corte neuroquirúrgico; de acuerdo con los resultados de la monitorización, las medidas de intervención oportunas pueden mejorar el estado de conciencia de los pacientes en el período postoperatorio temprano y reducir la aparición de problemas postoperatorios tempranos y déficits neurológicos.

PALABRAS CLAVE: Neuroelectrofisiología; Presión intracraneal; Presión de perfusión cerebral; Clipping neuroquirúrgico.

REFERENCES

- Addis, A.; Baggiani, M. & Citerio, G. Intracranial pressure monitoring and management in aneurysmal subarachnoid hemorrhage. *Neurocrit. Care*, 39(1):59-69, 2023.
- Al-Salman, W.; Li, Y.; Wen, P.; Miften, F.; Oudah, A. Y. & Ghayab, H. R. A. Extracting epileptic features in EEGs using a dual-tree complex wavelet transform coupled with a classification algorithm. *Brain Res.*, 1779:147777, 2022.
- Asimakidou, E.; Abut, P.A.; Raabe, A. & Seidel, K. Motor evoked potential warning criteria in supratentorial operation: a scoping review. *Cancers (Basel)*, 13(11):2803, 2021.
- Chalos, V.; van der Ende, N. A. M.; Lingsma, H. F.; Mulder, M. J. H. L.; Venema, E.; Dijkland, S. A.; Berkhemer, O. A.; Yoo, A. J.; Broderick, J. P.; Palesch, Y. Y.; et al. National Institutes of Health Stroke Scale: an alternative primary outcome measure for trials of acute treatment for ischemic stroke. *Stroke*, 51(1):282-290, 2020.
- Chen, N.; Li, R.; Dai, S.; Zhang, Y.; Huang, J.; Wang, E. & He, Z. Prognosis in patients underwent craniotomy for aneurysm clipping with cardiovascular diseases. *Zhong Nan Da Xue Xue Bao Yi Xue Ban*, 44(1):40-5, 2019.
- Cook, N. F. The Glasgow Coma Scale: A European and Global Perspective on Enhancing Practice. *Crit. Care Nurs. Clin. North Am.*, 33(1):89-99, 2021.
- Doron, O.; Silverstein, J. W.; Likowski, D.; Kohut, K. & Ellis, J. A. Temporary vessel occlusion in cerebral aneurysm operation guided by direct cortical motor evoked potentials. *Acta. Neurochir. (Wien)*, 164(5):1255-63, 2022.
- Haggag, H. & Hodgson, C. Clinimetrics: Modified Rankin Scale (mRS). *J. Physiother.*, 68(4):281, 2022.
- Harper, C. M. & Nelson, K. R. Intraoperative electrophysiological monitoring in children. *J. Clin. Neurophysiol.*, 9(3):342-56, 1992.

- Hawryluk, G. W. J.; Citerio, G.; Hutchinson, P.; Koliás, A.; Meyfroidt, G.; Robba, C.; Stocchetti, N. & Chesnut, R. Intracranial pressure: current perspectives on physiology and monitoring. *Intensive Care Med.*, 48(10):1471-81, 2022.
- Horvath, J. C.; Forte, J. D. & Carter, O. Evidence that transcranial direct current stimulation (tDCS) generates little-to-no reliable neurophysiologic effect beyond MEP amplitude modulation in healthy human subjects: A systematic review. *Neuropsychologia*, 66:213-36, 2015.
- Hr, D.; Praneeth, K.; Aggarwal, A.; Gupta, S. K. & Sachdeva, N. Seasonal variation and Incidence of rupture of intracranial aneurysm : A prospective study and Literature review. *Acta Neurol. Taiwan*, 31(3):137-45, 2022.
- Jiang, Z.; Chen, Y.; Zeng, C.; Feng, J.; Wan, Y. & Zhang, X. Neurosurgical clipping versus endovascular coiling for patients with intracranial aneurysms: a systematic review and meta-analysis. *World Neurosurg.*, 138:e191-e222, 2020.
- Kang, X. K.; Guo, S. F.; Lei, Y.; Wei, W.; Liu, H.; Huang, L. L. & Jiang, Q. L. Endovascular coiling versus surgical clipping for the treatment of unruptured cerebral aneurysms: Direct comparison of procedure-related complications. *Medicine (Baltimore)*, 99(13):e19654, 2020.
- Kirkman, M. A. & Smith, M. Intracranial pressure monitoring, cerebral perfusion pressure estimation, and ICP/ CPP-guided therapy: a standard of care or optional extra after brain injury? *Br. J. Anaesth.*, 112(1):35-46, 2014.
- Konovalov, A.; Shekhtman, O.; Pilipenko, Y.; Okishev, D.; Ershova, O.; Oshorov, A.; Abramyan, A.; Kurzakova, I. & Eliava, S. External ventricular drainage in patients with acute aneurysmal subarachnoid hemorrhage after microsurgical clipping: our 2006-2018 experience and a literature review. *Cureus*, 13(1):e12951, 2021.
- Lee, K. S.; Zhang, J. J. Y.; Nguyen, V.; Han, J.; Johnson, J. N.; Kirolos, R. & Teo, M. The evolution of intracranial aneurysm treatment techniques and future directions. *Neurosurg. Rev.*, 45(1):1-25, 2022.
- Lv, H.; Qu, Q.; Liu, H.; Qian, Q.; Zheng, X. & Zhang, Y. Clinical, neuroelectrophysiological and muscular pathological analysis of chronic progressive external ophthalmoplegia. *Exp. Ther. Med.*, 20(2):1770-4, 2020.
- Meling, T. R. & Lavé, A. What are the options for cardiac standstill during aneurysm operation? A systematic review. *Neurosurg. Rev.*, 42(4):843-52, 2019.
- Mierzwa, J.; Wron'ski, J.; Juniewicz, H. & Abraszko, R. Results of postoperative treatment of patients after brain tumor removal based on the cerebral circulatory pressure index (CCPI) in comparison with ICP and CPP. *Neurol. Neurochir. Pol.*, 33(5):1063-76, 1999.
- Rahmani, R.; Baranoski, J. F.; Albuquerque, F. C.; Lawton, M. T. & Hashimoto, T. Intracranial aneurysm calcification-A narrative review. *Exp. Neurol.*, 353:114052, 2022.
- Schizodimos, T.; Soulountsi, V.; Iasonidou, C. & Kapravelos, N. An overview of management of intracranial hypertension in the intensive care unit. *J. Anesth.*, 34(5):741-57, 2020.
- Seidel, K.; Jeschko, J.; Schucht, P.; Bervini, D.; Fung, C.; Krejci, V.; Z'Graggen, W.; Fischer, U.; Arnold, M.; Goldberg, J.; et al. Somatosensory evoked potential and transcranial doppler monitoring to guide shunting in carotid endarterectomy. *J. Neurol. Surg. A Cent. Eur. Neurosurg.*, 82(4):299-307, 2021.
- Sharma, T.; Datta, K. K.; Kumar, M.; Dey, G.; Khan, A. A.; Mangalaparathi, K. K.; Saharan, P.; Chinnapparaj, S.; Aggarwal, A.; Singla, N.; et al. Intracranial aneurysm biomarker candidates identified by a proteome-wide study. *OMICS*, 24(8):483-492, 2020.
- Sprengers, L.; Lemmens, R. & van Loon, J. Usefulness of intraoperative monitoring in microvascular decompression for hemifacial spasm: a systematic review and meta-analysis. *Br. J. Neurosurg.*, 36(3):346-57, 2022.
- Strommen, J. A.; Skinner, S. & Crum, B. A. Neurophysiology during peripheral nerve surgery. *Handb. Clin. Neurol.*, 186:295-318, 2022.
- Ward Fuller, G.; Hernandez, M.; Pallot, D.; Lecky, F.; Stevenson, M. & Gabbe, B. Health state preference weights for the glasgow outcome scale following traumatic brain injury: a systematic review and mapping study. *Value Health*, 20(1):141-51, 2017.
- Xiao, B.; Constatntini, S.; Browd, S.R.; Zhan, Q.; Jiang, W. & Mei, R. The role of intra-operative neuroelectrophysiological monitoring in single-level approach selective dorsal rhizotomy. *Childs Nerv. Syst.*, 36(9):1925-33, 2020.
- Xu, K.; Hou, K.; Xu, B.; Guo, Y. & Yu, J. Single-stage clipping of seven intracranial aneurysms in the anterior circulation via unilateral pterional approach: a case report and literature review. *J. Neurol. Surg. A Cent. Eur. Neurosurg.*, 81(3):271-8, 2020a.
- Xu, Y.; Tian, W.; Wei, Z.; Li, Y.; Gao, X.; Li, W. & Dong, B. Microcatheter shaping using three-dimensional printed models for intracranial aneurysm coiling. *J. Neurointerv. Surg.*, 12(3):308-10, 2020b.
- Yoshimoto, T.; Kayama, T.; Kodama, N. & Suzuki, J. Distribution of intracranial aneurysm. *Tohoku J. Exp. Med.*, 126(2):125-32, 1978.
- Yuan, Y. S.; Xu, H. L.; Liu, Z. D.; Kou, Y. H.; Jin, B. & Zhang, P. X. Brain functional remodeling caused by sciatic nerve transposition repair in rats identified by multiple-model resting-state blood oxygenation level-dependent functional magnetic resonance imaging analysis. *Neural Regen. Res.*, 17(2):418-26, 2022.

Corresponding author:
Sunfu Zhang
No.82, Qinglong Street
Qingyang District
Sichuan Province
Chengdu City
CHINA

E-mail:zhangsunfu3rd@outlook.com