

Multiple Anatomical Variations of the Hepatic Pedicle. Case Report and Clinical Application

Múltiples Variaciones Anatómicas del Pedículo Hepático. Reporte de Caso y Aplicación Clínica

Homero Felipe Bianchi*; Rubén Daniel Algieri*; Daniela Sanjurjo*; Nicolás Ernesto Ottone^{*,**,***} & Ramón Fuentes**

BIANCHI, H. F.; ALGIERI, R. D.; SANJURJO, D.; OTTONE, N. E. & FUENTES, R. Multiple anatomical variations of the hepatic pedicle. Case report and clinical application. *Int. J. Morphol.*, 32(3):782-785, 2014.

SUMMARY: The knowledge in detail of the anatomy of the hepatic pedicle is critical when operating it and its surroundings. The presence of anatomic variations is higher at the arterial component level than at the bile component level or venous component level, which in the 90% of the cases it appears as the classic description. The presented case in this work implies a very low frequency of appearance. For this reason, the surgeon must be alert at the moment of making a decision so as to avoid injuries that may put the patient's life at risk.

KEY WORDS: Hepatic pedicle; Hepatic hilum; Variations of the hepatic pedicle.

INTRODUCTION

In-depth knowledge about the anatomy of the hepatic pedicle is essential when carrying out surgical procedures on the anatomic region that includes the hepatic hilum and hilar area. The normal arrangement of the components within the liver pedicle is described as follows: the hepatic artery proper, ascending against the anterior left wall of the portal vein, runs alongside the inner wall of the common bile duct, all contained within the hepatoduodenal ligament (Bouchet *et al.*, 1990). These elements shape the anterior border of the epiploic foramen (also called foramen of Winslow), entry passage to the bursa omentalis. The arterial division giving off the right and left hepatic arteries is located below the biliary convergence. The right hepatic artery crosses either the common hepatic duct or the right hepatic duct, depending on the biliary convergence level. The most frequent occurrence is the artery crossing behind the bile duct, but in 13% of cases it crosses the duct in front of the bile duct (Michels, 1953, 1962).

The occurrence of anatomic variations on the hepatic pedicle is more frequent regarding the arterial component, less frequent regarding the biliary component, and the least infrequent regarding the venous component. Variations regarding the origin and course of the celiac trunk and hepatic arteries are well described by the literature; also, variations regarding the bile ducts. For its part, the venous component of the hepatic pedicle shows a normal location in over 90%

of cases, and variations regarding portal vein location are not frequent compared to portal vein formation (Mantovani *et al.*, 2002; Bergman *et al.*, 2006).

This work will show one case of multiple and simultaneous variations of the hepatic pedicle, which individually represent a low-frequency variation occurrence; but altogether, it results in a rare case. Our objective is to show the importance of knowing the normal anatomy of the hepatic pedicle and its variations, taking them into account during surgery, either open hepatobiliary-pancreatic or laparoscopic surgery, and in cases of hepatobiliary trauma, in order to avoid lesions that can bring serious complications that can consequently jeopardize the patient's life (Michels, 1953, 1962; Vandamme *et al.*, 1969; Rygaard *et al.*, 1986; Hiatt *et al.*, 1994; Marin *et al.*, 2001; Covey *et al.*, 2002; Mantovani *et al.*; Prabhasavat & Homgade, 2008).

CASE REPORT

The observation was made during the routine dissection conducted in the abdominal area of a corpse of a Caucasian male adult embedded in formalin 10%. We conducted the common dissection of the hepatic pedicle documented by Panasonic Lumix AZ30 digital camera.

* Instituto de Morfología "J.J. Naón", Facultad de Medicina, Universidad de Buenos Aires, Buenos Aires, Argentina.

** Facultad de Odontología, Universidad de La Frontera, Temuco, Chile.

*** Programa de Doctorado en Ciencias Morfológicas, Facultad de Medicina, Universidad de La Frontera, Temuco, Chile.

After dissecting the hepatoduodenal ligament, in first place, portal vein was found located medial from the other elements (Fig. 1). The common hepatic artery runs behind portal vein (Fig. 2). When reaching the right edge of the vein, it gives the left hepatic and gastroduodenal arteries, with the absence of the hepatic artery proper. The left hepatic artery is located to the right of portal vein and to the left of the extrahepatic bile duct, turning into the most ventral element of the pedicle (Fig. 3). The right hepatic artery passes behind the bile duct placing between this one and cystic duct and reaching the hepatic hilum. At this point, a very short cystic artery appears (Figs. 3 and 4).

The common hepatic artery originates from the superior mesenteric artery, thus in order to reach the hepatic

pedicle, it passes behind the pancreas neck, the first duodenal portion and, finally, it is located behind the portal vein and in front of the common bile duct. The celiac trunk, as is, does not exist; the splenic artery arises from aorta, immediately above the origin of the superior mesenteric artery and emits the left gastric artery as a collateral branch.

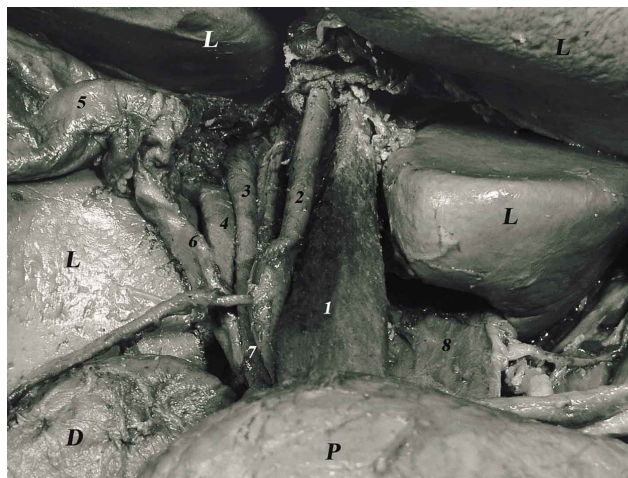


Fig. 1. Distribution of hepatic pedicle after the dissection of hepatoduodenal ligament. L. liver; D. Duodenum; P. Pancreas; 1. hepatic portal vein; 2. left hepatic artery; 3. common hepatic duct; 4. right hepatic artery; 5. gallbladder; 6. cystic duct; 7. bile duct; 8. vena cava inferior.

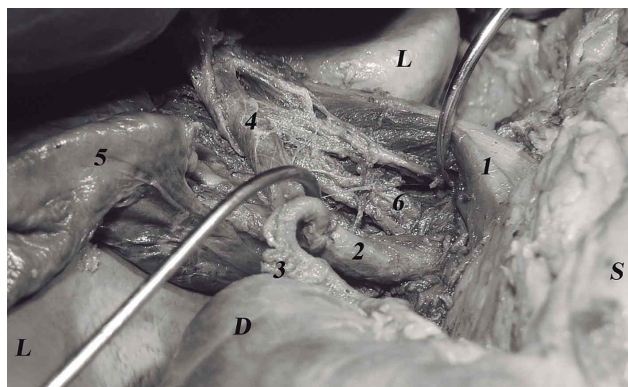


Fig. 2. The biliary tract is separated to a side and the portal vein to the other side to display the common hepatic artery between and posterior to those elements. L. liver; D. duodenum; S. stomach; 1. hepatic portal vein; 2. common hepatic artery; 3. right gastric artery; 4. left hepatic artery; 5. gallbladder; 6. bile duct.

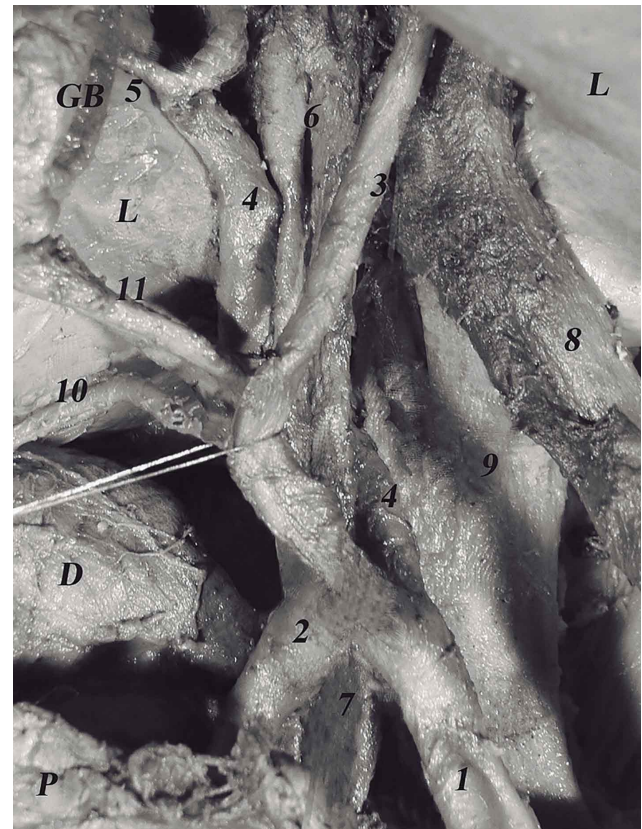

Fig. 3. Disposition of the right and left hepatic arteries, in absence of hepatic artery proper. L. liver; D. duodenum; P. pancreas; GB. gallbladder; 1. Common hepatic artery; 2. gastroduodenal artery; 3. left hepatic artery; 4. right hepatic artery; 5. cystic artery; 6. common hepatic duct; 7. bile duct; 8. hepatic portal vein; 9. inferior vena cava; 10. right gastric artery; 11. cystic duct.

DISCUSSION

The description of the variations of the hepatic pedicle, specially the modification of the location of the portal vein, is uncommon. Only Marks, in 1969, described the finding of the portal vein behind the common bile duct and the hepatic artery in 1 case out of 386 surgeries of the region (Bergman *et al.*).

Regarding the variations of celiac trunk and hepatic artery, several authors have made descriptions (Daly *et al.*,

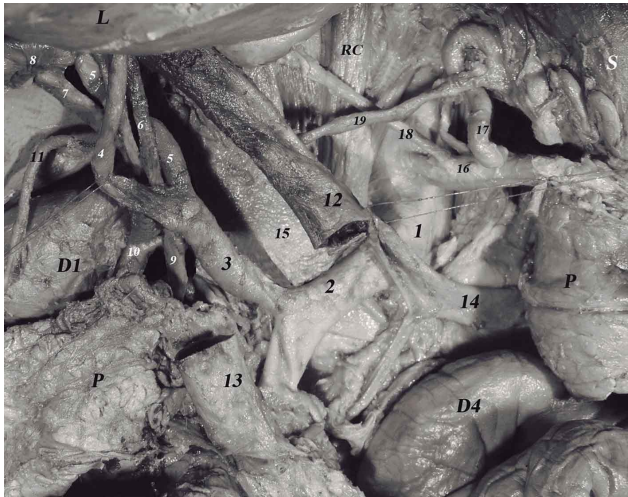


Fig. 4. Visualisation of the multiple anatomical variations after the ending of the dissection, in which the portal vein was sectioned. L. liver; D1. duodenum, superior part; RC. right crus (diaphragm); P. pancreas; D4. duodenum, ascending part; 1. aorta; 2. superior mesenteric artery; 3. common hepatic artery; 4. left hepatic artery; 5. right hepatic artery; 6. common hepatic duct; 7. cystic duct; 8. gallbladder; 9. bile duct; 10. gastroduodenal artery; 11. right gastric artery; 12. hepatic portal vein; 13. superior mesenteric vein; 14. splenic vein; 15. inferior vena cava; 16. splenic artery; 17. left gastric artery; 18. inferior diaphragmatic artery; 19. gastric vein.

1984; Rygaard *et al.*; Marín *et al.*; Covey *et al.*; Ottone *et al.*, 2006; Petrella *et al.*, 2007; Prabhasavat & Homgade), and they have also described the absence of celiac trunk as the origin of the common hepatic artery from the superior mesenteric artery (Michels, 1953, 1962; Vandamme *et al.*; Hiatt *et al.*; Limura *et al.*, 2007). In Michels' classification (1953), the common hepatic artery arises from the superior mesenteric artery in the 2.5% of the cases (type IX), while according to Hiatt *et al.* it is found in the 1.5% of the cases (type V). This arterial disposition is consistent with type V described by Adachi (1928), found in 0.4% (of a total of 252 investigated cases). In most of these cases, the common hepatic artery runs behind portal vein and common bile duct. The exception is the case of Peschard *et al.* (2006), in which the common hepatic artery arises from the superior mesenteric artery, runs in front of the portal vein. In our work the common hepatic artery after passing behind the first portion of the duodenum, passes behind portal vein and in front of common bile duct. A similar description has been made by Wang *et al.* (2010), in which the common hepatic artery travels behind portal vein and then passes in front of common bile duct. However, in that case, the common hepatic artery arose from the celiac trunk.

In our work, as far as pedicle is concerned, the most

anterior element turned out to be the left hepatic artery, whereas the right one runs behind it and bile duct and runs to the right appearing between bile duct and cystic duct, where it emits a very short cystic artery.

Regarding extra-hepatic bile duct, the abnormalities of the traveling are completely exceptional. Some cases of pre-duodenal traveling of main bile duct along with portal vein have been described (Bouchet *et al.*). In our case the composition of it is normal, but it presents a varied space location, to the right and dorsal to the portal vein while its normal location is in front of and to the right of the vein.

Most surgical lesions on the bile duct are caused by the misinterpretation of the anatomy, as well as the presence of anatomic variations.

Knowing the occurrence of diverse anatomic variations is a must to reduce the number of malpractice cases and complications during traditional and laparoscopic hepatobiliary-pancreatic surgery, both associated to a high morbidity rate; in addition, the surgeon will apply this knowledge during surgery due to hepatic injury, when handling the liver pedicle during damage control surgery, during a conventional or laparoscopic cholecystectomy, during liver transplant surgery, during duodeno-pancreatectomy, radical gastrectomy, and countless surgeries that are typical of this complex anatomic region (Vandamme *et al.*, 1969; Suzuki *et al.*, 1971; Hardy & Jones, 2001).

Even though the hepatic pedicle structure is known to vary, the case shown in this work has not been previously described in the literature so it is assumed to have a very low occurrence. In the hepatic pedicle, the ventral location of the portal vein determines a change in the location of the other components, which is defined as follows: the portal vein runs ventrally and medially; the left hepatic artery runs ventrally and laterally; the extrahepatic portion of the bile duct runs dorsally and laterally to the portal vein and left hepatic artery; and the right hepatic artery runs dorsally to all components. These highly-infrequent location cases of hepatic pedicle anatomic variation force the attending surgeon to keep to bring up the appropriate and detailed knowledge about the normal anatomy of the hepatic pedicle and its variations in order to plan and safely carry out surgical procedures during hepatobiliary-pancreatic surgery ("open" or laparoscopic), hepatobiliary injury and damage control surgery, aiming at the best possible results and avoiding lesions that can jeopardize the patient's life.

BIANCHI, H. F.; ALGIERI, R. D.; SANJURJO, D.; OTTONE, N. E. & FUENTES, R. Múltiples variaciones anatómicas del pedículo hepático. Reporte de caso y aplicación clínica. *Int. J. Morphol.*, 32(3):782-785, 2014.

RESUMEN: El conocimiento en detalle de la anatomía del pedículo hepático es fundamental al momento de intervenir quirúrgicamente sobre el mismo y su vecindad. La presencia de variaciones anatómicas es mayor a nivel del componente arterial, luego biliar y finalmente venoso, el cual en el 90% de los casos se dispone de acuerdo con la descripción clásica. El caso presentado en este trabajo supone una muy baja frecuencia de aparición, siendo precisamente estas disposiciones poco habituales las que obligan al cirujano a mantenerse alerta en el momento de actuar para evitar injurias que puedan comprometer la vida del paciente.

PALABRAS CLAVE: Pedículo hepático; Hilio hepático; Variaciones del pedículo hepático.

REFERENCES

- Adachi, B. *Das Arteriensystem der Japaner*. Band II. Kyoto, Maruzen, Kaiserlich-Japanischen Universität zu Kyoto, 1928. 18-71 p.
- Bergman, R. A.; Afifi, A. K. & Miyauchi, R. *Illustrated Encyclopedia of Human Anatomic Variation*. Opus II: Cardiovascular System: Veins: Abdomen. Portal Vein. 2006. Disponible en: <http://www.anatomyatlases.org/AnatomicVariants/Cardiovascular/Text/Veins/Portal.shtm>
- Bouchet, Y.; Passagia, J. G. & López, J. F. *Anatomie des voies biliaires extrahepatiques*. – Encycl. Méd. Chir. Techniques chirurgicales – Appareil digestif. Paris, Elsevier, 1990. p.16.
- Covey, A. M.; Brody, L. A.; Maluccio, M. A.; Getrajdman, G. I. & Brown, K. T. Variant Hepatic Arterial Anatomy Revisited: Digital Subtraction Angiography Performed in 600 Patients. *Radiol.*, 224(2):542-7, 2002.
- Daly, J. M.; Kemeny, N. & Botet, J. Longterm hepatic arterial infusion chemotherapy. *Arch. Surg.*, 119(8):936-41, 1984.
- Hardy, K. J. & Jones, R. M. The hepatic artery: A reminder of surgical anatomy. *J. Roy. Coll. Surg. Edinb.*, 46(3):168-70, 2001.
- Hiatt, J.; Gabbay, J. & Busuttill, R. Surgical anatomy of the hepatic arteries in 1000 cases. *Ann. Surg.*, 220(1):50-2, 1994.
- Limura, A.; Oguchi, T.; Shibata, M. & Takahashi, T. An anomalous case of hepatic artery arising from the superior mesenteric artery. *Okajimas Folia Anat. Jpn.*, 84(2):61-6, 2007.
- Mantovani, M.; Leal, R. F. & Fontelles, M. I. Anatomic study of portal vein, transpancreatic vessels injuries approach. *Acta Cir. Bras.*, 17(4):225-31, 2002.
- Marín, L. M.; Gómez, M. A.; Bernal, C.; Álamo, J. M.; Suárez, G. & Serrano, J. Variability of the Extrahepatic Arterial Anatomy in 500 Hepatic Grafts. *Transplant. Proceed.*, 42(8):3159-61, 2001.
- Michels, N.A. Variational anatomy of the hepatic, cystic, and retroduodenal arteries; a statistical analysis of their origin, distribution, and relations to the biliary ducts in two hundred bodies. *AMA Arch. Surg.*, 66(1):20-34, 1953.
- Michels, N.A. Newer anatomy of the liver and its variant blood supply and collateral circulation. *Am. J. Surg.*, 112(3):337-47, 1962.
- Ottone, N. E.; Arrotea Molina, A.; Domínguez, M. L.; Lo Tartaro, M.; García De Quiros, N.; Medan, C.; Blasi, E. & Bertone, V. H. Arterias hepáticas aberrantes. Estudio sobre 64 cadáveres disecados. *Int. J. Morphol.*, 24(4):581-5, 2006.
- Peschaud, F.; El-Hajjam, M.; Malafosse, R.; Goere, D.; Benoist, S.; Penna, C. & Nordlinger, B. A common hepatic artery passing in front of the portal vein. *Surg. Radiol. Anat.*, 28(2):202-5, 2006.
- Petrella, S.; Fernando de Sousa Rodriguez, C.; Sgrott, E. A.; Medeiros Fernandes, G. J.; Marques, S. R. & Prates, J. C. Anatomía y Variaciones del Tronco Celíaco. *Int. J. Morphol.*, 25(2):249-57, 2007.
- Prabhasavat, K. & Homgade, C. Variation of Hepatic Artery by 3-D Reconstruction MDCT Scan of Liver in Siriraj Hospital. *J. Med. Assoc. Thai.*, 91(11):1748-53, 2008.
- Rygaard, H.; Forrest, M.; Mygind, T. & Baden, H. Anatomic variants of the hepatic arteries. *Acta Radiol. Diagn.*, 27(4):425-7, 1986.
- Suzuki, T.; Nakayasu, A.; Kawabe, K.; Takeda, H. & Honjo, I. Surgical significance of anatomic variations of the hepatic artery. *Am. J. Surg.*, 122(4):505-12, 1971.
- Vandamme, J. P. J.; Bonte, J. & Schueren, G. A reevaluation of hepatic and cystic arteries. The importance of the aberrant hepatic branches. *Acta Anat.*, 73(2):192-209, 1969.
- Wang, M. J.; Cheng, Z.; Wang, R.; Li, Y. & Zhou, Z. G. Unusual course of the common hepatic artery originating from the celiac trunk. *Surg. Radiol. Anat.*, 32(9):883-85, 2010.

Correspondence to:
Nicolas Ernesto Ottone
Facultad de Odontología
Universidad de La Frontera
Av. Francisco Salazar 01145, Temuco
CHILE

Email: nicolas.ottone@ufrontera.cl

Received: 12-04-2014

Accepted: 24-05-2014