

# Anatomic Study of the Distance Between the Lower Margin of the Mandible and the Marginal Mandibular Branch of the Facial Nerve: A Systematic Review

Estudio Anatómico de la Distancia entre el Margen Mandibular y la Rama Marginal Mandibular del Nervio Facial: Una Revisión Sistemática

Pedro Christian Aravena<sup>\*\*</sup>; Rodrigo Santibáñez<sup>\*\*</sup>; Pablo Rubilar<sup>\*\*</sup>; Christian Espinoza<sup>\*\*</sup> & Francisco Pérez-Rojas<sup>\*\*\*</sup>

ARAVENA, P. C.; SANTIBÁÑEZ, R.; RUBILAR, P.; ESPINOZA, C. & PÉREZ-ROJAS, F. Anatomic study of the distance between the lower margin of the mandible and the marginal mandibular branch of the facial nerve: a systematic review. *Int. J. Morphol.*, 32(1):327-333, 2014.

**SUMMARY:** The marginal mandibular branch of the facial nerve (MMB) has a significant variation in relation to the lower border of the mandible (LBM). That is why it is important to know its topographical description to prevent damage in submandibular surgical procedures. The objective of this study was to determine the distance between the MMB and LBM based on descriptive studies carried out on human corpses and surgical patients. A systematic review of literature in MEDLINE, "Science Citation Index Expanded" of Web of Science (ISI) databases and manual search was performed. The articles with number of samples greater than or equal to 10 facial samples and recording of measurements between the MMB and the LBM or Gonion were selected. From the selected articles, the authors registered year of publication, country of origin, number of samples, sample type (fresh, embalmed body/fixated cadavers or surgical patient), distribution percentage of the MMB in relation to LBM, average and maximum distance between MMB and LBM or Gonion. The results were presented in tables with descriptive statistic. Seventeen articles describing measurements of the distance between MMB and the lower border of the mandible carried out in cadavers and patients were selected. In these articles a total of 1,408 samples were dissected. The maximum distance observed was 4.01 cm (mean±SD 1.64±0.92 cm, Min= 0.69; Max= 4.01). Several reports suggest that an incision 2 cm below the lower border of the mandible would be enough to avoid damage of the MMB. However, according to the maximal distances registered, such an incision might involve risk for the MMB. For this reason, we propose that the MMB of facial nerve should be at least 4 cm below the lower border of the mandible.

**KEY WORDS:** Anatomy and histology; Facial Nerve; Facial Nerve Injuries; Surgery; Oral; Head and Neck Neoplasms; Review Literature as Topic.

## INTRODUCTION

The marginal mandibular branch (MMB) originates in the facial nerve and is responsible for providing motor innervation to the circumoral musculature, which is primarily responsible for lip expression (Batra *et al.*, 2010). Due to its location, this branch can be damaged during cervical surgeries and particularly in surgeries confined to the submandibular region (Wang *et al.*, 1991), such as fixation of mandibular angle fractures (Cabrini Gabrielli *et al.*, 2003), parotidectomies (Barry *et al.*, 2007; Mra *et al.*, 1993), submandibular gland excisions (Milton *et al.*, 1986), carotid endarterectomies (Aldoori & Baird, 1988; Assadian *et al.*,

2004), rhytidectomy and liposuction surgery (Liebman *et al.*, 1988). It can be also damaged during the deep dissection of the neck (Nason *et al.*, 2007).

The classical approach in these procedures is to use the Risdon's technique or submandibular approach: an incision of 4-5 cm long and 2 cm below and posterior to the angle of the mandible (Ebenezer & Ramalingam, 2011). The most common cause of paralysis of this nerve is due to iatrogenic damage during surgery in the mandibular or parotid regions (Batra *et al.*; O'Brien, 2007; Toure *et al.*,

\* Institute of Anatomy, Histology and Pathology. Faculty of Medicine, Universidad Austral de Chile, Valdivia, Chile.

\*\* School of Dentistry. Faculty of Medicine, Universidad Austral de Chile, Valdivia, Chile.

\*\*\* Faculty of Health Sciences. Medicine, Universidad Autónoma de Chile, Talca, Chile.

2004; Woltmann *et al.*, 2006). Its damage can cause salivary incontinence and aesthetic impairment due to an alteration in the balance of the musculature around the lower lip, in its lateral, downward and inversion movements (Moffat & Ramsden, 1977). These complications are difficult to correct (Stern, 1992). However, in most cases it may be temporary, with a recovery time that ranges from 3 to 6 months after surgery (Nason *et al.*).

The high incidence of injury to the MMB may be related to the proportionally greater number of operations in the region of the mandible (Dingman & Grabb, 1962), but also to the lack of an accurate description of the course of this nerve in the anatomical textbooks (Moore, 1985; Williams *et al.*, 1995).

According to Suazo & Manterola (2010), it is possible to evaluate a number of morphological topics through systematic review of the literature. Therefore, the aim of this work was to determine the distance between the MMB and Lower Border of Mandible (LBM) based on descriptive studies carried out on human corpses and surgical patients, and then to propose a suitable length for surgical access of the neck.

## MATERIAL AND METHOD

A systematic review of literature was performed according to the PRISMA statement reporting guideline (Moher *et al.*, 2010). Research was carried out taking into consideration anatomical and surgical descriptive studies that recorded the distance between MMB and LBM or Gonion on cadavers or patients. Articles reviewed were published between 1960 and 2013, in English, and available in electronic databases Medline by PubMed (<http://www.ncbi.nlm.nih.gov/pubmed/>) and “Science Citation Index Expanded” of Web of Science of Thomson Reuters (ISI) database ([www.webofknowledge.com](http://www.webofknowledge.com)) on January 10th, 2014. In addition, a manual search of the biomedical literature available in the Central Library from Universidad Austral de Chile was performed. The search strategy is summarized in Table I.

Table I. Keywords and limits used by database.

Databases	Key Words or Advanced search terms	Limits
MEDLINE	“facial nerve AND marginal AND mandible”	Humans, adults ≥19 years, English language Types of documents =(articles)
Web of Science	(TI=(facial nerve) AND TS=mandible)	Database= Science Citation Index Expanded (SCI-EXPANDED) Timespan= from year 1988 to 2013

After collecting the data, according to search strategy, two authors (RS and PR) read the publication’s abstracts and titles, discarding papers that did not meet the following search criteria: number of samples greater than or equal to 10 facial samples and recording of measurements between the MMB and the LBM or Gonion.

From the selected articles, the authors registered year of publication, country of origin, number of samples, sample type (fresh, embalmed body/fixed cadavers or surgical patient), distribution percentage of the MMB in relation to LBM, mean and maximum distance between MMB and LBM or Gonion. Furthermore, the degree of bias in the selected articles was presented qualitatively by including the anatomical points upon the measurements that were made.

In those articles where the authors (RS and PR) had discrepancies in the classification/collection of data, a consensus was reached qualitatively by assessing the article by a third author (PA). Consequently, the data found were tabulated and summarized in Table II. The results were analyzed with the statistical software STATA 10.0, using descriptive statistics.

## RESULTS

Sixty-one articles were obtained from the electronic databases and 3 articles from the manual search of the literature. Those with duplicates in the databases, which did not meet the selection criteria and the articles that lacked full text, were excluded. In total, 17 articles were selected for further analysis (Fig. 1).

These articles were published between 1962 and 2013 and around 50% of them were from Asian origin. The data were collected from 1,121 cadavers and 287 patients. The measurements were made from different anatomical points, being the lowest point of the arc of the nerve the most used. The extreme landmarks were the facial artery and Gonion, anteriorly and posteriorly, respectively. The name of authors, country of origin, sample condition and measurement landmarks used in each report are summarized in Table II.

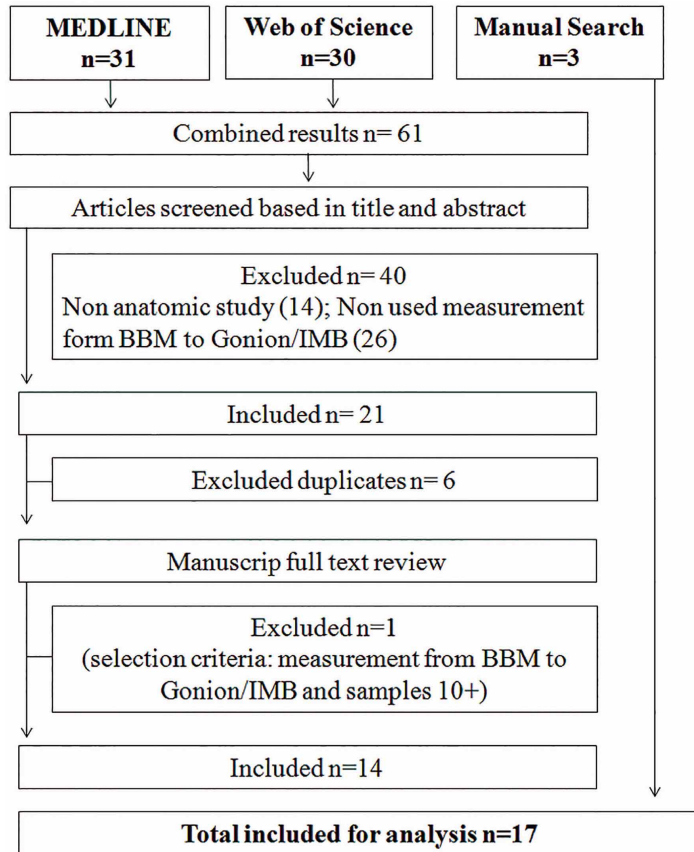


Fig. 1. Flow chart of literature review and selection criteria.

The average maximum distance between MMB and LBM was  $1.5 \pm 0.74$  cm (min = 0.69; max = 4.01) (Table III).

## DISCUSSION

In this revision, the highest value between the MMB of the LBM was 4.01 cm (Karapinar *et al.*, 2013) and 3 cm was found (Nason *et al.*; Wang *et al.*). Most of the researches used attached bodies, but an important number of samples (n=287) were patients (Nason *et al.*; Balagopal *et al.*, 2012). The selected articles demonstrated, also, the variation of the position and itinerary of the facial nerve according to if the dissection of the neck were conducted in neck extension and neutral position. In addition, they indicated that the measurements on neutral position were the lowest for distances between the MMB and the LBM. Wang *et al.*, have the third largest number of cases studied (n=120) showed an average of 0.95 cm, and 4.34% of the cases have a range between 2.1 and 3 cm. Moreover, an average of 50% was observed regarding the course of the MMB below the LBM. Finally, an average of 50% showed the course of the MMB below the LBM, which has a range that fluctuates from 15% to 100% (Basar *et al.*, 1997).

Possible explanations to the variations of the distances measured by the authors include the position of the head when making the measurement (Nason *et al.*) and also the state of the cervical tissues, since in fresh corpses samples or living patients with lax connective tissue, the MMB can be found as low as 3-4 cm from the LBM (Moffat & Ramsden) versus fixed corpses samples whose tissues contract and stiffen. There may be differences in the measurements inherent to the volume by dehydration in human corpses (Nason *et al.*) and edema in surgical patients with greater relevance in those cases showing a traumatic lesion.

Surgical practice has divulged, through texts and surgical atlas, the dissection measures known as the Risdon technique, corresponding to an incision of 2 cm below the LBM (Toure *et al.*). To achieve this distance the authors propose to mark a projection of one (Dingman & Grabb) or two (Ziarah & Atkinson, 1981; Cranin, 1975; Ellis & Zide, 1995; Potgieter *et al.*, 2005) finger width below the LBM. At the time this review was carried out, we observed other recommendations as varied as making the incision at a distance of at least 1.6 cm from LBM and Gonion (Batra *et al.*), 2.1cm (Karapinar *et al.*) and 3 cm or more (Wang *et al.*; Woltmann *et al.*; Savary *et al.*, 1997; Kim *et al.*, 2009; Zani *et al.*, 2003).

The limitations of our study were also considered: articles were recovered from only 2 databases Science Citation Index Expanded via Web of Science and MEDLINE only over the decade from 1961 to 2013 year. We excluded reports in languages other than English, as well as studies in which it was impossible to perform a meta-analysis due to the nature of the data. Despite these limitations, the articles analyzed included those in which a direct clinical or anatomical assessment of distance between MMB of the LBM was performed, excluding studies with other points of measurement for to compare the results between reports. However, because of the diverse measurements found, as well as the lack of homogeneity in their definitions and the measurement methods used, the inclusion of other papers, from other databases, in other languages, would produce even more diffuse results.

Although the number of articles and samples studied could provide a clear distance from the MMB to the LBM, the methodology used is not comparable between articles. They differ in their geographical

Table II. Name of authors, country, sample conditions and measurement landmark between the Marginal Mandibular Branch of Facial Nerve (MMB) and Lower Border of Mandible (LBM) of each articles selected.

Author (year)	Country	Sample condition	Measurement landmarks	Additional coments
Dingman & Grabb (1962)	USA	Human corpses	The lowest point of the arc of the nerve	Publication does not indicate whether the samples were fixed
Ziarah & Atkinson (1981)	England	Fixed	The lowest point between the nerve and the mandibular body	
Wang <i>et al.</i> (1991)	China	Human corpses	The lowest point of the arc of the nerve	Publication does not indicate whether the samples were fixed or fresh. Explicit ethnicity of the samples: China
Savary <i>et al.</i> (1997)	France	Fresh and Fixed	-	1 Fresh/10 Fixed
Basar <i>et al.</i> (1997)	Turkey	Fixed	IBM crosspoint with the facial artery	
Zani <i>et al.</i> (2003)	Brazil	Human corpses	-	Publication does not indicate whether the samples were fixed or fresh
Potgieter <i>et al.</i> (2005)	South Africa	Fixed	Just anterior to the facial artery on the IBM	
Woltmann <i>et al.</i> (2006)	Brazil	Fixed	The lowest point of the arc of the nerve	
Nason <i>et al.</i> (2007)	Canada/Saudi Arabia	Patients	The lowest point of the nerve between the posterior and anterior facial veins	
Al-Hayani (2007)	Saudi Arabia	Human corpses	Exit of the parotid gland	Publication does not indicate whether the samples were fixed or fresh
Saylam <i>et al.</i> (2007)	Turkey	Fixed	-	
Kim Di <i>et al.</i> (2009)	Korea	Fresh and Fixed	IBM crosspoint with the facial artery	Explicit ethnicity of the samples: Korea. 29 Fresh/20Fixed
Russo <i>et al.</i> (2009)	Italy/Georgia	Fixed	The lowest point of the arc of the nerve	
Batra <i>et al.</i> (2010)	India	Fixed	Gonion	
Weerapant <i>et al.</i> (2010)	Thailand	Fixed	Gonion	
Balagopal <i>et al.</i> (2012)	India	Patients	Facial Artery	202 patients; 144 males and 58 females
Karapinar <i>et al.</i> (2013)	Turkey	Fixed	--	Using digital calipers, 18 males and 4 females

§=Place where average and maximum distance were measured.

origins, type of samples, sex, variability in the number of collateral branches (Dingman & Grabb; Basar *et al.*; Savary *et al.*; Kim *et al.*; Balagopal *et al.*) and the anatomic landmarks chosen for the measurements. These are all elements that can generate and increase variations in the results and, therefore, difficulty when comparing them. The different methodologies that were used to obtain the results in these articles and the lack of statistical methods, did not allow scientific analysis to determine a reliable distance. Thus, to understand if the variability of the observed measurements corresponds to the real situation or if it is an artifact of different methodologies, a statistical design is needed.

In view of what has been said so far, the distance parameter (2 cm) based on what has been described by anatomy and surgical textbooks, is ambiguous and can be misleading. Likewise, there are reports that indicate that an incision between 3 to 4 cm below the LBM (Wang *et al.*; Savary *et al.*; Kim *et al.*; Zani *et al.*), is sufficient to avoid consequent damage to the MMB. Hence, to establish its clinical validity, the surgeon must be extremely careful.

As a conclusion, and based on the data found throughout this systematic review, we propose that the MMB of facial nerve should be at least 4 cm below the lower border of the mandible.

Table III. Number of samples and distances between MMB and LBM of each articles selected.

Author (year)	Samples (facial halves)	Below IBM* (%)	A verage distance <sup>†</sup> (cm)	Maximum distance <sup>‡</sup> (cm)
Dingman & Grabb (1962)	100	19	-	1.00
Ziarah & Atkinson (1981)	110	53	-	1.20
Wang <i>et al.</i> (1991)	120	33	0.95	3.00
Savary <i>et al.</i> (1997)	22	63 <sup>c</sup>	-	1.00
Basar <i>et al.</i> (1997)	40	15 <sup>d</sup>	0.503±0.326 <sup>g</sup>	1.06
Zani <i>et al.</i> (2003)	300	60	-	2.00
Potgieter <i>et al.</i> (2005)	36	78	-	0.69
Woltmann <i>et al.</i> (2006)	45	42	-	1.30
Nason <i>et al.</i> (2007)	85	92 <sup>E</sup>	1.25±0.7	3.00
Al-Hayani (2007)	50	72 <sup>D</sup>	-	2.30
Saylam <i>et al.</i> (2007)	50	26 <sup>D</sup>	0.696±0.167	1.004
Kim Di <i>et al.</i> (2009)	85	31 <sup>c</sup>	-	1.53
Russo <i>et al.</i> (2009)	20	100 <sup>F</sup>	0.67±0.169	1.04
Batra <i>et al.</i> (2010)	50	32	1.5	1.60
Weerapant <i>et al.</i> (2010)	49	43	0.91±0.22	1.35
Balagopal <i>et al.</i> (2012)	202	60 <sup>D</sup>	1.73±1.57	0.8
Karapinar <i>et al.</i> (2013)	44	100	2.19±0.82	4.01
<b>Total</b>	1408	-	-	-
<b>Average</b>	-	54	-	1.64

\*= Shows the percentage of samples in which the MMB, or one of its rami, was below the LBM, in relation to the total number of samples.

†= Average of measurements made from the LBM to the MMB when it was below the LBM.

‡= Maximum distance measured by the author from the LBM to MMB when the nerve was below de LBM.

C= It was calculated according to the total number of rami of the MMB.

D= The percentage was calculated by us with the data provided by the author, taking into account the samples in which one of its rami the MMB, was below the LBM, in relation to the total number of samples.

E= The percentage was calculated by us with the data provided by the author, taking into account the samples in which the MMB=was below the LBM, in relation to the total number of samples.

F= The authors did not specify if the took into consideration if the samples passed below the LBM for inclusion in his study.

G= The average was calculated by us with the published data. Note it was recorded in its respective paper with a negative sign (-).

H= The maximum distance was published by the respective author as the minimum distance recorded. Note it was published originally with a negative sign (-).

We recommend that an incision of at least 3 cm parallel to the LBM should be made, adding a safety margin higher than 1 cm based of maximum distance looked in report of Karapinar *et al.* Thus, the concomitant damage that may affect the MMB, causing neurologic sequelae, can be avoided, even if it means increasing the difficulty of the surgical technique.

**ACKNOWLEDGMENTS.** We are thankful to Miguel Reyes, Carolina Vergara and Günther Preisler for having kindly fully reviewed and comments to this paper. This paper is based on a thesis submitted in partial fulfillment of the requirements for the degree of Bachelor in Dental Surgery in the School of Dentistry of the Universidad Austral de Chile.

**ARAVENA, P. C.; SANTIBÁÑEZ, R.; RUBILAR, P.; ESPINOZA, C. & PÉREZ-ROJAS, F.** Estudio anatómico de la distancia entre el borde mandibular y la rama marginal mandibular del nervio facial: Una revisión sistemática. *Int. J. Morphol.*, 32(1):327-333, 2014.

**RESUMEN:** La rama mandibular marginal del nervio facial (RMM) posee variaciones significativas en su relación con el margen inferior de la mandíbula (MIM), siendo importante su descripción topográfica para evitar su daño en procedimientos quirúrgicos submandibulares. El objetivo fue determinar la distancia RMM y MIM observadas en humanos. Se realizó una revisión sistemática de la literatura en las bases de datos MEDLINE, "Science Citation Index Expanded" de Web of Science (ISI) y una búsqueda manual. Se seleccionaron artículos con análisis de 10 o más muestras y que registrarán la distancia entre el RMM y el MIM o Gonion. Se registró autor, países de origen, condición de la muestra, número de muestras, distancias promedio y máximas registradas. Los resultados se analizaron mediante estadística descriptiva y presentada en tablas. Se seleccionaron 17 artículos con mediciones de las distancias entre el RMM y MIM tanto en cadáveres como pacientes. En total, 1,408 muestras fueron disecadas. La distancia máxima registrada fue de 4.01 cm (promedio±DE 1.64±0.92 cm, Min= 0,69; Max= 4,01). Diversos reportes sugieren que una incisión a 2 cm bajo el margen inferior de la mandíbula sería suficiente para evitar el daño al RMM. Sin embargo, con las distancias máximas observadas dicha incisión podría generar un daño. Por lo tanto, esta revisión sugiere la presencia del RMM a lo menos a 4 cm bajo el margen inferior de la mandíbula.

**PALABRAS CLAVE:** Anatomía; Nervio Facial; Cirugía Oral; Cirugía Maxilofacial; Cuello; Revisión sistemática.

## REFERENCES

- Al-Hayani, A. Anatomical localisation of the marginal mandibular branch of the facial nerve. *Folia Morphol. (Warsz)*, 66(4):307-13, 2007.
- Aldoori, M. I. & Baird, R. N. Local neurological complications during carotid endarterectomy. *J. Cardiovasc. Surg. Torino*, 29(4):432-6, 1988.
- Assadian, A.; Senekowitsch, C.; Pfaffelmeyer, N.; Assadian, O.; Ptakovsky, H. & Hagmüller, G. W. Incidence of cranial nerve injuries after carotid eversion endarterectomy with a transverse skin incision under regional anaesthesia. *Eur. J. Vasc. Endovasc. Surg.*, 28(4):421-4, 2004.
- Balagopal, P. G.; George, N. A. & Sebastian, P. Anatomic variations of the marginal mandibular nerve. *Indian J. Surg. Oncol.*, 3(1):8-11, 2012.
- Barry, O.; Girish, B.; Satwant, B. & Victoria, C. Facial nerve morbidity after retrograde nerve dissection in parotid surgery for benign disease: A 10-year prospective observational study of 136 cases. *Br. J. Oral Maxillofac. Surg.*, 45(2):101-7, 2007.
- Basar, R.; Sargon, M. F.; Tekdemir, Y. & Elhan, A. The marginal mandibular branch of the facial nerve. *Surg. Radiol. Anat.*, 19(5):311-4, 1997.
- Batra, A.; Mahajan, A. & Gupta, K. Marginal mandibular branch of the facial nerve: An anatomical study. *Indian J. Plast. Surg.*, 43(1):60-4, 2010.
- Cabrini Gabrielli, M. A.; Real Gabrielli, M. F.; Marcantonio, E. & Hochuli-Vieira, E. Fixation of mandibular fractures with 2.0-mm miniplates: review of 191 cases. *J. Oral Maxillofac. Surg.*, 61(4):430-6, 2003.
- Cranin, A. N. Comparison of two submandibular incisions on the motor function of lower lip. *Oral Surg. Oral Med. Oral Pathol.*, 40(3):327-32, 1975.
- Dingman, R. O & Grabb, W. C. Surgical anatomy of the mandibular ramus of the facial nerve based on the dissection of 100 facial halves. *Plast. Reconstr. Surg. Transplant. Bull.*, 29:266-72, 1962.
- Ebenezer, V. & Ramalingam, B. Comparison of approaches for the rigid fixation of sub-condylar fractures. *J. Maxillofac. Oral Surg.*, 10(1):38-44, 2011.
- Ellis III, E. & Zide, M. F. *Surgical approaches to facial skeleton*. Philadelphia, Williams and Wilkins, 1995.
- Karapinar, U.; Kilic, C.; Cetin, B.; Saglam, O.; Dursun, E. & Durmus, M. The course of the marginal mandibular branch of the facial nerve in adult cadavers. An anatomic study. *Saudi Med. J.*, 34(4):364-8, 2013.
- Kim, D.; Nam, S. H.; Nam, Y. S.; Lee, K. S.; Chung, R. H & Han, S. H. The marginal mandibular branch of the facial nerve in Koreans. *Clin. Anat.*, 22(2):207-14, 2009.
- Liebman, E. P.; Webster, R. C.; Gaul, J. R. & Griffin, T. The marginal mandibular nerve in rhytidectomy and lipo-suction surgery. *Arch. Otolaryngol. Head Neck Surg.*, 114(2):179-81, 1988.
- Milton, C. M.; Thomas, B. M. & Bickerton, R. C. Morbidity study of submandibular gland excision. *Ann. R. Coll. Surg. Engl.*, 68(3):148-50, 1993.
- Moffat, D. A. & Ramsden, R. T. The deformity produced by palsy of the marginal mandibular branch of the facial nerve. *J. Laryngol. Otol.*, 91(5):401-6, 1977.
- Moore, K. L. *Clinically Oriented Anatomy*. 2nd ed. Baltimore, Williams and Wilkins, 1985.
- Moher, D.; Liberati, A.; Tetzlaff, J.; Altman, D. G. & PRISMA Group. Preferred reporting items for systematic reviews and meta-analyses: the PRISMA statement. *Int. J. Surg.*, 8(5):336-41, 2010.
- Mra, Z.; Komisar, A. & Blaugrund S. M. Functional facial nerve weakness after surgery for benign parotid tumours: A multivariate statistical analysis. *Head Neck*, 15(2):147-52, 1993.
- Nason, R. W.; Binahmed, A.; Torchia, M. G & Thliversis, J. Clinical observations of the anatomy and function of the marginal mandibular nerve. *Int. J. Oral Maxillofac. Surg.*, 36(8):712-5, 2007.
- O'Brien, C. J. Facial nerve localization in parotid surgery. *ANZ J. Surg.*, 72(5):370, 2002.
- Potgieter, W.; Meiring, J. H.; Boon, J. M.; Pretorius, E.; Pretorius, J. P. & Becker, P. J. Mandibular Landmarks as an Aid in Minimizing Injury to the Marginal Mandibular Branch: A Metric and Geometric Anatomical Study. *Clin. Anat.*, 18(3):171-8, 2005.
- Russo, A.; Albanese, E.; Quiroga, M. & Ulm, A. J. Submandibular approach to the C2-3 disc level: microsurgical anatomy with clinical application. *J. Neurosurg. Spine*, 10(4):380-9, 2009.
- Savary, V.; Robert, R.; Rogez, J. M.; Armstrong, O. & Leborgne, J. The mandibular marginal ramus of the facial nerve: an anatomic and clinical study. *Surg. Radiol. Anat.*, 19(2):69-72, 1997.
- Saylam, C.; Ucerler, H.; Orhan, M.; Uckan, A. & Ozek, C. Localization of the marginal mandibular branch of the facial nerve. *J. Craniofac. Surg.*, 18(1):137-42, 2007.

Stern, S. J. Precise localization of the marginal mandibular nerve during neck dissection. *Head Neck*, 14(4):328-31, 1992.

Suazo, G. I. & Manterola, D. C. What is published in Human Morphology? Types of designs and Levels of evidence. *Int. J. Morphol.*, 28(2):461-70, 2010.

Toure, S.; Vacher, C. & Bertrand, J. C. Anatomy of the marginal mandibular branch of facial nerve. *Rev. Stomatol. Chir. Maxillofac.*, 105(3):149-52, 2004.

Wang, T. M.; Lin, C. L.; Kuo, K. J. & Shih, C. Surgical anatomy of mandibular ramus of the facial nerve in Chinese adults. *Acta Anat. (Basel)*, 142(2):126-31, 1991.

Weerapant, E.; Bunaprasert, T.; Chokrungrvaranont, P. & Chentanez, V. Anatomy of the facial nerve branching patterns, the marginal mandibular branch and its extraparotid ramification in relation to the lateral palpebral line. *Asian Biomed.*, 4(4):603-8, 2010.

Williams, P. L.; Bannister, L. H.; Berry, M. M.; Collins, P.; Dyson, M.; Dussek, J. E. & Ferguson M. W. J. *Gray's Anatomy*. 38<sup>th</sup> ed. London, Churchill Livingstone, 1995.

Woltmann, M.; Faveri, R. & Sgrott, E. A. Anatomical study of the marginal mandibular branch of the facial nerve for submandibular surgical approach. *Braz. Dent. J.*, 17(1):71-4, 2006.

Zani, R.; Fadul, R. Jr.; Da Rocha, M. A.; Santos, R. A.; Alves, M. C. & Ferreira, L. M. Facial nerve in rhytidoplasty: anatomic study of its trajectory in the overlying skin and the most common sites of injury. *Ann. Plast. Surg.*, 51(3):236-42, 2003.

Ziarah, H. A. & Atkinson, M. E. The surgical anatomy of the mandibular distribution of the facial nerve. *Br. J. Oral Surg.*, 19(3):159-70, 1981.

Correspondence to:  
Pedro Aravena  
Faculty of Medicine  
Universidad Austral de Chile  
Campus Isla Teja s/n Valdivia  
CHILE

Phone: 56-63-221205

Email: paravena@uach.cl

Recibido : 10-06-2013

Aceptado: 23-01-2014