

Morphological Analysis on the Occipital Condyles and Review of the Literature

Análisis Morfológico de los Cóndilos Occipitales y Revisión de la Literatura

José Aderval Aragão¹; Guilherme Machado de Santana²; Rebeca Zelice da Cruz de Moraes²;
Iapunira Catarina Sant'Anna Aragão³; Felipe Matheus Sant'Anna Aragão³ & Francisco Prado Reis⁴

ARAGÃO, J. A.; DE SANTANA, G. M.; DA CRUZ DE MORAES, R. Z.; ARAGÃO, I. C. S.; ARAGÃO, F. M. S.; REIS, P. F.
Morphological analysis on the occipital condyles and review of the literature. *Int. J. Morphol.*, 35(3):1129-1132, 2017.

SUMMARY: Most anatomical and biomechanical studies on the craniovertebral junction have involved morphological or morphometric analysis on the occipital condyles. Some of these studies have provided important findings based on different surgical procedures. The shape, size and angle of the occipital condyles and the locations of the intracranial and extracranial orifices of the hypoglossal canal are highly important because they may affect the lateral approaches to the craniovertebral junction. To determine the frequency of occurrence of different morphological types of occipital condyle. 214 occipital condyles in 107 dry human skulls were analyzed and the classification of their morphological types was determined through assessing digitized photographic images. Among the 107 skulls analyzed, 59.8 % were male and 40.2 % were female. Their ages ranged from 11 to 91 years, with a mean of 57.56 years. Of the total of 10 morphological types of occipital condyle that were found, more than 50 % were of the “8”, “S” and ring types. Condyles of “8” and “S” shape were the main types found in male skulls: the “8” shape prevailed on the left side and the “S” shape on the right side. However, in female skulls, these two types had equal bilateral distribution.

KEY WORDS: Skull; Occipital condyle; Atlanto-occipital joint; Surgical anatomy; Craniofacial abnormalities; Morphology; Occipital bone.

INTRODUCTION

Assessment and morphological analysis on the bones that make up the neurocranium and viscerocranium of the human skeleton are very important in forensic anthropology and play a significant role in investigations to estimate and determine the sex, age, ethnicity and height of unknown individuals (Kumar & Nagar, 2014).

The occipital condyles are anatomical structures that are located laterally to the foramen magnum of the occipital bone, at the external base of the skull (Kavitha *et al.*, 2013; Natsis *et al.*, 2013). These structures make a connection with the vertebral column through the atlanto-occipital joint (Kavitha *et al.*, Bayat *et al.*, 2014; Das *et al.*, 2006; Naderi *et al.*, 2005; Ozer *et al.*, 2011; Kizilkanat *et al.*, 2006). The integrity of the occipital condyles is very important for the

stability of the craniovertebral junction, such that variations in their shape, size and angle correspond equally to variations in the atlanto-occipital joint (Naderi *et al.*, Ozer *et al.*).

The occipital condyles have been described as bone structures with an oval outline that are arranged obliquely in such a way that the anterior extremity is more medial than the posterior extremity, thus presenting a convex anteroposterior surface (Kavitha *et al.*; Ozer *et al.*). The condylar canal is located posteriorly to the occipital condyles. In some cases, the occipital condyles may project significantly towards the foramen magnum (Muthukumar *et al.*, 2005). The canal of the hypoglossal nerve is located at the anterolateral margin of this foramen (Kizilkanat *et al.*).

¹ Associate Professor, Department of Morphology and the Postgraduate Applied Health Science Programs, Federal University of Sergipe (UFS), and Titular Professor of the Medical School, Tiradentes University (UNIT), Aracaju, Sergipe, Brazil.

² Medical student at the Federal University of Sergipe (UFS), Aracaju, Sergipe, Brazil.

³ Medical Student, University Center of Volta Redonda (UNIFOA), Volta Redonda, Rio de Janeiro, Brazil.

⁴ Titular Professor, Medical School of Tiradentes University (UNIT), Aracaju, Sergipe, Brazil.

There are several anatomical studies in the literature reporting the importance of morphometric variations of the occipital condyles (Kumar & Nagar, 2014, Kavitha *et al.*, Natsis *et al.*, Bayat *et al.*, Das *et al.*, Naderi *et al.*, Ozer *et al.*, Kizilkanat *et al.*, Muthukumar *et al.*, Avci *et al.*, 2011, Bozbug̃a *et al.*, 1999, Kalthur *et al.*, 2014, El-Gaidi *et al.*, 2014, Gapert *et al.*, 2009) and radiological studies have also been conducted (Avci *et al.*, Le *et al.*, 2011, Hong *et al.*, 2011, Noble & Smoker, 1996). Knowledge of the topography of different neurovascular structures located around the region of the occipital condyles is highly important with regard to conducting neurosurgical procedures (transcondylar approach) and obtaining good results. Notions of this knowledge should be one of the main issues to be analyzed during the preoperative decision-making process (Kumar & Nagar, Naderi *et al.*, Ozer *et al.*, Kizilkanat *et al.*, Avci *et al.*).

Most of the descriptions found in textbooks do not deal with anatomical variations of the occipital condyles (Gardner *et al.*, 1988; Hollinshead, 1991; Drake *et al.*, 2010; Moore *et al.*, 2011). This indicates that there is still a need for studies on the morphometric variations of the occipital condyles. The present study had the aim of determining the frequency of occurrence of different morphological types of occipital condyles.

MATERIAL AND METHOD

We analyzed 214 occipital condyles in dry human skulls belonging to the Forensic Anatomy and Anthropology Study and Research Center of Tiradentes University (UNIT), Aracaju, Sergipe, Brazil. Skulls that appeared to be complete in the region of the occipital condyles and which were identified regarding sex and age were analyzed. The classification of the morphological types of occipital condyles was determined through examining digitized photographic images that had been obtained using a digital camera (Sony DSLR-A100K) and had been save in JPEG format (Joint Photographic Experts Group). The present study was approved by the Research Ethics Committee of the Federal University of Sergipe, under protocol number 0357.0.107.000-11.

RESULTS

Among the 107 skulls that were analyzed in the present study, 64 (59.8 %) were male and 43 (40.2 %) were female. Their ages ranged from 11 to 91 years, with a mean of 57.56 years. The morphological types that were found are represented in Fig. 1 and their frequency of distribution according to sex is presented in Table I. It can be seen that the type in an “8” shape was most prevalent, followed by the “S” and ring types, and that condyles of irregular shape were least prevalent. Symmetrical and asymmetrical forms were found respectively in 26.2 % and 73.8 % of the skulls.

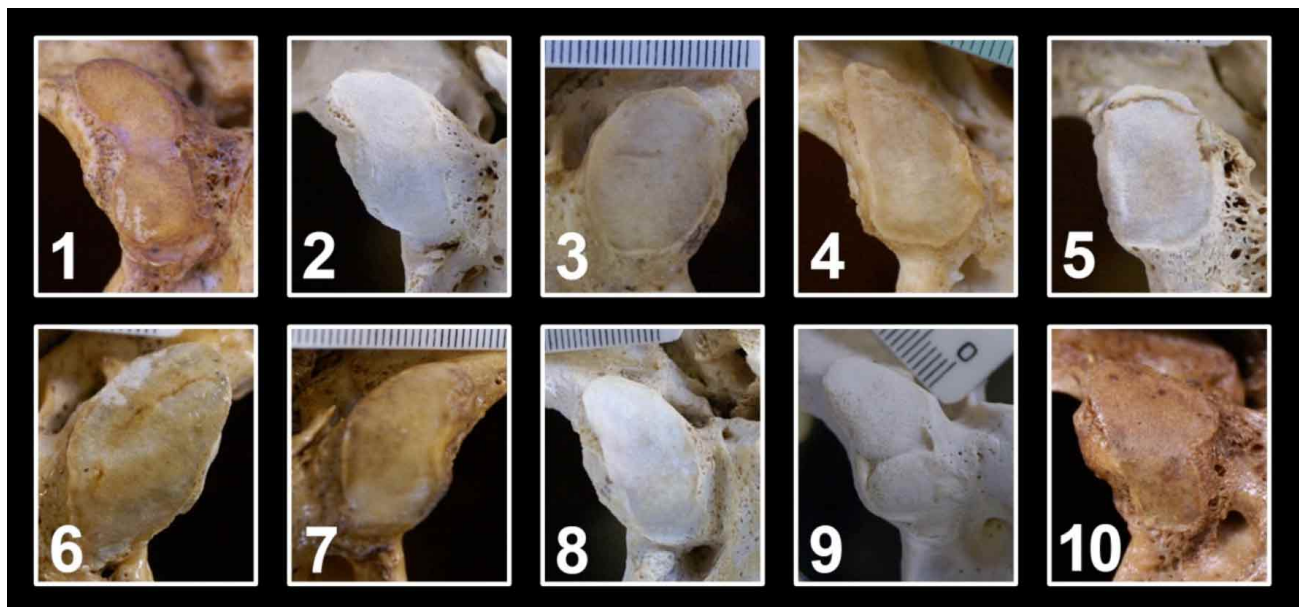


Fig. 1. Morphology of occipital condyles. 1) “8” shape, 2) “S” shape, 3) ring, 4) triangular, 5) quadrilateral, 6) biconvex, 7) reniform, 8) oval, 9) condyle in two parts, 10) irregular.

Table I. Distribution of different morphological types of occipital condyle, according to sex.

Morphological type	Sex								Total	
	Male				Female					
	Right		Left		Right		Left		n	%
	n	%	n	%	n	%	n	%	n	%
“8”	7	3.3	18	8.4	8	3.7	8	3.7	41	19.2
“S”	16	7.5	9	4.2	7	3.3	7	3.3	39	18.2
Ring	10	4.7	12	5.6	5	2.3	4	1.9	31	14.5
Triangular	3	1.4	5	2.3	7	3.3	5	2.3	20	9.3
Quadri lateral	4	1.9	6	2.8	1	0.5	7	3.3	18	8.4
Biconvex	7	3.3	4	1.9	4	1.9	2	0.9	17	7.9
Reniform	6	2.8	2	0.9	5	2.3	4	1.9	17	7.9
Oval	4	1.9	5	2.3	3	1.4	1	0.5	13	6.1
Condyle in two parts	5	2.3	3	1.4	1	0.5	1	0.5	10	4.7
Irregular	2	0.9	0	0.0	2	0.9	4	1.9	8	3.7
Total	64	29.9	64	29.9	43	20.1	43	20.1	214	100

Table II. Most frequent morphological types of occipital condyle in different studies.

Study	Morphological type	Population	%
Ozer <i>et al.</i>	Oval	Turkish	59.67
Fetouh &	Reniform	Egyptian	22
Naderi <i>et al.</i>	Oval	Turkish	50
Sinha <i>et al.</i>	S	Indian	25
Bayat <i>et al.</i>	Reniform	Iranian	34.4
Kalthur <i>et al.</i>	“8”	Indian	22.5
Natsis <i>et al.</i>	“S”	Greek	30.7
Present study	“8”	Brazilian	19.2

DISCUSSION

Several classifications have been created to define different morphological types of occipital condyle, but without determining the prevalence of each of these types (Bozbugã *et al.*; Olivier, 1975; Guidotti, 1984). Guidotti analyzed 741 skulls belonging to the Institute of Anatomy of the University of Siena and propose a classification of occipital condyles based on (1) division of their surface into planes; (2) partition without

interruption of the joint surface; (3) partition with an evident angle but without separation of the two surfaces; and (4) duplication of condyles. Bozbuga *et al.* classified occipital condyles as follows: (1) two forms of semicircle; (2) oval; (3) lozenge; (4) bean; (5) prismatic; (6) flattened; (7) convex; (8) flattened convex; (9) plane; (10) short and wide; (11) planar and long; and (12) small and convex.

Table II shows the variance and discordance regarding the morphological types of occipital condyles, along with their prevalence. From an analysis on skulls from the Turkish population, Ozer *et al.* and Naderi *et al.* concluded that occipital condyles of oval shape were the commonest. According to Sinha *et al.* (2014) and Natsis *et al.* the “S” shape was the main type. However, Bayat *et al.* and Fetouh & Awadalla (2009) reported that occipital condyles of reniform shape were most prevalent. In the present study, the main morphological type of occipital condyle was found to be the “8” shape. A similar finding was reported by Kalthur *et al.* from a study on individuals in the Indian population. A comparison of incidence rates among morphological types of occipital condyle reported by some authors is shown in Table III.

Table III. Morphological comparison of occipital condyles in various studies.

Authors	Shape of occipital condyles															
	n	1	2	3	4	5	6	7	8	9	10	11	12	13	14	15
		%														
Naderi <i>et al.</i>	404	50	3.5	23.2	4.2	9	4	0.8	5.5	-	-	-	-	-	-	-
Kalthur <i>et al.</i>	142	22.5	12	14.8	22.5	10.6	1.4	4.9	11.3	-	-	-	-	-	-	-
Ozer <i>et al.</i>	704	59.7	23	4	4.5	4.2	2.3	0.3	1.7	-	-	-	-	-	-	-
Fetouh & Awadalla	200	16	22	19	12	6	7	13	-	5	-	-	-	-	-	-
Bayat <i>et al.</i>	90	10	34.4	25.6	6.7	13.3	7.8	-	2.2	-	-	-	-	-	-	-
Sinha <i>et al.</i>	72	-	12.5	25	13.9	19.4	-	-	-	5.6	16	6.9	-	-	-	-
Kavitha <i>et al.</i>	290	30.7	-	-	-	-	-	-	-	-	-	-	30	-	31	7.9
Natsis <i>et al.</i>	286	7.6	6.2	30.7	12.6	16.2	4.4	16.6	5.8	-	-	-	-	-	-	-
Present study	214	6.1	7.9	18.2	19.2	9.3	14.5	4.7	-	8.4	3.7	-	-	7.9	-	-

1. oval; 2. reniform; 3. “S”; 4. “8”; 5. triangular; 6. ring; 7. condyle in two parts; 8. deformed; 9. quadri lateral; 10. irregular; 11. oval/ring; 12. oblong; 13. biconvex; 14. crescent; 15. lozenge.

CONCLUSIO. In the present study, occipital condyles of “8” and “S” shape were the main types found. Among the male skulls, the “8” shape was most prevalent on the right side, while the “S” shape was most prevalent on the right side. Among the female skulls, these two types had the same distribution bilaterally.

ARAGÃO, J. A.; DE SANTANA, G. M.; DA CRUZ DE MORAES, R. Z.; ARAGÃO, I. C. S.; ARAGÃO, F. M. S.; REIS, P. F. Análisis morfológico de los cóndilos occipitales. *Int. J. Morphol.*, 35(3):1129-1132, 2017.

RESUMEN: La mayor parte de los estudios anatómicos y biomecánicos de la unión cráneo-vertebral han sido realizados sobre el análisis morfológico o de la morfometría de los cóndilos occipitales. Algunos de estos trabajos tienen previsto importantes hallazgos basados en diferentes procedimientos quirúrgicos. De tal forma, el tamaño y ángulo del cóndilo occipital bien como su localización de los orificios intracraneales y extracraneales del canal hipogloso son de gran importancia, ya que pueden afectar a los enfoques laterales de la unión cráneo-vertebral. El objetivo del estudio fue determinar la prevalencia de los tipos morfológicos de cóndilos occipitales. Fueron analizados 214 cóndilos de 107 cráneos secos de humanos y la clasificación de los tipos morfológicos fue determinada a partir de los análisis de estudio de imágenes fotográficas digitalizadas. De los 107 cráneos que fueron analizados, 59,8 % eran de sexo masculino y 40,2 % de sexo femenino, cuyas edades comprendidas entre 11 y 91 años con una media de 57.56 años. De un total de 10 tipos morfológicos de los cóndilos occipitales encontrados, más del 50 % eran de tipo ocho, S y anillo. Los cóndilos en forma de “8” y “S” fueron los principales tipos encontrados, en el sexo masculino, la forma en “8” prevaleció en el lado izquierdo, y el tipo morfológico en “S”, en el lado derecho del cráneo. Mientras que en el sexo femenino esos dos tipos tuvieron una equitativa distribución bilateral.

PALABRAS CLAVE: Cráneo; Cóndilo occipital; Articulación atlanto-occipital; Anatomía quirúrgica; Anomalías craneofaciales; Morfología; Hueso occipital.

REFERENCES

Avcı, E.; Dagtekin, A.; Ozturk, A. H.; Kara, E.; Ozturk, N. C.; Uluc, K.; Akture, E., & Baskaya, M. K. Anatomical variations of the foramen magnum, occipital condyle and jugular tubercle. *Turk. Neurosurg.*, 21(2):181-90, 2011.

Bayat, P.; Bagheri, M.; Ghanbari, A. & Raoofi, A. Characterization of occipital condyle and comparison of its dimensions with head and foramen magnum circumferences in dry skulls of Iran. *Int. J. Morphol.*, 32(2):444-8, 2014.

Bozbug̃a, M.; Oztürk, A.; Bayraktar, B.; Ari, Z.; Sahinog̃lu, K.; Polat, G. & Gürel, I. Surgical anatomy and morphometric analysis of the occipital condyles and foramen magnum. *Okajimas Folia Anat. Jpn.*, 75(6):329-34, 1999.

Das, S.; Suri, R. & Kapur, V. Unusual occipital condyles of the skull: an osteological study with clinical implications. *São Paulo Med. J.*, 124(5):278-9, 2006.

Drake, R. L.; Vogl, A. W. & Mitchell, A. *Gray's Anatomia para Estudantes*. 2nd ed. Rio de Janeiro, Elsevier, 2010.

El-Gaidi, M. A.; Eissa, E. M. & El-Shaarawy, E. A. Free-hand placement of occipital condyle screws: a cadaveric study. *Eur. Spine J.*, 23(10):2182-8, 2014.

Fetouh, F. & Awadalla, A. Morphometric analysis of the occipital condyle and its surgical implications in transcondylar approach. *Skull Base*, 19:A023, 2009.

Gapert, R.; Black, S. & Last, J. Sex determination from the occipital condyle: discriminant function analysis in an eighteenth and nineteenth century British sample. *Am. J. Phys. Anthropol.*, 138(4):384-94, 2009.

Gardner, E.; Gray, D. J. & O' Rahilly, R. *Anatomy: A Regional Study of Human Structure*. 4th ed. Rio de Janeiro, W. B. Saunders, 1988.

Guidotti, A. Morphometrical considerations on occipital condyles. *Anthropol. Anz.*, 42(2):117-9, 1984.

Hollinshead, W. H. *Anatomia Humana*. 4th ed. Rio de Janeiro, Interlivros, 1991.

Hong, J. T.; Takigawa, T.; Sugisaki, K.; Espinoza Orías, A. A.; Inoue, N. & An, H. S. Biomechanical and morphometric evaluation of occipital condyle for occipitocervical segmental fixation. *Neurol. Med. Chir. (Tokyo)*, 51(10):701-6, 2011.

Kalthur, S. G.; Padmashali, S.; Gupta, C. & Dsouza, A. S. Anatomic study of the occipital condyle and its surgical implications in transcondylar approach. *J. Craniovertebr. Junction Spine*, 5(2):71-7, 2014.

Kavitha, S.; Chandrasekaran, S.; Anand, A. & Shanthi, K. C. Morphometric study of occipital condyles in adult human skulls. *I. J. C. R. R.*, 5(15):31-4, 2013.

Kizilkanat, E. D.; Boyan, N.; Soames, R. & Oguz, O. Morphometry of the hypoglossal canal, occipital condyle, and foramen magnum. *Neurosurg. Q.*, 16(3):121-5, 2006.

Kumar, A. & Nagar, M. Human adult occipital condyles: A morphometric analysis. *Res. Rev. J. Med. Health Sci.*, 3(4):112-6, 2014.

Le, T. V.; Dakwar, E.; Hann, S.; Effio, E.; Baaj, A. A.; Martinez, C.; Vale, F. L. & Uribe, J. S. Computed tomography-based morphometric analysis of the human occipital condyle for occipital condyle-cervical fusion. *J. Neurosurg. Spine*, 15(3):328-31, 2011.

Moore, K. L.; Dalley, A. F. & Agur, A. M. R. *Anatomia Orientada para a Clínica*. 6ª ed. Rio de Janeiro, Guanabara Koogan, 2011.

Muthukumar, N.; Swaminathan, R.; Venkatesh, G. & Bhanumathy, S. P. A morphometric analysis of the foramen magnum region as it relates to the transcondylar approach. *Acta Neurochir. (Wien)*, 147(8):889-95, 2005.

Naderi, S.; Korman, E.; Citak, G.; Güvençer, M.; Arman, C.; Senog̃lu, M.; Tetik, S. & Arda, M. N. Morphometric analysis of human occipital condyle. *Clin. Neurol. Neurosurg.*, 107(3):191-9, 2005.

Natsis, K.; Piagkou, M.; Skotsimara, G.; Piagkos, G. & Skandalakis, P. A morphometric anatomical and comparative study of the foramen magnum region in a Greek population. *Surg. Radiol. Anat.*, 35(10):925-34, 2013.

Noble, E. R. & Smoker, W. R. The forgotten condyle: the appearance, morphology, and classification of occipital condyle fractures. *Am. J. N. R. Am. J. Neuroradiol.*, 17(3):507-13, 1996.

Olivier, G. Biometry of the human occipital bone. *J. Anat.*, 120(Pt.3):507-18, 1975.

Ozer, M. A.; Celik, S.; Govsa, F. & Ulusoy, M. O. Anatomical determination of a safe entry point for occipital condyle screw using three-dimensional landmarks. *Eur. Spine J.*, 20(9):1510-7, 2011.

Sinha, M. B.; Trivedi, S.; Siddiqui, A. U. & Rathore, M. Occipital condyle and its relevance during surgery. *N. J. C. A.*, 3(4):209-4, 2014.

Corresponding author:

José Aderval Aragão
Rua Aloisio Campos 500
Bairro Atalaia
Aracaju, Sergipe
CEP: 49035-020
BRAZIL

Received: 12-04-2017
Accepted: 25-07-2017

E-mail: jaafelipe@infonet.com.br