

# Three-dimensional Analysis of Nasolabial Soft Tissues While Smiling Using stereophotogrammetry (3dMDTM)

## Análisis Tridimensional de los Tejidos Blandos Nasolabiales en Sonrisa Utilizando Estereofotogrametría (3dMDTM)

Marcelo Parra<sup>1,2,3</sup>; Ricardo Pardo<sup>2</sup>; Ziyad S. Haidar<sup>4,5</sup>; Juan Pablo Alister<sup>2</sup>; Francisca Uribe<sup>2,6</sup> & Sergio Olate<sup>1,2,3</sup>

PARRA, M.; PARDO, R.; HAIDAR, Z. S.; ALISTER, J. P.; URIBE, F. & OLATE, S. Three-dimensional analysis of nasolabial soft tissue while smiling using stereophotogrammetry (3dMDTM). *Int. J. Morphol.*, 37(1):232-236, 2019.

**SUMMARY:** The nasolabial region is the central esthetic unit of the face and is considered one of the most important determinants of the facial esthetic. The facial morphometry of soft tissues is a very important tool in facial surgery. Advances have been made recently in the capture and analysis of 3D images, which offer great development potential in the diagnosis and treatment of facial deformities. The aim of this study was to characterize the nasolabial region of patient candidates for orthognathic surgery using 3D facial captures. A study was conducted to characterize the width of the nasal base and the nasolabial angle in adult patients through 3D photographs. 30 subjects were included, taking two 3D photos each, one in a resting position and the other smiling. The three-dimensional capture was done with the 3dMDface System. The measurements were taken with the 3dMD Vultus software. The length of the alar base was an average of  $34.3 \pm 2.6$  mm at rest, and  $39.1 \pm 2.9$  mm smiling. The mean of the nasolabial angle was  $104.6 \pm 9.6^\circ$  at rest and  $105.4 \pm 14.3^\circ$  smiling. Additionally, the distance of the alar base smiling compared to its distance at rest increased an average of 4.83 mm, whereas the nasolabial angle smiling increased an average of  $0.8^\circ$  compared to at rest. In this study, the nasolabial angle did not present any significant changes so that its assessments in the case of facial modifications can be standard; the width of the nasal base is significantly modified with the smile and thus a more intense study of any type of modification in this area is required.

**KEY WORDS:** 3D analysis; 3dMD; Facial morphology.

## INTRODUCTION

The nasolabial region is the central esthetic unit of the face and is considered one of the most important determinants of the facial esthetic (Jang *et al.*, 2017). In order to obtain a good functional, esthetic and predictable outcome, it is crucial that the surgical effects on the soft and hard tissues be understood (Hellak *et al.*, 2015). Pre-surgical planning focuses on the initial stability of the facial tissues, so the static condition is one of the parameters included, whereas the dynamic position of facial tissues can bring about changes in the results of facial proportion and normality. To this end, the use of new tools that can analyze facial soft tissues in static and dynamic phases is critical (Yashwant *et al.*, 2016).

Direct anthropometry has been considered the criterion of reference to assess facial soft tissues (Cagle &

Stephan, 2016); however, it has certain disadvantages: 1) increased clinical time and 2) difficulty and bias o position the markers, among others. In this sense, the use of 2D photos has been used to provide measurements (Muradin *et al.*, 2007), although its disadvantages include limitation to one facial area, inaccuracies related to the adjustment of the equipment, problems related to the position of the patient and difficult metric measurements according to the capture and quality of the image (Olate *et al.*, 2015).

To offset these drawbacks, advances have been made in the capture and analysis of digital 3D photos, also known as stereophotogrammetry, which offers great development potential in the diagnosis and treatment of facial deformities (Zogheib *et al.*, 2018). These captures can analyze facial morphology and thus craniofacial growth, changes in soft

<sup>1</sup> Programa de Doctorado en Ciencias Morfológicas, Universidad de La Frontera, Temuco, Chile.

<sup>2</sup> Division of Oral, Facial and Maxillofacial Surgery, Universidad de La Frontera, Temuco, Chile.

<sup>3</sup> Center of Excellence in Morphological and Surgical Studies (CEMyQ), Universidad de La Frontera, Temuco, Chile.

<sup>4</sup> BioMATX , Faculty of Dentistry, Universidad de Los Andes, Santiago de Chile.

<sup>5</sup> Center for Biomedical Research and Innovation (CIIB), Faculty of Medicine, University of Los Andes, Santiago, Chile.

<sup>6</sup> Programa de Doctorado en Cs. Médicas, Universidad de La Frontera, Temuco, Chile.

tissues after facial surgery, planning studies and digital surgical simulation, among others (Vittert *et al.*, 2018). Considering that facial analyses using 3D technology are in the early stages, the aim of this work was to characterize the nasolabial region using 3D facial captures, specifically the width of the alar base and the value of the nasolabial angle in a static and dynamic position.

## MATERIAL AND METHOD

A descriptive study was conducted to analyze facial morphology through 3D photos of adult subjects who consulted in the Oral, Facial and Maxillofacial Surgery Division of Universidad de La Frontera, Temuco, Chile. A sampling by convenience was used that included 30 candidates for orthognathic or facial surgery, taking linear morphometry of the width of the nasal base and the nasolabial angle both in static and dynamic (smile) position.

**Inclusion and exclusion criteria.** The inclusion criteria were: i) initial consultation in the Division of Oral, Facial and Maxillofacial Surgery, Universidad de La Frontera, ii) male or female subjects between 18 and 60 years and candidates for orthognathic surgery, and iii) subjects who signed the informed consent to participate in the study. Subjects with facial tumors, facial trauma or other facial

pathologies that could modify the facial soft tissue characteristics were excluded.

### Photo capture and analysis in Vultus 3dMD software.

The 3D capture was done using the 3dMDface System (3dMDTM), which consists of two modular units of six cameras and an industrial grade flash system synchronized in a single capture, which automatically generates a continuous 3D polygonal surface mesh with a single system of x, y, z coordinates. This enables a facial capture of 180 degrees, with an ultrafast capture of 1.5 milliseconds and a 3D image rendering speed of 7 seconds.

The subject was positioned in front of the camera, approximately 60 cm from the central point of the recording monitor, with the bipupilar plane parallel to the floor and vision oriented to the horizon (Fig. 1). The subject was positioned with help from an experienced investigator previously trained for this process.

The measurements were taken by two calibrated researchers (MP and RP) with the 3dMD Vultus software. In each photograph, the length of the alar base of the nose, defined as the distance between the most external points of each nasal ala, was evaluated using the option of distance between points (Fig. 2). Then the value of the nasolabial angle was determined, formed by the join of the columella, subnasale and edge of the upper lip.

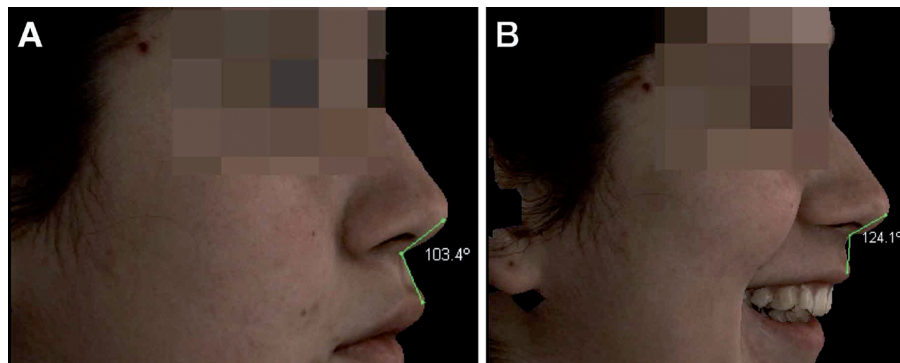


Fig. 1. Images obtained for comparative morphometry in nasolabial angle at rest and smiling.

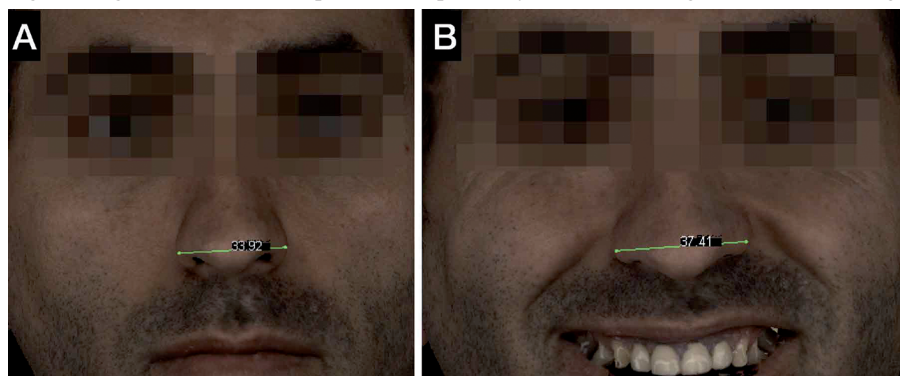


Fig. 2. Images obtained for comparative morphometry of alar base width at rest and smiling.

**Data analysis.** The data were recorded on a Microsoft Excel® spreadsheet. For the data analysis the GraphPad Prism (version 5.0®, San Diego, USA) statistics program was used, and a descriptive analysis was performed on the data as well as the Shapiro-Wilk test of normality; the Mann-Whitney U test and the t-test for related samples were used with a value of  $p < 0.05$  to obtain statistical significance, considering 95 % confidence intervals of reliability.

## RESULTS

Thirty subjects were included in this study (9 males and 21 female), with an age from 18 to 41 years. The measurements were taken independently by two operators, obtaining an intraclass correlation coefficient of 0.85, confirming the viability of the measurements.

Tables I and II show the results obtained in the study, being the alar base length and the nasolabial angle, considering the normal position and the smiling movement. The alar base length was an average of  $34.3 \pm 2.6$  mm at rest, and  $39.1 \pm 2.9$  mm smiling. The mean of the nasolabial angle was  $104.6 \pm 9.6^\circ$  at rest and  $105.4 \pm 14.3^\circ$  smiling. The distance of the alar base smiling compared to its distance at rest increased an average of 4.83 mm, while the nasolabial angle smiling increased an average of  $0.8^\circ$  compared to at rest.

To compare the measurements at rest versus smiling, the Mann-Whitney U test showed statistically significant differences in the distance of the alar base between the two positions ( $p=0.0001$ ). The t-test for related samples indicated no statistically significant differences in the nasolabial angle measurement ( $p=0.7$ ).

Table I. Description of the morphometric analyses of the nasolabial area at rest and smiling in the 30 subjects included.

Subject	Sex	Alar base length at rest (mm)	Alar base length smiling (mm)	Nasolabial angle at rest	Nasolabial angle smiling
1	F	34.2	38.1	98.7°	107.4°
2	F	34.3	37.1	105.4°	110.7°
3	M	33.3	38.9	101.6°	100.8°
4	F	34.3	39.1	100.4°	90.7°
5	M	35	39.7	129.3°	128.7°
6	F	36.3	39.1	95°	115.4°
7	F	31.7	36.9	94.3°	107°
8	F	35	38.2	102.6°	98.4°
9	F	32.2	35.2	107.1°	96.7°
10	F	35	39.7	106.8°	118.6°
11	M	42.6	47.3	99.9°	86°
12	M	39.1	44.4	99.6°	98.1°
13	F	34.6	36.4	88.2°	80.7°
14	F	35.6	39.3	88.7°	99.7°
15	F	33.6	37.6	112.8°	115.7°
16	F	35.6	39.9	111.9°	100.8°
17	M	39.8	43.3	101°	112.5°
18	F	32.5	37	107.8°	103.4°
19	F	31.9	37.8	109.2°	110.5°
20	F	30.2	38.9	101.9°	73.8°
21	F	31.3	34.2	102.3°	98.6°
22	F	32	37.9	98.2°	104.1°
23	F	32.9	35.9	113.6°	104.2°
24	M	33	41.2	114.3°	106.7°
25	F	31.6	33.9	127.4°	145.6°
26	F	34.8	39.7	98.7°	108.6°
27	F	33.1	40.8	111.2°	104.1°
28	M	35.4	42.6	90.9°	98°
29	F	33.1	40.9	107.5°	132.2°
30	M	35.1	43	111.1°	103.7°

Table II. Distribution of results observed in the sample of 30 subjects included in this research.

Measurement	Minimum	Maximum	Mean	Standard deviation	Median	Average difference	p-value
Alar base width at rest (mm)	30.2	42.6	34.3	2.6	34.2	4.83	0.0001* (a)
Alar base width smiling (mm)	33.9	47.3	39.1	2.9	39		
Nasolabial angle at rest (°)	88.2	129.3	104.6	9.6	102.5	0.8	0.7 (b)
Nasolabial angle smiling (°)	73.8	145.6	105.4	14.3	104.1		

(a) Mann-Whitney U Test; (b) T-test for related samples; (\*) statistically significant

## DISCUSSION

3D facial photography or stereophotogrammetry is a noninvasive method to obtain a highly accurate three-dimensional reproduction of the facial structures (Olate *et al.*, 2017). Analysis with this 3D technology has yielded good initial results, and is an important focus on the current development of facial morphology with a clinical application (Schendel *et al.*, 2013). Achieving accuracy is complex, where 3D technology enables better approaches (Fischl *et al.*, 1999). In this sense, the 3dMD facial system has a precision with an average error less than 0.2 mm, which makes the data reliable.

The methodology used to conduct three-dimensional studies of the facial morphology has been unclear. Almeida *et al.* (2011) studied the areas of the chin and lower lip with computed tomography; Schendel *et al.*, using stereophotogrammetry, performed an analysis, identifying 26 facial points, obtaining variable results with limitations in the definition of normality and variation; Yuan *et al.* (2013), on the other hand, used a laser scanner to define the facial morphology. In a recent systematic review, Olate *et al.* (2017) demonstrated the poor scientific data with respect to the 3D facial morphology analyses and the limited results in their clinical application in the field of facial modifications.

Zhao *et al.* (2017) compared the accuracy between different 3D facial photography capture in subjects with facial deformities. They concluded that 3D precision of the different facial segments is inconsistent in subjects with facial deformities, and the best results in terms of accuracy were observed in the midfacial segment. The patients included in this study were candidates for orthognathic surgery, where the nasolabial conditions were evaluated to orient therapeutic decision-making, demonstrating significant changes in the position of the alar base when smiling, which confirms the effect of muscle dynamics.

Modifications of the nasolabial angle determine the esthetic assessment of the area (van Loon *et al.*, 2015). Ohba *et al.* (2017), in a study of subjects with a class III facial deformity who underwent orthognathic surgery, found that a greater mandibular retrusion in the postoperative stage is

associated with a greater nasolabial angle. For their part, Tiwari *et al.* (2018), analyzing 3D photos obtained 12 months after orthognathic surgery, showed a relation between 1 mm of maxillary advancement with increase in average of 1.81° in the nasolabial angle and between 1 mm of maxillary regression related to a decrease of 2.73° in this angle. Han & Lee (2018), in a retrospective study where they analyzed patients who underwent orthognathic surgery, reported a direct relation between the rotation of the occlusal plane and the nasolabial angle, considering that for every degree of clockwise rotation of the occlusal plane, there is an average increase of 1.35° in the nasolabial angle. Labial dynamics were not assessed in these studies, determining that most of these relations are established at rest and not smiling.

Smile dynamics are linked to factors like central incisor positions, capacity for mobility of the upper lip, increases in overjet and overbite (Peck *et al.*, 1992; Barbosa *et al.*, 2016); other investigations have also demonstrated that the position of the lower lip affects the position of the upper lip (Olate *et al.*, 2016), so that there are variables that have not been fully identified and quantified in the smiling condition; our results show that there are no statistically significant differences in the value of the nasolabial angle when being evaluated at rest and smiling with only 0.8° of difference. Although the depressor muscle of the nasal septum is one of the important ones responsible in this dynamic for the descent of the nasal tip and for decreasing the nasolabial angle, it is possible that in this sample there is no significant alteration in the action of this muscle either in its morphology or in its interaction with other muscles such as the orbicularis oris of the lips.

On the other hand, cross-sectionally there are positional changes in the nasal ala that vary 4.83 mm from the resting position, indicating the action of the muscles involved in smiling. In this sense, the smile assessed as attractive surrounds the contraction of the major zygomaticus muscle in combination with the orbicularis oculi (Lin *et al.*, 2013), which may explain the significant increase in interalar distance of this area during the muscle action. Recent studies have indicated that the smile is a highly valuable component in the facial esthetic (Patusco *et al.*, 2018) and this value is reduced when there is an increase in the width of the alar base; accordingly, the inclusion of different areas involved in the smile, such as lips, nose and

eyes, renders the segmentation of subunits in these analyses complex, such that new studies must be conducted to assess the facial subunits and their effect on the smile and facial expression.

Facial analyses with digital 3D photos have improved some of the difficulties observed in 2D analyses; however, 3D analyses are not free of bias, mainly due to the points having to be located with a cursor, which continues to be operator-dependent (Olate *et al.*, 2017). In this study, the nasolabial angle does not present significant changes; therefore, its assessment in the event of facial modifications can be standard in both scenarios. The width of the nasal base is significantly modified with the smile and thus a more intense study of any type of modification in this area is required.

**PARRA, M.; PARDO, R.; HAIDAR, Z. S.; ALISTER, J. P.; URIBE, F.; OLATE, S.** Análisis tridimensional de los tejidos blandos nasolabiales en sonrisa utilizando estereofotogrametría (3dMDTM). *Int. J. Morphol.*, 37(1):232-236, 2019

**RESUMEN:** La región nasolabial es la unidad estética central de la cara y se considera uno de los determinantes más importantes de la estética facial. La morfometría facial en tejidos blandos, es una herramienta de gran importancia en Cirugía Facial. En el último tiempo, se han realizado avances en captura y análisis de imágenes 3D, las cuales ofrecen un gran potencial de desarrollo en el diagnóstico y tratamiento de las deformidades faciales. El objetivo de este trabajo fue caracterizar mediante capturas faciales 3D la región nasolabial de pacientes candidatos a cirugía ortognática. Se realizó un estudio para caracterizar a través de fotografías tridimensionales de pacientes adultos el ancho de la base nasal y el ángulo nasolabial. Se incluyeron 30 sujetos, tomando 2 fotografías 3D a cada uno, una en posición de reposo y otra en sonrisa. Se realizó la captura tridimensional con la cámara facial 3dMDface System. Las mediciones fueron realizadas con el software 3dMD Vultus. La longitud de base alar en reposo, fue en promedio de  $34,3 \pm 2,6$  mm, y de  $39,1 \pm 2,9$  mm, en sonrisa. Por otra parte, la media del ángulo nasolabial en reposo fue de  $104,6 \pm 9,6^\circ$  y en sonrisa, de  $105,4 \pm 14,3^\circ$ . Por otro lado, la distancia de la base alar en sonrisa respecto a su distancia en reposo, aumentó un promedio de 4,83 mm, mientras que el ángulo nasolabial en sonrisa, aumentó en promedio  $0,8^\circ$  respecto a la posición de reposo. En esta investigación, el ángulo nasolabial no presentó cambios significativos de forma que su valoración frente a modificaciones faciales puede ser estándar; el ancho de base nasal se modifica significativamente con la sonrisa de forma que su estudio debe ser más agudo frente a cualquier tipo de modificación en esta zona.

**PALABRAS CLAVE:** 3D analysis; 3dMD; Facial morphology.

## REFERENCES

Almeida, R. C.; Cevidanes, L. H.; Carvalho, F. A.; Motta, A. T.; Almeida, M. A.; Styner, M.; Turvey, T.; Proffit, W. R. & Phillips, C. Soft tissue response to mandibular advancement using 3D CBCT scanning. *Int. J. Oral Maxillofac. Surg.*, 40(4):353-9, 2011.

Barbosa, D. M.; Bernal, L. V.; Zapata, O. A.; Agudelo-Suárez, A.; Angel, L.; Estrada, F. & Suárez, J. Influence of facial and occlusal characteristics on gummy smile in children: a case-control study. *Pesq. Bras. Odontopediatria Clin. Integr.*, 16(1):25-34, 2016.

Caple, J. & Stephan, C. N. A standardized nomenclature for craniofacial and facial anthropometry. *Int. J. Legal Med.*, 130(3):863-79, 2016.

Fischl, B.; Sereno, M. I.; Tootell, R. B. & Dale, A. M. High-resolution intersubject averaging and a coordinate system for the cortical surface. *Hum. Brain Mapp.*, 8(4):272-84, 1999.

Han, Y. S. & Lee, H. The influential bony factors and vectors for predicting soft tissue responses after orthognathic surgery in mandibular prognathism. *J. Oral Maxillofac. Surg.*, 76(5):1095.e1-1095.e14, 2018.

Hellak, A. F.; Kirsten, B.; Schauseil, M.; Davids, R.; Kater, W. M. & Korbmacher-Steiner, H. M. Influence of maxillary advancement surgery on skeletal and soft-tissue changes in the nose - a retrospective cone-beam computed tomography study. *Head Face Med.*, 9, 11:23, 2015.

Jang, K. S.; Bayome, M.; Park, J. H.; Park, K. H.; Moon, H. B. & Kook, Y. A. A three-dimensional photogrammetric analysis of the facial esthetics of the Miss Korea pageant contestants. *Korean J. Orthod.*, 47(2):87-99, 2017.

Lin, A. I.; Braun, T.; McNamara, J. A. Jr. & Gerstner, G. E. Esthetic evaluation of dynamic smiles with attention to facial muscle activity. *Am. J. Orthod. Dentofacial Orthop.*, 143(6):819-27, 2013.

Muradin, M. S.; Rosenberg, A.; van der Bilt, A.; Stoelinga, P. J. & Koole, R. The reliability of frontal facial photographs to assess changes in nasolabial soft tissues. *Int. J. Oral Maxillofac. Surg.*, 36(8):728-34, 2007.

Ohba, S.; Kohara, H.; Koga, T.; Kawasaki, T.; Miura, K. I.; Yoshida, N. & Asahina, I. Soft tissue changes after a mandibular osteotomy for symmetric skeletal class III malocclusion. *Odontology*, 105(3):375-81, 2017.

Olate, S.; Cantín, M.; Vásquez, B.; Muñoz, M. & de Moraes, M. 2D photography in facial asymmetry diagnosis. *Int. J. Morphol.*, 33(4):1483-6, 2015.

Olate, S.; Zaror, C. & Mommaerts, M. Y. A systematic review of soft-to-hard tissue ratios in orthognathic surgery. Part IV: 3D analysis - Is there evidence? *J. Craniomaxillofac. Surg.*, 45(8):1278-86, 2017.

Olate, S.; Zaror, C.; Blythe, J. N. & Mommaerts, M. Y. A systematic review of soft-to-hard tissue ratios in orthognathic surgery. Part III: Double jaw surgery procedures. *J. Craniomaxillofac. Surg.*, 44(10):1599-606, 2016.

Patusco, V.; Carvalho, C. K.; Lenza, M. A. & Faber, J. Smile prevails over other facial components of male facial esthetics. *J. Am. Dent. Assoc.*, 149(8):680-7, 2018.

Peck, S.; Peck, L. & Kataja, M. The gingival smile line. *Angle Orthod.*, 62(2):91-100, 1992.

Schendel, S. A.; Jacobson, R. & Khalessi, S. 3-dimensional facial simulation in orthognathic surgery: is it accurate? *J. Oral Maxillofac. Surg.*, 71(8):1406-14, 2013.

Tiwari, R.; Chakravarthi, P. S.; Kattimani, V. S. & Lingamaneni, K. P. A perioral soft tissue evaluation after orthognathic surgery using three-dimensional computed tomography scan. *Open Dent. J.*, 12:366-76, 2018.

van Loon, B.; van Heerbeek, N.; Bierenbroodspot, F.; Verhamme, L.; Xi, T.; de Koning, M. J.; Ingles, K. J.; Bergé, S. J. & Mall, T. J. Three-dimensional changes in nose and upper lip volume after orthognathic surgery. *Int. J. Oral Maxillofac. Surg.*, 44(1):83-9, 2015.

Vittert, L.; Katina, S.; Ayoub, A.; Khambay, B. & Bowman, A. W. Assessing the outcome of orthognathic surgery by three-dimensional soft tissue analysis. *Int. J. Oral Maxillofac. Surg.*, 47(12):1587-95, 2018.

Yashwant, V. A.; K. R. & Arumugam, E. Comparative evaluation of soft tissue changes in Class I borderline patients treated with extraction and nonextraction modalities. *Dental Press J. Orthod.*, 21(4):50-9, 2016.

Yuan, L.; Shen, G.; Wu, Y.; Jiang, L.; Yang, Z.; Liu, J.; Mao, L. & Fang, B. Three-dimensional analysis of soft tissue changes in full-face view after surgical correction of skeletal class III malocclusion. *J. Craniofac. Surg.*, 24(3):725-30, 2013.

Zogheib, T.; Jacobs, R.; Bornstein, M. M.; Agbaje, J. O.; Anumendem, D.; Klazen, Y. & Politis, C. Comparison of 3D Scanning Versus 2D Photography for the Identification of Facial Soft-Tissue Landmarks. *Open Dent. J.*, 12:61-71, 2018.

Correspondence author:

Dr. Sergio Olate  
Facultad de Odontología  
Universidad de La Frontera  
Claro Solar 115, Oficina 414  
Temuco  
CHILE

Received: 10-09-2018  
Accepted: 20-12-2018

Email: sergio.olate@ufrontera.cl