

Prevalence of Radix Entomolaris in Mandibular First Molars by Cone-Beam Computed Tomography in a Southern Chilean Sub-Population

Prevalencia de Radix Entomolaris en Primeros Molares Mandibulares Usando Tomografía Computarizada Cone-Beam en una Subpoblación del Sur de Chile

Pablo Betancourt^{1,2}; Alain Arias^{2,3}; Daniela Matus^{1,2}; Pablo Navarro^{2,4}; Ivonne Garay¹ & Ramón Fuentes^{1,2}

BETANCOURT, P.; ARIAS, A.; MATUS, D.; NAVARRO, P.; GARAY, I. & FUENTES, R. Prevalence of radix entomolaris in mandibular first molars by Cone-Beam Computed Tomography in a Southern Chilean sub-population. *Int. J. Morphol.*, 40(2):414-419, 2022.

SUMMARY: The aim of this study was to evaluate the prevalence and morphology of radix entomolaris (RE) in the mandibular first molar (MFM) in a southern Chilean sub-population by cone-beam computed tomography (CBCT). Two hundred ten CBCT images of MFM were analysed. To detect the presence of RE, the observation and measurements were standardised, advancing 1 mm to apical from the floor of the pulp chamber to the most apical zone of the tooth. The data were analyzed using descriptive statistics, with a value of $P < 0.05$ being statistically significant. The prevalence of a third root in the permanent MFM was 5.7 % (12/210). The incidence of RE was the same in male patients (2.9 %) as in female patients (2.9 %) ($p=0.324$). The occurrence of an RE in the left MFM was 7.3 % (3/41 patients) for male patients and 4.5 % (3/66) for female patients ($p=0.398$). The right MFM in male patients had an incidence of 8.1 % (3/37) and 4.5 % (3/66) for female patients ($p=0.340$). When the presence of an RE was compared between the left (5.6 %) and right side (5.8 %), no statistically significant differences were found ($p=0.998$). The frequency of bilateral three-rooted MFM was 71.43 % (5/7) and 28.57 % (2/7) were unilateral. The prevalence of RE in MFM in a southern Chilean sub-population was 5.7 %. The occurrence was bilateral in the majority of cases and no significant differences were observed by sex or side. The commonest type of RE was Type 1 (83.3 %). The use of CBCT can improve the endodontic treatment outcome.

KEY WORDS: Radix entomolaris; Mandibular First Molar; Cone-Beam Tomography; Morphology.

INTRODUCTION

Knowledge of dental morphology, including variant forms, is fundamental for successful endodontic treatment (Tu *et al.*, 2009). The permanent mandibular first molar (MFM) habitually presents 2 well-defined roots: one mesial characterised by a flattened mesiodistal surface and a widened buccolingual surface; and one distal, in the majority of cases with a broad oval canal or 2 round canals (Vertucci, 1984). However, some variations have been reported in the number of roots present. The principal variant described is the presence of a third accessory root on the lingual face of the tooth, called radix entomolaris (RE) (Bolk, 1915). RE is a supernumerary distolingual root (DL), located lingual

respect to the distobuccal root (DB). It is generally shorter than DB root (Calberson *et al.*, 2007) and it may be totally separated from the DB root or fused with it (Carlsen & Alexandersen, 1990).

Failure to identify RE in clinical practice will prevent correct cleaning and disinfection of the root canal system, resulting in a poor endodontic prognosis. Furthermore, biomechanical instrumentation of the RE presents a challenge for the clinician, as it normally presents different degrees of curvature, most frequently to vestibulo-lingual (Abella *et al.*, 2012). Based on the degree of curvature, De

¹ Department of Integral Adult Dentistry, Dental School, Universidad de La Frontera, Temuco, Chile.

² Center for Research in Dental Sciences (CICO), Endodontic Laboratory, Universidad de La Frontera, Temuco, Chile

³ Universidad Adventista de Chile, Chillán, Chile.

⁴ Universidad Autónoma de Chile, Chile.

The authors are grateful for DIUFRO project DI21-0034. This project was partially funded by the Research Directorate of Universidad de La Frontera.

Moor *et al.* (2004) suggested a classification with three different types of RE: Type 1: a straight root; Type 2: a curve in the coronal third and straight thereafter; and Type 3: an initial curve in the coronal third of the root canal and a second curve beginning in the middle and continuing to the apical third.

The appearance of this extra root varies according to the study population. A frequency of less than 5 % has been reported in Caucasian, African, Eurasian and Indian populations, while in those with Mongoloid features, such as Chinese, Eskimo and native American populations, the frequency of RE varies from 5 % to 40 % (Gulabivala *et al.*, 2001; De Moor *et al.*; Tu *et al.*, 2007; Chen *et al.*, 2009; Huang *et al.*, 2010).

In recent years, cone-beam computed tomography (CBCT) has made it possible to view in three dimensions dental anatomical structures which are difficult to view and access (Betancourt *et al.*, 2016). CBCT is a valuable aid as a complementary examination for endodontic diagnosis and treatment. Its advantages include the use of a smaller dose of radiation than conventional computed tomography, and providing more precise details than periapical or panoramic radiography (Abella *et al.*).

The aim of this of this study was to evaluate the prevalence and morphology of RE in the MFM in a southern Chilean sub-population by CBCT.

MATERIAL AND METHOD

This study was approved by the Ethics Committee of the Universidad de La Frontera, Temuco, Chile (Protocol n° 038/21). CBCT images were examined of 111 patients of both sexes referred to the radiology unit of the Dental Faculty of Universidad de La Frontera, Temuco, Chile, between November 2014 and December 2020. A cross-sectional observational descriptive study was designed for the present research. The CBCT examinations were applied as part of dental examination, diagnosis and treatment planning. Informed consent was obtained from all the patients whose CBCT images were included in the study. The patients' identities were not revealed to the investigators and the only information to which they had access was age and sex. The images were taken using a PAX Zenith 3D tomograph (Vatech Co, Gyeonggi-Do, Korea), with 120 kV, 10 mA, 24 s acquisition; FOV 8 x 6 cm / 12 x 9 cm, voxel size 0.12 mm. The data were exported in DICOM format in the EZ 3D 2009 software (Vatech, Hwaseong-si, Korea) and projected on a LED screen KDL-42W651A (Sony, Minato,

Japan) to observe 3D images of the coronal, mid and apical sections.

Two hundred ten MFM were observed (107 left MFM and 103 right MFM). The inclusion criteria for the CBCT images were: age between 18 and 75 years and complete root formation. The exclusion criteria were: presence of intraradicular post or metal restorations, endodontic treatment implemented, tooth rehabilitated with a fixed prosthesis, presence of calcification in the root canal, evidence of radectomy or periapical surgery, and mandibular molars with anomalies in their development. The images were examined by two specialists in endodontics with experience in CBCT viewing and prior training. The specialists examined 20 previously selected CBCT images of MFM. The observers analyzed the images on three occasions, at one-week intervals. When a consensus could not be reached, a radiology specialist helped in taking the final decision. Interexaminer agreements were calculated by using the Cohen kappa coefficient.

Methodology of Observation. First, the sagittal and coronal sections were oriented in parallel with the long axis of the root, and then sections were obtained in the axial and coronal planes at intervals of 0.5 mm and a thickness of 1 mm for all the samples, using multiplanar reformation (MPR). MPR constructs a three-dimensional model, showing all structures with thickness of 1 mm superimposed on one another. To detect the presence of RE, the observation and measurements were standardised, advancing 1 mm to apical (2 sections of 0.5 mm) from the floor of the pulp chamber to the most apical zone of the tooth (Betancourt *et al.*). In the sagittal plane, the RE was explored from coronal to apical in order to study the degree of curvature.

Statistical analysis. The data collected were recorded in a Microsoft Office Excel spreadsheet. Descriptive analysis of the data was carried out, determining a frequency distribution table. The Kolmogorov-Smirnov normality test was applied. The Mann-Whitney U non-parametric test for independent samples, Wilcoxon's test for related samples and Pearson's Chi-squared test for qualitative variables were all applied. Data were analysed with the IBM SPSS Statistics programme (version 23.0). A value of $p < 0.05$ was selected as the threshold of statistical significance.

RESULTS

Prevalence of RE. The 111 patients included in the study presented ages between 18 and 75 years, mean age 27.17 years. The prevalence of a third root in the permanent MFM

was 5.7 % (12/210). The incidence of RE was the same in male patients (2.9 %) as in female patients (2.9 %) ($p=0.324$). The occurrence of an RE in the left MFM was 7.3 % (3/41 patients) for male patients and 4.5 % (3/66) for female patients ($p=0.398$). The right MFM in male patients had a incidence of 8.1 % (3/37) and 4.5 % (3/66) for female patients ($p=0.340$). When the frequency of an RE was compared between the left (5.6 %) (Fig. 1) and right side (5.8 %) (Fig. 2), no statistically significant differences were found ($p=0.998$). The frequency of bilateral three-rooted was 71.43 % (5/7) (Fig. 3) and 28.57 % (2/7) were unilateral, distributed one on the right side and one on the left. The

Kappa index determined agreement between the examiners ($p= 0.000$) and the strength of agreement was very good (0.885).

Type of RE. The commonest type of RE was Type 1 (83.3 %), followed by Type 3 (16.7 %). No Type 2 was seen in the whole sample analysed. In women, 3 cases (100 %) of RE observed in the left MFM were of Type 1, while in men 66.7 % of RE were Type 1 and 33.3 % were Type 3 ($p= 0.317$). The distribution of RE in the right MFM in women was 100 % Type 1, while in men it was 66.7 % Type 1 and 33.3 % Type 3 ($p= 0.317$).

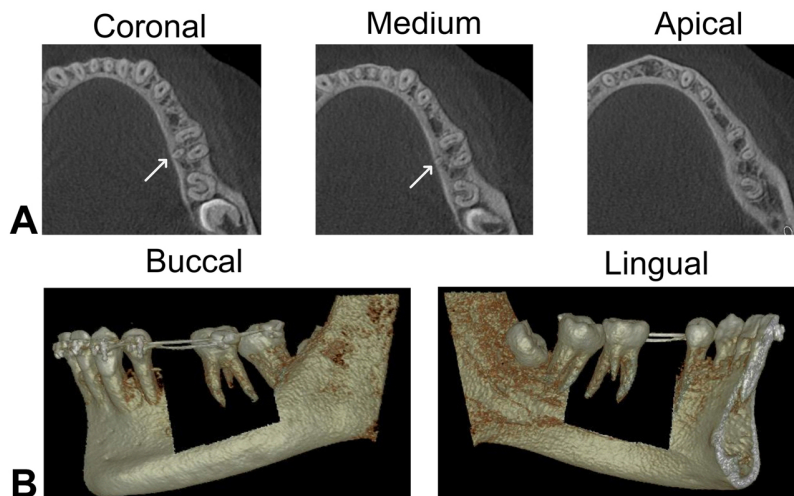


Fig 1. A. Cross-sectional CBCT image of left mandibular first molar with a clearly distinguished radix entomolaris (with the arrows). B.- Three-dimensional reconstruction of the triradicular left mandibular first molar, without the presence of alveolar bone.

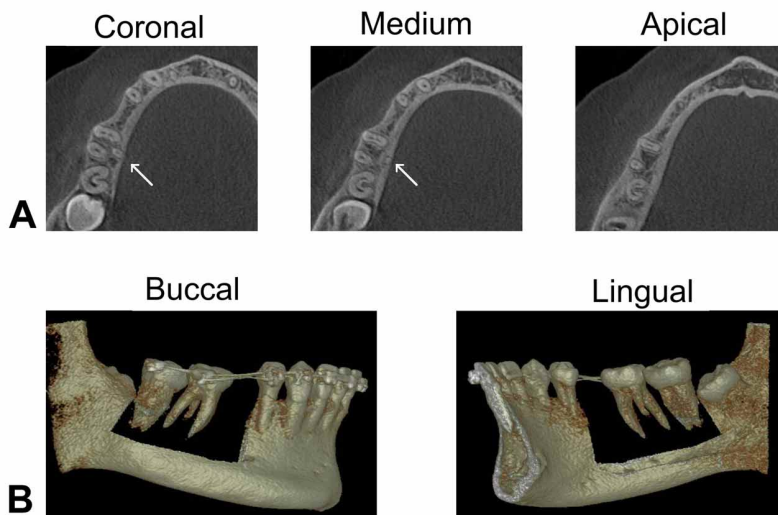


Fig 2. A.- Cross-sectional CBCT image of right mandibular first molar with a clearly distinguished radix entomolaris (with the arrows) B.- Three-dimensional reconstruction of the triradicular right mandibular first molar, without the presence of alveolar bone.

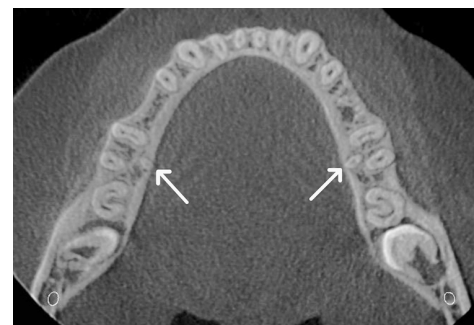

Fig 3. A case of a bilateral permanent three-rooted mandibular first molar in axial direction. White arrow indicates the extra distal root.

DISCUSSION

The MFM exhibit a wide range of variations in root number and their morphology. The major anatomical variant is the presence of a supernumerary DL root, known as a RE. A high percentage of endodontic treatment failures are due to failure to identify of an “extra” root, preventing correct disinfection and seriously compromising the prognosis of treatment (De Moor *et al.*). Therefore, an accurate diagnosis of RE in permanent MFM is essential for carrying out correct surgical, periodontal or endodontic treatment (Calberson *et al.*). One of the clinical signs that may be presented by RE is a more prominent distolingual lobe with cervical convexity (Calberson *et al.*). However, an altered morphology of the root structure is not always associated with a coronal alteration. Thus, imaging methods are recommended in order to determine the variations of the root canal system.

The frequency of occurrence of RE is currently a subject of discussion, mainly because of the differences in frequency between different populations. One predisposing factor associated with the presence of a third root in MFM is ethnicity. In Asian populations (races of Mongoloid origin) RE is considered a common morphological variation due to the high frequency of its appearance. Several studies have reported a frequency higher than 20 % (Tu *et al.*; Wang *et al.*, 2010; Zhang *et al.*, 2011), and others even over 30 % (Song *et al.*, 2009; Gu *et al.*, 2010). In the population of India the frequency of a third root ranges between 4.5 % and 13.3 % (Garg *et al.*, 2010), while the reported frequency in Africa is lower than in Asia and India, 3.1 % (Sperber & Moreau, 1998). In Caucasian populations, RE is considered a rare or unusual variant, with a frequency lower than 10 % (Torres *et al.*, 2015). These results demonstrate that the frequency of occurrence of RE varies with respect to the study population and its geographical location. However, there is little information on the genetic influence on the appearance of a third accessory root. Rodríguez-Niklitschek *et al.* (2015) carried out a clinical, radiological and genetic study of a double RE in a Chilean patient. They concluded that the genetic factor is one of the most probable causes of the appearance of RE. Genetic studies should be the focus of future research using appropriated methodologies.

Different methodologies have been used to assess the morphological variations of MFM. The technique most commonly used in vitro is diaphonization. This is a very precise technique, however the tooth has to be extracted for its study. Periapical radiography is the most frequently method used in vivo for endodontic diagnosis and treatment planning (Garg *et al.*). However, it provides only a two-dimensional view of the structures, which limits the possibility of observing an extra root. It must also be considered that this technique is sensitive both to the superposition of other structures (e.g. the zygomatic arch or tooth roots) as well as the skill of the operator. CBCT and micro-computed tomography (micro-CT) offer great advantages by providing a three-dimensional image of the structure studied in the sagittal, coronal and transverse axes. CBCT is a non-invasive technique, using a lower dose of radiation than micro-CT, and has shown a high level of accuracy in the location of morphological structures (Betancourt *et al.*). Also, CBCT allows reliable comparison of the results of morphological structures as a function of sex and bilateral occurrence in different populations. However, care must be taken with the “artefacts” that may appear in the image, due to metallic elements (restoration of amalgam, intra-radicular posts or dental implants) or even gutta-percha in teeth with endodontic treatment.

The results of the present CBCT study in a southern Chilean sub population, showed a frequency of RE of 5.7 % for permanent MFM, which is higher than the 3 % obtained in an Iranian population (Rahimi *et al.*, 2017), the 2.06 % found in a Turkish population (Demirbuga *et al.*, 2013) and the 2.03 % reported in an Israeli population (Shemesh *et al.*, 2015), all using CBCT. On the other hand, it was much lower than the frequency reported by Tu *et al.* (2009) (33.3 %) and Zhang *et al.* (29 %) using CBCT in Taiwanese and Chinese populations respectively. These differences may be due to racial and ethnic characteristics, sample size or selection of cases.

In the Chilean population there are few studies oriented towards the study of this morphological variation. In 2015, Torres *et al.* reported a prevalence of 6.16 % of RE in MFM in a Chilean sub-population, close to the 5.7 % observed in the present study. Recently, Abarca *et al.* (2020) did not observe the presence of RE in 510 MFM through CBCT. These differences with our results may be due to the fact that their study sub-population was from another region of the country. Further research should be performed to determine the incidence of RE in Chilean population.

According to sex, no significant differences were found in the distribution of the RE between men and women. These results are similar with those observed in Taiwanese and Israeli populations (Tu *et al.*; Tu *et al.*; Shemesh *et al.*)

The presence of a third root in the MFM habitually occurs bilaterally in patients (De Moor *et al.*; Huang *et al.*). In our study, 71.34 % of the RE were bilateral, close to the 68.57 % reported by Tu *et al.* (2007). This means that if a RE exists on one side, the clinician must consider searching in the contralateral side. The unilateral appearance of the extra third root was homogeneous between the right (5.8 %) and left hemiarch (5.6 %), with no statistically significant difference ($p = 0.998$). These results disagree with the findings in a Taiwanese population, where incidence of RE was more frequent in the right side (13.01 %) (Tu *et al.*, 2009). There is also a report in a population in Singapore where a greater frequency of RE was found on the left side (Loh, 1990).

The classification of types of RE according to De Moor *et al.* showed that Type 1 (straight root) was the most prevalent (83.3 %), followed by Type 3 (16.7 %). Special attention must be paid to Type 3, because of the complications that the curvature in the apical third may present for mechanical and disinfection procedures. Furthermore, it should be noted that type 2 was not observed in any of the cases analyzed.

CONCLUSIONS

The incidence of RE in MFM in a southern Chilean sub-population was 5.7 %. The occurrence was bilateral in the majority of cases and no significant differences were observed by sex or side. The commonest type of RE was Type 1 (83.3 %). The clinician should routinely carry out diagnosis of a possible extra third root in permanent MFM. Finally, we recommend the use of CBCT as a complementary diagnostic method to improve the outcome of endodontic treatment.

ACKNOWLEDGEMENTS

The authors are grateful for DIUFRO project DI21-0034. This project was partially funded by the Research Directorate of Universidad de La Frontera, Chile.

BETANCOURT, P.; ARIAS, A.; MATUS, D.; NAVARRO, P.; GARAY, I. & FUENTES, R. Prevalencia de Radix entomolaris en primeros molares mandibulares usando tomografía computarizada cone-beam en una subpoblación del sur de Chile. *Int. J. Morphol.*, 40(2):414-419, 2022.

RESUMEN: El objetivo de este estudio fue evaluar la prevalencia y morfología de radix entomolaris (RE) en el primer molar mandibular (MFM) en una subpoblación del sur de Chile mediante tomografía computarizada de haz cónico (CBCT). Se analizaron doscientas diez imágenes CBCT de MFM. Para detectar la presencia de OD se estandarizó la observación y las medidas, avanzando 1 mm apical desde el suelo de la cámara pulpar hasta la zona más apical del diente. Los datos fueron analizados mediante estadística descriptiva, siendo estadísticamente significativo un valor de $P < 0,05$. La prevalencia de una tercera raíz en el MFM permanente fue de 5,7 % (12/210). La incidencia de ER fue la misma en pacientes masculinos (2,9 %) que en pacientes femeninas (2,9 %) ($p=0,324$). La aparición de un ER en el MFM izquierdo fue del 7,3 % (3/41 pacientes) para los pacientes masculinos y del 4,5 % (3/66) para las pacientes femeninas ($p=0,398$). El MFM derecho en pacientes masculinos tuvo una incidencia de 8,1 % (3/37) y 4,5 % (3/66) para pacientes femeninos ($p=0,340$). Cuando se comparó la presencia de un OD entre el lado izquierdo (5,6 %) y derecho (5,8 %), no se encontraron diferencias estadísticamente significativas ($p=0,998$). La frecuencia de MFM de tres raíces bilaterales fue 71,43 % (5/7) y 28,57 % (2/7) fueron unilaterales. La prevalencia de RE en MFM en una subpoblación del sur de Chile fue de 5,7 %. La presentación fue bilateral en la mayoría de los casos y no se observaron diferencias significativas por sexo o lado. El tipo de ER más frecuente fue el tipo 1 (83,3 %). El uso de CBCT puede mejorar el resultado del tratamiento endodóntico.

PALABRAS CLAVE: Radix entomolaris; primer molar mandibular; tomografía de haz cónico; Morfología.

REFERENCES

- Abarca, J.; Duran, M.; Parra, D.; Steinfert, K.; Zaror, C. & Monardes, H. Root morphology of mandibular molars: a cone-beam computed tomography study. *Folia Morphol. (Warsz.)*, 79(2):327-32, 2020.
- Abella, F.; Patel, S.; Durán-Sindreu, F.; Mercadé, M. & Roig, M. Mandibular first molars with disto-lingual roots: review and clinical management. *Int. Endod. J.*, 45(11):963-78, 2012.
- Betancourt, P.; Navarro, P.; Muñoz, G. & Fuentes, R. Prevalence and location of the secondary mesiobuccal canal in 1,100 maxillary molars using cone beam computed tomography. *BMC Med. Imaging.*, 16(1):66, 2016.
- Bolk, L. Bemerkungen über Wurzel variation enammen schlichenunteren Molaren. *Ztg. Morphol. Anthropol.*, 17:605-10, 1915.
- Calberson, F. L.; De Moor, R. J. & Deroose, C. A. The radix entomolaris and paramolaris: clinical approach in endodontics. *J. Endod.*, 33(1):58-63, 2007.
- Carlsen, O. & Alexandersen, V. Radix entomolaris: identification and morphology. *Scan. J. Dent. Res.*, 98 (5):363-73, 1990.
- Chen, G.; Yao, H. & Tong, C. Investigation of the root canal configuration of mandibular first molars in a Taiwan Chinese population. *Int. Endod. J.*, 42(11):1044-9, 2009.
- De Moor, R. J. G.; Deroose, C. A. J. G. & Calberson, F. L. G. The radix entomolaris in mandibular first molars: an endodontic challenge. *Int. Endod. J.*, 37(11):789-99, 2004.
- Demirbuga, S.; Sekerci, A. E.; Dincer, A. N.; Cayabatmaz, M. & Zorba, Y. O. Use of cone-beam computed tomography to evaluate root and canal morphology of mandibular first and second molars in Turkish individuals. *Med. Oral Patol. Oral Cir. Bucal*, 18(4):737-44, 2013.
- Garg, A. K.; Tewari, R. K.; Kumar, A.; Hashmi, S. H.; Agrawal, N. & Mishra, S. K. Prevalence of three-rooted mandibular permanent first molars among the Indian Population. *J. Endod.*, 36(8):1302-6, 2010.
- Gu, Y.; Lu, Q.; Wang, H.; Ding, Y.; Wang, P. & Ni, L. Root canal morphology of permanent three-rooted mandibular first molars – part I: pulp floor and root canal system. *J. Endod.*, 36(6):990-4, 2010.
- Gulabivala, K.; Aung, T. H.; Alavi, A. & Ng, Y. L. Root and canal morphology of Burmese mandibular molars. *Int. Endod. J.*, 34(5):359-70, 2001.
- Huang, R. Y.; Cheng, W. C.; Chen, C. J.; Lin, C. D.; Lai, T. M.; Shen, E. C.; Chiang, C. Y. & Chiu, H. C. Fu E. Three-dimensional analysis of the root morphology of mandibular first molars with distolingual roots. *Int. Endod. J.*, 43(6):478-84, 2010.
- Loh, H. S. Incidence and features of three-rooted permanent mandibular molars. *Aust. Dent. J.*, 35(5):434-7, 1990.
- Rahimi, S.; Mokhtari, H.; Ranjkesh, B.; Johari, M.; Frough Reyhani, M.; Shahi, S. & Seif Reyhani, S. Prevalence of extra roots in permanent mandibular first molars in Iranian population: A CBCT Analysis. *Iran. Endod. J.*, 12(1):70-3, 2017.
- Rodríguez-Niklitschek, C. A.; Oporto, G.; Garay, I. & Salazar, L. A. Clinical, imaging and genetic analysis of double bilateral radix entomolaris. *Folia Morphol. (Warsz.)*, 74(1):127-32, 2015.
- Shemesh, A.; Levin, A.; Katzenell, V.; Ben Itzhak, J.; Levinson, O.; Zini, A. & Solomonov, M. Prevalence of 3- and 4-rooted first and second mandibular molars in the Israeli population. *J. Endod.*, 41(3):338-42, 2015.
- Song, J. S.; Kim, S. O.; Choi, B. J.; Choi, H. J.; Son, H. K. & Lee, J. H. Incidence and relationship of an additional root in the mandibular first permanent molar and primary molars. *Oral Surg. Oral Med. Oral Pathol. Oral Radiol. Endod.*, 107(1):56-60, 2009.
- Sperber, G. H. & Moreau, J. L. Study of the number of roots and canals in Senegalese first permanent mandibular molars. *Int. Endod. J.*, 31(2):117-22, 1998.
- Torres, A.; Jacobs, R.; Lambrechts, P.; Brizuela, C.; Cabrera, C.; Concha, C. & Pedemonte, M. E. Characterization of mandibular molar

- root and canal morphology using cone beam computed tomography and its variability in Belgian and Chilean population samples. *Imaging Sci. Dent.*, 45(2):95-101, 2015.
- Tu, M. G.; Huang, H. L.; Hsue, S. S.; Hsu, J. T.; Chen, S. Y.; Jou, M. J. & Tsai, C. C. Detection of permanent three rooted mandibular first molars by cone-beam computed tomography imaging in Taiwanese individuals. *J. Endod.*, 35(4):503-7, 2009.
- Tu, M. G.; Tsai, C. C.; Jou, M. J.; Chen, W. L.; Chang, Y. F.; Chen, S. Y. & Cheng, H. W. Prevalence of three-rooted mandibular first molars among Taiwanese individuals. *J. Endod.*, 33(10):1163-6, 2007.
- Vertucci, F. J. Root canal anatomy of the human permanent teeth. *Oral Surg. Oral Med. Oral Pathol.*, 58(5):589-99, 1984.
- Wang, Y.; Zheng, Q. H.; Zhou, X. D.; Tang, L.; Wang, Q.; Zheng, G. N. & Huang, D. M. Evaluation of the root and canal morphology of mandibular first permanent molars in a western Chinese population by cone-beam computed tomography. *J. Endod.*, 36(11):1786-9, 2010.
- Zhang, R.; Wang, H.; Tian, Y. Y.; Yu, X.; Hu, T. & Dummer, P. M. H. Use of cone-beam computed tomography to evaluate root and canal morphology of mandibular molars in Chinese individuals. *Int. Endod. J.*, 44(11):990-9, 2011.

Corresponding author:
Prof. Dr. Pablo Betancourt
Center for Research in Dental Sciences (CICO)
Endodontic Laboratory
Universidad de La Frontera
Avenida Francisco Salazar 01145
Temuco
CHILE

E-mail: pablo.betancourt@ufrontera.cl