

Anatomical Landmarks for Locations and Boundary of Distal Tarsal Tunnel at Medial Side of Ankle with Clinical Implication

Puntos de Referencia Anatómicos para Ubicaciones y Límites del Túnel Tarsiano Distal en el Lado Medial del Tobillo con Implicación Clínica

Chanatporn Inthasan¹; Tanawat Vaseenon² & Pasuk Mahakkanukrauh^{1,3}

INTHASAN, C.; VASEENON, T. & MAHAKKANUKRAUH, P. Anatomical landmarks for locations and boundary of distal tarsal tunnel at medial side of ankle with clinical implication. *Int. J. Morphol.*, 40(2):455-459, 2022.

SUMMARY: The tarsal tunnel (TT) is an osteofibrous tunnel that separates into proximal and distal tarsal tunnels. The most common nerve entrapment which involved tarsal tunnel was tarsal tunnel syndrome (TTS) which divided into proximal TTS and distal TTS because they had different compression areas and symptoms. We were interested in distal TT because this structure had limited studies. Therefore, we studied anatomical landmarks of locations and boundary of distal TT. We studied forty legs from fresh frozen cadavers and used two reference lines: Malleolar-calcaneal (MC) and navicular-calcaneal (NC) axes. The locations of the distal tarsal tunnel were defined by 10 located points and were recorded in X-coordinate and Y-coordinate. The lengths of boundary of the tarsal tunnel were measured from one point to the other. These results were reported as mean±SD. We found that the distal TT located deep to abductor hallucis (AbH) muscle. Medial wall of distal TT had two layers such as deep fascia of AbH muscle and deep thin layer. It showed the trapezoidal shape and was divided into two tunnels by the septum. The information of the location and boundary of the distal TT could improve knowledge and understanding of clinicians and anatomists. Additionally, this information could help surgeons improve their treatments, especially tarsal tunnel release.

KEY WORDS: Distal tarsal tunnel; Tarsal tunnel syndrome; Ankle; Anatomy.

INTRODUCTION

The essential structure which involves neurovascular structures at the medial side of the ankle is the tarsal tunnel (TT) (Ahmad *et al.*, 2012). TT is an osteofibrous tunnel that separates into proximal and distal tarsal tunnels (Heimkes *et al.*, 1987). Firstly, the proximal TT locates under flexor retinaculum as a roof (Ahmad *et al.*). On the other hand, the distal TT locates under deep fascia of abductor hallucis (AbH) muscle (Kelikian & Sarrafian, 2011; Singh & Kumar, 2012). It has a septum separates distal TT into medial and lateral tunnels for branches of posterior tibial nerve and artery as medial and lateral plantar nerves and arteries (Fernández-Gibello *et al.*, 2019; Moroni *et al.*, 2019a). Especially distal TT, it has essential locations which endanger nerve entrapment such as near the septum and under deep fascia of AbH muscle (Heimkes *et al.*; Moroni *et al.*, 2019b).

The most common neuro-pathology at the medial side of the ankle is tarsal tunnel syndrome (TTS) that is the nerve entrapment (Sammarco & Chang, 2003) and is classified to proximal or classical TTS and distal TTS because they have different etiologies and symptoms that depend on the compression of the posterior tibial nerve (PTN) or its branch or branches specifically. The neuro structures are compressed under distal TT such as terminal branches of PTN as medial plantar nerve (MPN), lateral plantar nerve (LPN), medial calcaneal nerve (MCN), and/or inferior calcaneal nerve (ICN). In addition, the most compressed structure is LPN (Heimkes *et al.*).

Nowadays, the treatment procedure always begins from conservative treatment first. If the conservative

¹ Department of Anatomy, Faculty of Medicine, Chiang Mai University, Chiang Mai, 50200, Thailand.

² Department of Orthopaedics, Faculty of Medicine, Chiang Mai University, Chiang Mai, 50200, Thailand.

³ Excellence in Osteology Research and Training Center (ORTC), Chiang Mai University, Chiang Mai, 50200, Thailand.

treatment fails, the clinicians will consider using other options such as operative decompression or endoscopic procedures. Recently, the endoscopic TT decompression procedures are chosen for TTS's treatment because they are safer and higher success rate than open surgical treatment (Gkotsoulias *et al.*, 2014). However, TTR can occur at a failure rate from 4 % to 56 % (DiGiovanni *et al.*, 2003; Dellon, 2008; Ahmad *et al.*). Failure of TTR has several causes, especially an inadequate TTR. It is an effect of a deficient anatomical understanding of TT and nerve variations. Additionally, the recurrent TTS can appear over 90 % from an inadequate TTR due to lack of anatomical knowledge of TT (Barker *et al.*, 2008).

Therefore, we were interested to study anatomical landmarks of locations and boundary of distal TT at the medial side of ankle joint, especially thin layer of distal TT in order to improve the anatomical knowledge of clinicians and apply to treatment distal TTS by using TTR.

MATERIAL AND METHOD

Forty legs from fresh frozen cadavers were randomly dissected which were donated from the Department of Anatomy, Faculty of Medicine, Chiang Mai University, Chiang Mai, Thailand. This study was approved by the Research Ethics Committee, Faculty of Medicine, Chiang Mai University (Study code: ANA-2561-05229). Cadavers had sufficient quality and no evidence of surgical procedures at the ankle in medial and lateral sides which were included in this study. Each leg was set up in the anatomical position, after that the superficial structures and AbH muscle were removed. Then, deep fascia of AbH muscle was cautiously

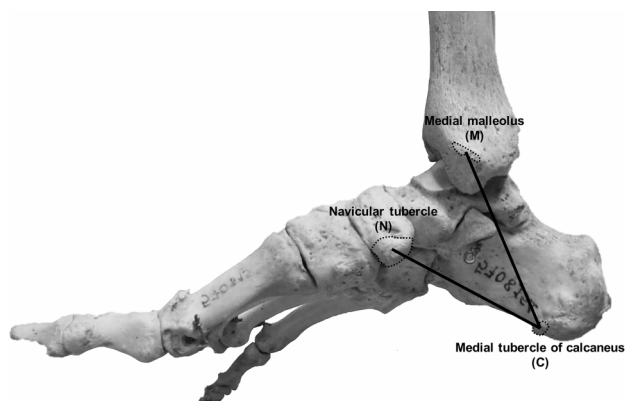


Fig. 1. The reference lines: the malleolar-calcaneal (MC) axis and the navicular-calcaneal (NC) axis. The MC axis started from the medial malleolar (M) to the medial process of calcaneal tubercle (C). The NC axis that starts from the tubercle of navicular bone (N) to the medial process of calcaneal tubercle (C).

removed in order to identify the thin layer of distal TT. Next, this study determined two reference lines such as malleolar-calcaneal (MC) axis and navicular-calcaneal (NC) axis which were respectively initiated from medial malleolus and tubercle of navicular bone to medial process of the calcaneal tubercle as shown in Figure 1. The locations of the distal tarsal tunnel were defined 10 located points and were recorded in X-coordinate and Y-coordinate as illustrated in Table I. Furthermore, all parameters of locations and lengths of boundary of the distal TT were studied and measured by using a digital vernier caliper as represented in Figure 2. Additionally, the results were recorded and calculated as mean \pm SD by using Microsoft Excel. Lastly, all figures in this study were taken from the cadavers and the diagrams were drawn by Microsoft PowerPoint based on the dissected structures.

RESULTS

The distal TT located deep to AbH muscle. After we removed deep fascia of AbH muscle, the thin fascia layer was appeared which seemed the transparent trapezoid which presented the wide anterior margin and narrow posterior margin. The posterior margin of distal TT located mostly inferior to the tubercle of navicular bone which was shown in Figures 2 and 3. The inferior margin closed generally to plantar aponeurosis which was shown in Figure 2. Additionally, it ran different two directions such as oblique and vertical directions. The oblique directional boundary composed of A, Sep, C, D, G, F, and H points and the other one, the vertical direction, located behind F to G line. The vertical part inserted medial inter-muscular septum and the oblique part attached calcaneus. The location of each point of the distal TT was shown in Table I. The lengths of distal TT's boundary were shown in Figure 3.

Furthermore, the distal TT was divided into two tunnels including medial tunnel for medial plantar neurovascular structures and lateral tunnel for lateral plantar neurovascular structures by the septum. Focusing at anterior margin, the lateral tunnel had the wider anterior margin than the medial tunnel. After superior margin of medial plantar tunnel (A to B) was cleaved and flapped postero-inferiorly, the septum was represented and it ran antero-distally direction which was illustrated in Figure 2. Additionally, it originated from fibrous sheath of flexor hallucis longus tendon to attach deep part of thin layer. In addition, the branching point of the posterior tibial artery which branched into medial plantar artery (MPA) and lateral plantar artery (LPA) located slightly proximal to the origination of septum.

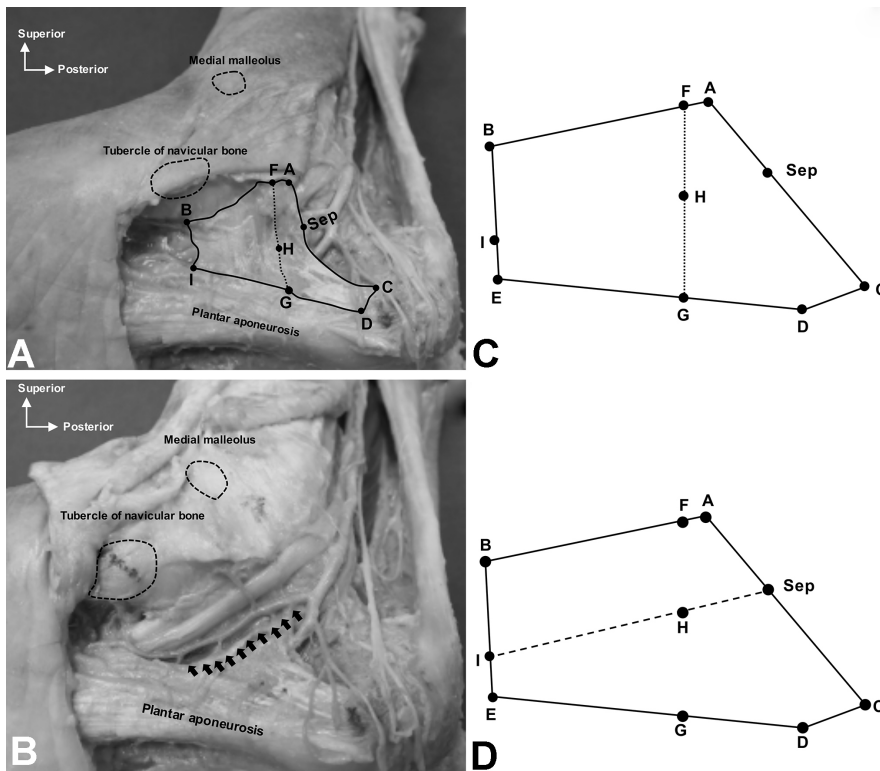


Fig. 2. The located points and boundary of the distal tarsal tunnel after removed abductor hallucis muscle and its deep fascia. The abbreviations of each point comprised of superior point of TT at anterior margin (A), superior point of TT at posterior margin (B), inferior point of TT at anterior margin (C), deep fascia of abductor hallucis muscle at medial process of calcaneal tubercle (D), inferior point of TT at posterior margin (E), superior point of TT at inner layer at an anterior margin (F), inferior point of TT at inner layer at posterior margin (G), origin of septum at inner layer at anterior margin (H), ending point of septum at inner later at posterior margin (I), and origin of septum at anterior margin (Sep). The solid line (—) presented the boundary of distal tarsal tunnel. The dotted line (· · ·) presented the separated line between oblique and vertical directions of distal tarsal tunnel. The black arrows (↑) and long-dashed line (- - -) presented septum's direction which separated medial plantar and lateral plantar tunnels of distal tarsal tunnel.

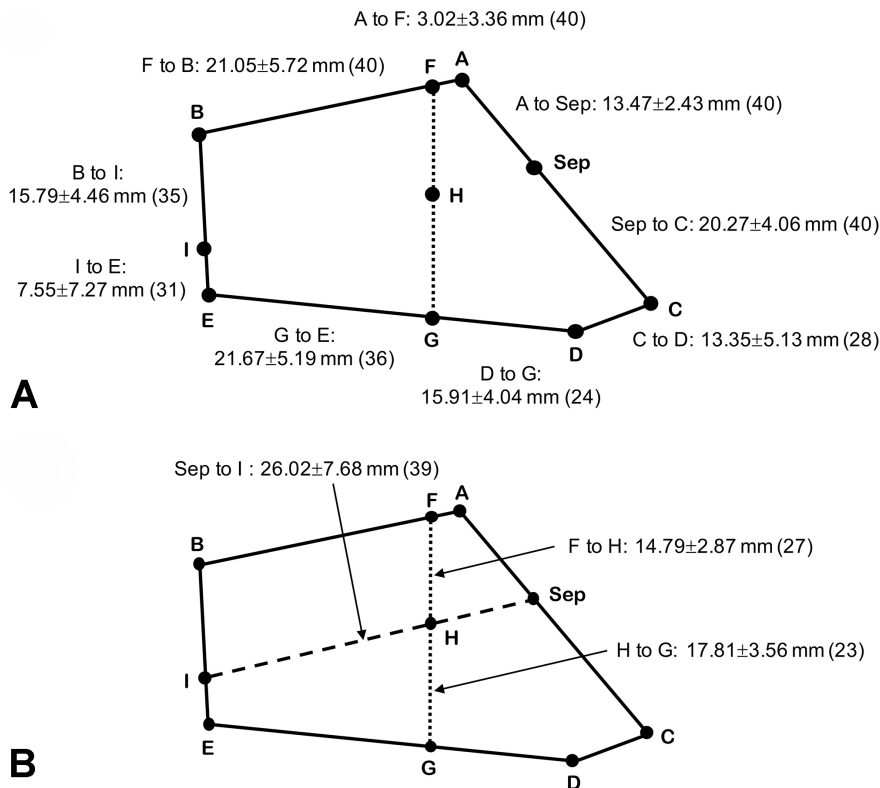


Fig. 3. The distances of each point of the boundary of the distal TT. The abbreviation of each point were superior point of TT at anterior margin (A), superior point of TT at posterior margin (B), inferior point of TT at anterior margin (C), deep fascia of abductor hallucis muscle at medial process of calcaneal tubercle (D), inferior point of TT at posterior margin (E), superior point of TT at inner layer at an anterior margin (F), inferior point of TT at inner layer at posterior margin (G), origin of septum at inner layer at anterior margin (H), ending point of septum at inner later at posterior margin (I), and origin of septum at anterior margin (Sep). The solid line (—) presented the boundary of the distal tarsal tunnel. The dotted line (· · ·) presented the separated line between oblique and vertical directions of distal tarsal tunnel. The long-dashed line (- - -) presented septum's direction which separated medial plantar and lateral plantar tunnels of distal tarsal tunnel.

Table I. Located points of the distal tarsal tunnel.

Measurements	No.	MC axis		NC axis	
		X-coordinate (mm)	Y-coordinate (mm)	X-coordinate (mm)	Y-coordinate (mm)
Superior point of TT at anterior border (A)	40	37.15±4.10	-1.14±3.88		
Superior point of TT at posterior border (B)	38			17.10±5.62	-0.79±10.51
Inferior point of TT at anterior border (C)	38	66.47±2.6.48	7.05±6.37		
Deep fascia of abductor hallucis muscle at medial process of calcaneal tubercle (D)	34			57.88±7.24	-0.96±5.38
Inferior point of TT at posterior border (E)	31			33.09±6.46	-12.12±7.13
Superior point of TT at inner layer at an anterior border (F)	40	37.45±4.24	-2.99±5.55		
Inferior point of TT at inner layer at anterior border (G)	32			43.03±7.09	0.52±11.63
Origin of septum at inner layer at anterior border (H)	26	48.72±7.28	-4.49±8.25		
Ending point of septum at inner later at posterior border (I)	35			27.30±6.76	-2.87±12.46
Origin of septum at anterior border (Sep)	37	48.56±5.40	-1.23±3.55		

MC, Malleolar-calcaneal; NC, Navicular-calcaneal; TT, tarsal tunnel.

DISCUSSION

In distal TT, it was divided into 2 chambers, for example, upper and lower chambers by interfascicular septum. In previous study, the medial wall of upper chamber or medial tunnel and lower chamber or lateral tunnel was flexor retinaculum that split and covered AbH muscle from its superior margin. Moreover, flexor retinaculum ran vertically at this region (Kelikian & Sarrafian). Thus, the thin transparent layer which ran vertically in this study was the distal part of flexor retinaculum which continued with medial intermuscular septum. In addition, the oblique part of thin layer in this study was deep aponeurotic segment of flexor retinaculum which attached calcaneus and formed posterior neurovascular tunnel (Kelikian & Sarrafian). For medial tunnel, considering its size was approximately 2.5 cm in length and 1.5 cm in width in anterior and posterior margins and represented trapezoidal shape as shown in Figures 2 and 3. The anterior margin of medial tunnel was smaller than anterior margin of lateral tunnel approximately one times. Nevertheless, the high incident of nerve entrapment in distal TT was LPN entrapment because LPN passed through medial intermuscular septum which increased compression point of LPN (Singh & Kumar). For the other one, the septum in this study showed the origination, insertion, and direction similar to the previous study (Heimkes *et al.*). The beginning point of septum originated slightly distal to the branching point of posterior tibial artery (PTA). Focusing the exact location of septum was approximately 5 cm from medial malleolus on MC axis and it was alike the location of branching point of PTA on MC axis (Inthasan *et al.*, 2020). In addition, the perpendicular distance from MC axis of septum was lower MC axis and branching point of PTA approximately 0.1 cm and 0.7 cm, respectively. Hence, the clinicians can use the branching point of PTA in order to identify the located origination of septum. Moreover, the physicians can estimate the length and direction of septum for TTR including the ac-

tual of the locations and lengths of boundary of the distal TT which were shown in Table I and Figure 3, respectively.

Tarsal tunnel syndrome (TTS) is the most common neuropathy entrapment of the foot (Sammarco & Chang) and divides into proximal TTS and distal TTS due to differ etiology and symptoms of patients (Heimkes *et al.*). The distal TTS was nerve entrapment of terminal branches of PTN which were MPN, LPN, MCN, and/or ICN. Furthermore, it related with chronic plantar fasciitis and posterior tibial tendon dysfunction. For treatments, clinicians usually select conservative treatment firstly. If this technique is unsuccessful, they will consider using open surgical technique for tarsal tunnel release (TTR). Success rate of TTR had a vary range from 44 % to 96 % (Pfeiffer & Cracchiolo 3rd, 1994; Hendrix *et al.*, 1998). Although, open surgery had an advantage which was the surrounding structures visualized completely (Mook *et al.*, 2013), open TTR still had complications, particularly inadequate distal TTR (Barker *et al.*). Recently, trending for TTR changes to minimally invasive release by using endoscopic technique which can cure nerve entrapment of individual branches of PTN (Lui, 2007; Chan *et al.*, 2008). Over the last years, Moroni *et al.* (2019a,b) studied distal TTR by using ultrasound-guide foot and ankle decompression surgery (UGAFDS) technique which was ultra-minimally invasive technique. They showed that neurovascular structures had no damage in 100 % of cases. Remarkably, podiatric surgeons in this method required experience in ultrasound-guided procedures over 5 years and these procedures were guided by a clinical anatomist who received training in both clinical anatomy and surgery for many years (Moroni *et al.*, 2019a,b). Therefore, the anatomical knowledge about locations and boundary of distal tarsal tunnel is essential for clinicians, especially podiatric surgeons in order to improve their anatomical knowledge and understanding and apply this information for clinically anatomical treatment in distal TTS effectively.

CONCLUSION

The knowledge of the anatomical landmark for location and boundary of the distal tarsal tunnel at the medial side of the ankle could improve knowledge and understanding of anatomists and podiatric surgeons. Additionally, surgeons can apply it to improve their treatments, especially tarsal tunnel release in order to decrease patients' complications and increase success rate of treatments. Therefore, the anatomical knowledge of the distal tarsal tunnel at the medial tarsal region should be a continued study in the future.

ACKNOWLEDGEMENTS

We would like to thank the research administration section, Faculty of Medicine, Chiang Mai University for their financial support of this project (Research ID: ANA-2561-05229). Importantly, we would love to pay a tribute of respect to the persons who donated their bodies for the improvement of education and research.

INTHASAN, C.; VASEENON, T. & MAHAKKANUKRAUH, P. Puntos de referencia anatómicos para ubicaciones y límites del túnel tarsiano distal en el lado medial del tobillo con implicación clínica. *Int. J. Morphol.*, 40(2):455-459, 2022.

RESUMEN: El túnel tarsiano (TT) es un túnel osteofibroso que se divide en túneles tarsianos proximal y distal. El atrapamiento nervioso más común del túnel tarsiano es el síndrome del túnel tarsiano (TTS), el cual se divide en TTS proximal y TTS distal debido a diferentes áreas de compresión. En este trabajo se estudiaron los puntos de referencia anatómicos de las ubicaciones y los límites del TT distal. Estudiamos cuarenta piezas de cadáveres frescos congelados y utilizamos dos líneas de referencia: ejes maleolar-calcáneo (MC) y navicular-calcáneo (NC). Las ubicaciones del túnel tarsiano distal se definieron en 10 puntos y se registraron en coordenadas X e Y. Las longitudes de los límites del túnel tarsiano se midieron desde un punto a otro. Estos resultados se informaron como media \pm DE. Encontramos que el TT distal se ubicaba profundo al músculo abductor del hálux (AbH). La pared medial del TT distal tenía dos capas, la fascia profunda del músculo AbH y una capa delgada profunda. Se observó la forma trapezoidal del túnel la que se encontraba dividida por el tabique en dos túneles. La información de la ubicación y el límite del TT distal podría mejorar el conocimiento de los médicos y anatomistas. Además, esta información podría ayudar a los cirujanos durante los tratamientos, especialmente la liberación del túnel tarsiano.

PALABRAS CLAVE: Túnel tarsiano distal; Síndrome del túnel tarsiano; Tobillo; Anatomía.

REFERENCES

- Ahmad, M.; Tsang, K.; Mackenney, P. & Adedapo, A. Tarsal tunnel syndrome: a literature review. *J. Foot Ankle Surg.*, 18(3):149-52, 2012.
- Barker, A. R.; Rosson, G. D. & Dellon, A. L. Outcome of neurolysis for failed tarsal tunnel surgery. *J. Reconstr. Microsurg.*, 24(02):111-8, 2008.
- Chan, L. K.; Lui, T. H. & Chan, K. B. Anatomy of the portal tract for endoscopic decompression of the first branch of the lateral plantar nerve. *Arthroscopy*, 24(11):1284-8, 2008.
- Dellon, A. L. The four medial ankle tunnels: a critical review of perceptions of tarsal tunnel syndrome and neuropathy. *Neurosurg. Clin.*, 19(4):629-48, 2008.
- DiGiovanni, B. F.; Abuzzahab, F. S. & Gould, J. S. Plantar fascia release with proximal and distal tarsal tunnel release: a surgical approach to chronic, disabling plantar fasciitis with associated nerve pain. *Tech. Foot Ankle Surg.*, 2(4):254-61, 2003.
- Fernández-Gibello, A.; Moroni, S.; Camuñas, G.; Montes, R.; Zwierzina, M.; Tasch, C.; Starke, V.; Sañudo, J.; Vazquez, T. & Korschake, M. Ultrasound-guided decompression surgery of the tarsal tunnel: a novel technique for the proximal tarsal tunnel syndrome—Part II. *Surg. Radiol. Anat.*, 41(1):43-51, 2019.
- Gkotsoulas, E. N.; Simonson, D. C. & Roukis, T. S. Outcomes and safety of endoscopic tarsal tunnel decompression: a systematic review. *Foot Ankle Spec.*, 7(1):57-60, 2014.
- Heimkes, B.; Posel, P.; Stotz, S. & Wolf, K. The proximal and distal tarsal tunnel syndromes. *Int. Orthop.*, 11(3):193-6, 1987.
- Hendrix, C. L.; Jolly, G. P.; Garbalosa, J. C.; Blume, P. & DosRemedios, E. Entrapment neuropathy: the etiology of intractable chronic heel pain syndrome. *J. Foot Ankle Surg.*, 37(4):273-9, 1998.
- Inthasan, C.; Vaseenon, T. & Mahakkanukrauh, P. Anatomical study and branching point of neurovascular structures at the medial side of the ankle. *Anat. Cell Biol.*, 53(4):422-434, 2020.
- Kelikian, A. S. & Sarrafian, S. K. *Sarrafian's Anatomy of the Foot and Ankle: Descriptive, Topographic, Functional*. 3rd ed. Philadelphia, Lippincott Williams & Wilkins, 2011.
- Lui, T. H. Endoscopic decompression of the first branch of the lateral plantar nerve. *Arch. Orthop. Trauma Surg.*, 127(9):859-61, 2007.
- Mook, W. R.; Gay, T. & Parekh, S. G. Extensile decompression of the proximal and distal tarsal tunnel combined with partial plantar fascia release in the treatment of chronic plantar heel pain. *Foot Ankle Spec.*, 6(1):27-35, 2013.
- Moroni, S.; Gibello, A. F.; Zwierzina, M.; Nieves, G. C.; Montes, R.; Sañudo, J.; Vazquez, T. & Korschake, M. Ultrasound-guided decompression surgery of the distal tarsal tunnel: a novel technique for the distal tarsal tunnel syndrome—part III. *Surg. Radiol. Anat.*, 41(3):313-21, 2019a.
- Moroni, S.; Zwierzina, M.; Starke, V.; Moriggl, B.; Montesi, F. & Korschake, M. Clinical-anatomic mapping of the tarsal tunnel with regard to Baxter's neuropathy in recalcitrant heel pain syndrome: part I. *Surg. Radiol. Anat.*, 41(1):29-41, 2019b.
- Pfeiffer, W. H. & Cracchiolo 3rd, A. Clinical results after tarsal tunnel decompression. *J. Bone Joint Surg. Am.*, 76(8):1222-30, 1994.
- Sammarco, G. J. & Chang, L. Outcome of surgical treatment of tarsal tunnel syndrome. *Foot Ankle Int.*, 24(2):125-31, 2003.
- Singh, G. & Kumar, V. Neuroanatomical basis for the tarsal tunnel syndrome. *Foot Ankle Int.*, 33(6):513-18, 2012.

Corresponding author:
Prof. Pasuk Mahakkanukrauh
Department of Anatomy
Faculty of Medicine
Chiang Mai University
Chiang Mai, 50200
THAILAND

E-mail: pasuk034@gmail.com