

Magnificent Harmony in Morphometric Measurements of Orbita and Foramen Magnum

Armonía Magnífica en Medidas Morfométricas de Órbita y Foramen Magno

Güler, H.¹ & Yilmaz, H.²

GÜLER, H. & YILMAZ, H. Magnificent harmony in morphometric measurements of orbita and foramen magnum. *Int. J. Morphol.*, 41(2):445-450, 2023.

SUMMARY: The foramen magnum (FM) is the key component of the craniovertebral junction, which connects the brain stem and medulla spinalis and is closely related to vital structures. FM dimensions are of great clinical importance. Considering the similarity in shape between FM and orbita, we thought that there might be a relationship between the lengths (sagittal diameter) and widths (transverse diameter) of these structures. Since it is not possible to reach FM directly, we set up our hypothesis as can we calculate the foramen magnum dimensions from orbital measurements before proceeding to costly tests. We also investigated this harmony in the skulls we used in the study. In the study, 21 dried skull bones from the Turkish population were used. FM and right Orbital length and width measurements were made. Precision digital caliper was used for measurements. Statistical validity and reliability analyzes were performed to prove the agreement between the measurements. We found that the length of the orbit and FM in the sagittal plane is close to each other, with 34.74 ± 2.11 mm and 34.99 ± 3.0 mm, and the width of the orbit in the coronal plane is approximately 1.40 times the width of the FM. We proved that the estimation of FM dimensions based on orbital measurements is also statistically valid and safe. Using orbital measurements, it is possible to estimate FM dimensions which are difficult to reach directly in living humans.

KEY WORDS: Foramen magnum; Orbita; Morphometry; Prediction; Reliability; Validity.

INTRODUCTION

The skull base is one of the most anatomically complex regions. Knowing the craniometric measurements of the skull base is of great importance for clinicians in defining pathological diagnoses and craniocervical junction anomalies, choosing the appropriate surgical method and determining the resections to be performed. The foramen magnum (FM) is located at the lowest part of the posterior fossa cranii and is the largest formation of the skull. This structure connects the posterior fossa cranii and canalis vertebralis with each other. Medulla oblongata (downward extension of the spinal cord), part of the XI cranial nerve, a. vertebralis, a. spinalis anterior and posterior passes through the foramen magnum (Günes & Vatansever, 2018).

FM is an important cranial structure that attracts attention in various disciplines in many areas of medicine, such as forensic anthropology, physical anthropology, comparative anatomy, evolutionary biology and surgery (Zdilla *et al.*, 2017).

It has clinical importance as pressure will occur on vital structures in FM-related achondroplasia and cerebellar hernias (Inao *et al.*, 1993; Chethan *et al.*, 2012).

Measurements and assessments of FM and related structures assist surgeons in the preoperative preparation of surgical procedures (Günes & Vatansever, 2018).

There is a relationship between surgical procedures at the craniovertebral junction and high morbidity and difficulties. Resection of tumors of this area remains a technically demanding surgical procedure (Tanrisever *et al.*, 2020).

In neurosurgery practice, the transcondylar approach is widely used to access lesions. It has been reported that understanding the bony anatomy of the condylar region is important for this approach (Muthukumar *et al.*, 2005).

¹Department of Anatomy, Faculty of Medicine, Erciyes University, Kayseri, Turkey.

²Department of Anatomy, Faculty of Medicine, Ordu University, Ordu, Turkey.

Variations of the FM shape are of diagnostic, clinical and radiological significance. Morphological types of FM shapes are: round, egg, quadrangular, oval, irregular, hexagonal, and pentagonal (Govsa *et al.*, 2011; Chethan *et al.*, 2012).

There are studies showing that the shape and size of the foramen magnum can be used for sex determination (Babu *et al.*, 2012; Meral *et al.*, 2020).

It has been shown that there is a relationship between the shape of FM and the ancestors of individuals (Chethan *et al.*, 2012).

The dimensions of FM are also important in the diagnosis and treatment planning of various neurological diseases (such as Chiari malformation) (Ulutabanca *et al.*, 2015). There are studies that correlate the morphometry of the foramen magnum with brain volume, cranial size and intracranial volume (Acer *et al.*, 2006).

In a study, it has been reported that there is a perfect harmony between cranium diameters and FM diameters, and FM dimensions can be reached from cranium dimensions (Ulçay *et al.*, 2021).

There are morphometric and morphological variation studies of FM in different populations. However, there are very few studies showing the proportional harmony between the structures in the cranium. In our study, we thought that FM dimensions studied in many disciplines can be estimated by external orbital measurements. In our study, we aimed to show the relationship between orbital and FM diameters on 21 dry bones by making validity and reliability analyzes.

MATERIAL AND METHOD

In our study, macroscopic observations and measurements were made on 21 dry bone skulls of adult individuals in the Turkish population. FM shapes were macroscopically examined and classified. FM length: sagittal diameter (measurement taken between the basion, which is the midpoint in the anterior, and the opisthion, which is the midpoint in the posterior), and FM width: transverse diameter (measurement taken from the widest part of the FM in the horizontal plane) were measured with a 0.1 mm precision digital caliper (Fig. 1A). In addition, orbita (O) width: transverse diameter (measurement taken between the midpoints of the medial and lateral edges that divide the orbita into two) and O length: sagittal diameter

(the distance between the upper and lower edges of the orbit; it is perpendicular to its width and similarly divides the orbita into two) measurements were made (Fig. 1B). From the measurements made, FM (Zdilla *et al.*, 2017) and O (Kaplanoglu *et al.*, 2014) index was calculated with formulas in accordance with the literature.

FM Index: FM length/FM width, Orbita Index: Orbita Length/Orbita Width × 100

In the study, measurements in the coronal and sagittal planes were used for the new indices. The proportional agreement (RR) between the measurements was determined by the O/FM formula. Orbital Width / FM Width formula was used in the calculation of the index in the coronal plane, and the Orbital Length / FM Length formula was used in the calculation of the index in the sagittal plane.

RR (Related Ratio)= O/FM

RR₁ (Proportional Cohesion Length Index)= $\frac{O \text{ length}}{FM \text{ length}}$

RR₂ (Proportional Cohesion Width Index)= $\frac{O \text{ width}}{FM \text{ width}}$

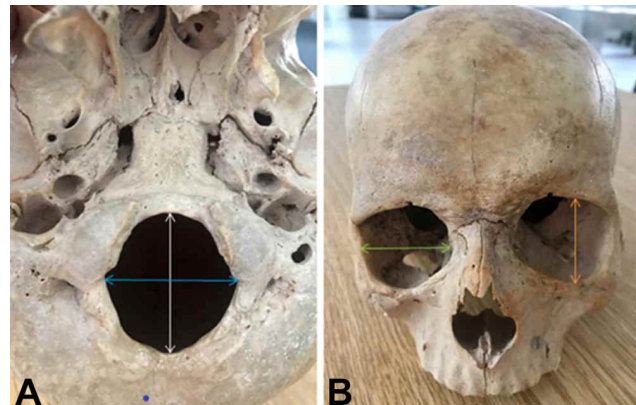


Fig. 1. A, B. Length and width measurements of foramen magnum and orbita.

Statistical analysis. The means and standard deviations of the measurements were obtained. Means were compared with each other. Orbita and foramen magnum measurements were proportional to each other and the relative ratios were calculated. Proportional values were subjected to normal distribution analysis using 5 parameters (Skewness-Kurtosis, Mean/Std, Histogram Q-Q Polts, Shapiro Wilk Test). Normally distributed data were subjected to the Related Samples T-Test. When it was determined that there was no difference between the data ($p>0.05$), validity and reliability analysis was performed. The Bland Altman Test was used in the validity analysis, and the Intra Class Correlation Coefficient (ICC) test was used in the reliability analysis.

In the Bland Altman test, the data for the difference between two measurements were calculated and the Simple Scotter Dat graph was drawn. The reliability (r) value in the ICC test was interpreted according to the literature (Sung *et al.*, 2002).

RESULTS

It was observed that the length of O and the length of FM in the sagittal plane were almost equal ($RR_1 = 1$). In the coronal plane, the width of O was approximately 1.40 times the width of FM ($RR_2 = 1.40$). The findings of the measurements are in Table I.

Table I. Descriptive parameters of orbita and foramen magnum.

| Measured Morphometric Parameter | Orbita | Foramen | Ratio |
|---------------------------------|-----------|-----------|-------|
| | Mean ± SD | Mean ± SD | |
| Length | 34.74±2.1 | 34.99±3.0 | 0.998 |
| Width | 39.93±1.6 | 28.35±1.9 | 1.4 |

Mean ± SD: Mean± Standard deviation.

In order to find an answer to the question of whether foramen magnum diameters can be calculated using orbital ratios, validity and reliability analyzes were performed after T-test (Table II) was performed on the dependent variables.

Table II. Comparison of proportioned orbital and foramen magnum diameters with T-Test.

| Measured Morphometric Parameter | Orbita _{RR} | Foramen Magnum _{RR} | P value |
|---------------------------------|----------------------|------------------------------|---------|
| | Mean ± SD | Mean ± SD | |
| Length | 34.74±2.1 | 34.99±3.05 | 0.724 |
| Width | 28.32±1.1 | 28.35±1.91 | 0.937 |

Mean ± SD: average-standart deviation; RR: Related Ratio. There is no differences between orbita_{RR} and foramen magnum_{RR}

It was observed that there was no statistically significant difference between the proportional orbita and foramen magnum diameters ($p > 0.05$).

Orbita_{RR} values were calculated by converging the orbita to the foramen magnum in Related Ratio (RR) ratios. There was no statistically significant difference between Orbita_{RR} and foramen magnum diameters ($p > 0.05$). Since there was no statistical difference, validity (Fig. 2 and Fig. 3) and reliability (Table III) analysis were performed.

It was observed that there was a validity agreement between Orbita_{RR} and Foramen magnum diameters in the

sagittal axis (Fig. 2). It was observed that there was a validity agreement between the orbita_{RR} and foramen magnum diameters in the transverse axis (Fig. 3).

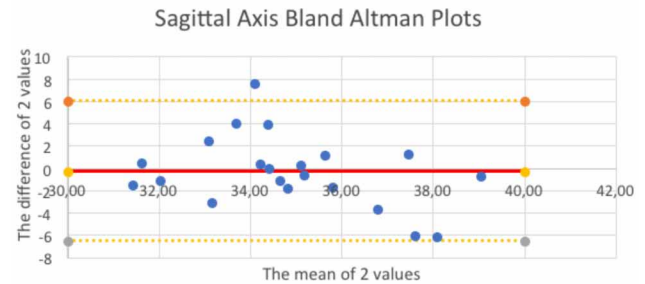


Fig. 2. Validity analysis on the sagittal axis.

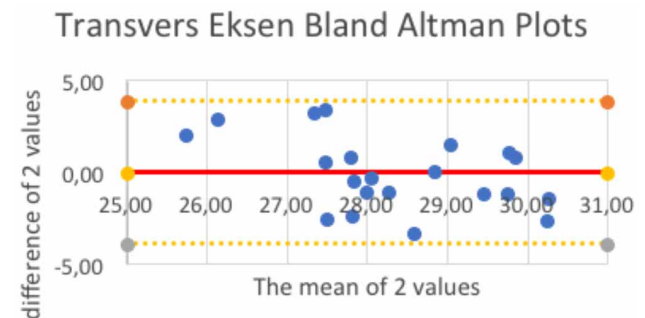


Fig. 3 . Validity analysis on the transverse axis.

After these data obtained, the reliability of the calculation of foramen magnum diameters using orbital ratios was examined (Table III). For reliability, the Intraclass Correlation Coeffidency (ICC) test was applied. According to this test, there was a moderate agreement between Orbita_{RR} and foramen magnum on the sagittal axis. On the transverse axis, there was a moderate agreement between Orbita_{RR} and foramen magnum.

FM Index=1.23±0.008 (mean±SD) (95% confidence interval) [CI] = 1.197-1.270.

Orbit Index=87.02±4.43 (mean±SD) (95% confidence interval [CI] was calculated as 85.00-89.04).

Table III. Reliability analysis between orbita_{RR} and foramen magnum_{RR}.

| Measured Morphometric Parameter | ICC | 95 % Coiffence | Sig (p.) |
|---------------------------------|-------|----------------|----------|
| Length | 0,429 | -0,484-0,767 | 0,104 |
| Width | 0,411 | -0,571-757 | 0,127 |

ICC: Intraclass Correlation Coeffidency, RR: Related Ratio

DISCUSSION

Chiari malformation, hypoplasia, clefts, aplasia, tonsillar herniation and many other pathologies and malformations are associated with FM. Morphometric measurements of FM are of great importance for clinicians in the diagnosis of skull base pathologies and in the selection of appropriate surgery (Basaran *et al.*, 2018; Rai *et al.*, 2018).

Studies related to FM are generally in the form of length and width measurements and volume measurements (Acer *et al.*, 2006; Babu *et al.*, 2012; Meral *et al.*, 2020). In our study, we sought an answer to the question of whether the dimensions of FM, which is an important structure due to its close proximity to vital organs, can be estimated using O measurements. We also investigated how reliable and valid it would be to reach FM dimensions from O dimensions. In this respect, our study may be the first study in the literature.

Ulçay *et al.* (2021) found FM width 28.14 ± 1.77 mm and FM length 35.81 ± 7.56 in their study with 60 Turkish skulls. We also found FM width 28.35 ± 1.91 mm and FM length 34.99 ± 3.05 mm in our study. The FM index we obtained from our study and the FM index we evaluated according to the results of Tuncay *et al.*'s study are in the 95 % confidence interval. We found that the FM dimensions and index results were consistent with our study.

Bahsi *et al.* (2021) reported the FM length as 36.75 ± 2.50 mm and the FM width as 32.55 ± 2.93 mm in their study on the images of 400 individuals. According to the results of the study, the FM index we evaluated is smaller than ours. We think that the difference between FM dimensions and index obtained from the study and the results of our study may be due to the method difference.

Mas *et al.* (2018) reported an average length of 34.38 ± 2.38 mm and a transverse diameter of 28.95 ± 2.19 mm in the study in which they compared the FM area by calculating with three different methods. The mean values of FM diameters were similar to our study, and the FM index we evaluated according to the results of the study was close to the confidence interval.

In which the FM index was calculated, Zdilla *et al.* (2017) in their study on 152 FM images, the mean width of FM in women was 32.02 ± 2.31 mm, and the mean length was 36.38 ± 3.933 mm; mean width in males was 33.58 ± 2.62 mm, and mean length was 38.56 ± 3.21 mm. In addition, the mean width of all FMs was reported as 32.45 ± 3.04 mm and the mean length as 37.11 ± 3.95 mm. In the results of this

study, similar to other studies, it is seen that FM dimensions in men are larger. We did not discriminate by sex in our study. While the FM index we obtained was 1.23 ± 0.08 , the FM index of this study was 1.14. We believe that this difference arises from the study of FM dimensions in bones of different races.

The mean FM length was 35.1 ± 3.2 mm, and the width was 29.3 ± 2.5 mm, in the study conducted on skull images of 247 adults from the Jordanian community. FM index is reported as 1.20 ± 0.10 . Both FM dimensions and FM index are similar to our study. The index of the study is in the confidence interval (95 % CI [1.19-1.27]) (Samara *et al.*, 2017).

Revankar *et al.* (2020) reported the mean length of FM as 34.36 ± 3.13 mm and width as 28.48 ± 3.97 mm in 40 Indian skull bones of unknown sex and age. The FM index was calculated as 1.2345 ± 0.180 . Both the FM dimensions and the FM index results in the study are compatible with the results of our study. In this study, the FM index is in the confidence interval.

Chethan *et al.* (2012) determined the mean length and width of FM in 53 skull bones as 31 ± 2.4 mm and 25.2 ± 2.4 mm, respectively. They reported the mean foramen magnum index as 1.2 ± 0.1 . Both the FM dimensions and the FM index results in the study are compatible with the results of our study. In this study, the FM index is close to our index (1.23 ± 0.08) and is in the confidence interval.

Naqshi *et al.* (2017) measured the length, width, and area of FM in 25 skull bones. They reported the length of the FM as 3.16 ± 0.216 cm and the width as 2.65 ± 0.212 cm. According to the results of the study, the FM index that we evaluated is in the confidence interval. The results are compatible with our study.

We determined that the measurement results and FM index of FM dimensions obtained from our study and FM dimensions and index values in the literature were similar. We thought that the similarity in shape between the structures in the cranium would also include dimensional harmony. Ulçay *et al.* (2021) investigated that there is a concordance between FM dimensions and cranium dimensions, similar to the hypothesis of our study. They found the ratio of cranium width to FM width to be 4.62 ± 0.35 [95 % CI: 4.52-4.70] and the ratio of cranium length to FM length as 4.62 ± 0.50 [95 % CI: 4.49-4.76], almost equal. This study supports our hypothesis that "there may be excellent harmony and proportions between structures with similar shape in the cranium". We also sought an answer to the question of whether FM dimensions can be reached from O

dimensions. We have come across many studies in the literature about the dimensions and area of the orbita (Hussmann & Samson, 2011; Kaplanoglu *et al.*, 2013; Patra *et al.*, 2021).

In a study with radiographic images of 200 patients, the height and width of the orbits were as follows: mean right orbital height 3.40 ± 1.80 cm and mean width 4.31 ± 2.04 cm; mean left orbital height was 3.23 ± 1.40 cm and mean width was 4.27 ± 2.02 cm. When the heights and widths of the right and left orbits were statistically analyzed, the right orbit was wider and higher than the left, but the difference was insignificant ($p > 0.05$). The O index was 81.5 ± 5.30 for right O and 80.75 ± 4.80 for left O. When the right and left O indices were compared, it was found that the O index on the right side was higher than the left side, but the difference was statistically insignificant ($p > 0.05$) (Patra *et al.*, 2021).

Kaplanoglu *et al.* (2013) found that the width of the right orbit was greater than that of the left in a study of 280 patients' CT images. The orbital dimensions of the males were wider and longer than the females. The right O index was smaller than the left orbital index, and there was no difference between the indexes and sexes ($p > 0.05$). In the study, the width of the right orbit was 45.3 ± 2.3 mm, and the height was 38.2 ± 2.7 mm; Left O width was 45 ± 2.4 mm and height 38.2 ± 2.7 mm. Right O index was 84.5 ± 6.2 , left O index was 85.2 ± 6.7 . Husmann & Samson (2011) found in their study that women had a higher orbital index. In other studies, this index is higher in males (Patra *et al.*, 2021). We speculate that these differences are more due to ethnic differences than sex.

Kanjani *et al.* (2019) found that the right orbital length was 30.65 ± 1.32 mm in men; they reported the width as 32.61 ± 1.93 mm. In women, it was reported that the length was 28.68 ± 1.79 mm and the width was 30.31 ± 1.36 mm.

In our study, we measured mean right O length of 34.74 ± 2.11 mm and O width as 39.93 ± 1.68 mm. The O index was 87.02 ± 4.43 95% CI [85.00-89.04]. We saw that the results of the orbita studies did not show any similarity. We believe that the reason for this is due to the change in O sizes of different races.

CONCLUSIONS

In our study, we found that there is a magnificent harmony between the length and width of FM and O. While the lengths in the sagittal plane were close between these

two structures, we found that the width measurements in the coronal plane were approximately 1.40 times larger than the FM width. In addition, we proved that this agreement is statistically safe and valid. In our study, we have shown that FM, which is very important clinically, can be estimated without directly reaching its dimensions. Conducting similar studies in different races and with more samples will strengthen the contribution to the literature.

ACKNOWLEDGMENTS. As the authors, we thank the bodies we used for research purposes in our study and their donors.

GULER, H. & YILMAZ, H. Armonía magnífica en medidas morfológicas de órbita y foramen magno. *Int. J. Morphol.*, 41(2):445-450, 2023.

RESUMEN: El foramen magno (FM) es el componente clave de la unión craneovertebral, que conecta el tronco encefálico y el bulbo raquídeo y está estrechamente relacionado con las estructuras vitales. Las dimensiones FM son de gran importancia clínica. Teniendo en cuenta la similitud de forma entre FM y órbitas, consideramos que podría haber una relación entre las longitudes (diámetro sagital) y las anchuras (diámetro transversal) de estas estructuras. Dado que no es posible llegar al FM directamente, establecimos nuestra hipótesis y calculamos las dimensiones del foramen magno a partir de mediciones orbitales antes de proceder a costosas pruebas. También investigamos esta armonía en los cráneos que usamos en el estudio. En el estudio, se utilizaron 21 huesos de cráneo secos de la población turca. Se realizaron mediciones FM y de longitud y anchura orbitales. Para las mediciones se utilizó un calibrador digital de precisión. Se realizaron análisis estadísticos de validez y confiabilidad para probar la concordancia entre las mediciones. Encontramos que la longitud de la órbita y FM en el plano sagital es cercana entre sí, con 34.74 ± 2.11 mm y 34.99 ± 3.0 mm, y el ancho de la órbita en el plano coronal es aproximadamente 1,40 veces el ancho de la FM. Demostramos que la estimación de las dimensiones FM basadas en mediciones orbitales también es estadísticamente válida y segura. Empleando mediciones orbitales, es posible estimar dimensiones FM que son difíciles de alcanzar directamente en humanos vivos.

PALABRAS CLAVE: Foramen magno; Órbita; Morfometría; Predicción; Fiabilidad; Validez.

REFERENCES

- Acer, N.; Sahin, B.; Ekinci, N.; Ergür, H. & Basaloglu, H. Relation between intracranial volume and the surface area of the foramen magnum. *J. Craniofac. Surg.*, 17(2):326-30, 2006.
- Babu, Y. P. R.; Kanchan, T.; Attiku, Y.; Dixit, P. N.; & Kotion, M. S. Sex estimation from foramen magnum dimensions in an Indian population. *J. Forensic Leg. Med.*, 19(3):162-7, 2012.

- Bahsi, I.; Adanir, S. S.; Orhan, M.; Kervancioglu, P.; Büyükbese, Z. S.; Beger, O. & Yalçin, E. D. Anatomical Evaluation of the Foramen Magnum on Cone-Beam Computed Tomography Images and Review of Literature. *Cureus*, 13(11): e19385, 2021.
- Basaran, R.; Efendioglu, M.; Senol, M.; Ozdogan, S. & Isik, N. Morphometric analysis of posterior fossa and craniovertebral junction in subtypes of Chiari malformation. *Clin. Neurol. Neurosurg.*, 169:1-11, 2018.
- Chethan, P.; Prakash, K. G.; Murlimanju, B. V.; Prashanth, K. U.; Prabhu, V.; Saralaya, V. V.; Krishnamurthy, A.; Somesh, M. S.; & Kumar, C. G. Morphological analysis and morphometry of the foramen magnum: an anatomical investigation. *Turk. Neurosurg.*, 22(4):416-9, 2012.
- Govsa, F.; Ozer, M. A.; Celik, S. & Ozmutaf, N. M. Three-dimensional anatomic landmarks of the foramen magnum for the craniovertebral junction. *J. Craniofac. Surg.*, 22(3):1073-6, 2011.
- Günes, B. E. & Vatanserver A. Türk Toplumunda Foramen Magnum ve Kafa Tabanındaki Oluşumların İlişkileri. *Kafkas J. Med. Sci.*, 8(3):207-13, 2018.
- Husmann, P. R. & Samson D. R. In the eye of the beholder: sex and race estimation using the human orbital aperture. *J. Forensic Sci.*, 56(6):1424-9, 2011.
- Inao, S.; Kuchiwaki, H.; Kanaiwa, H.; Sugito, K.; Banno, M. & Furuse, M. Magnetic resonance imaging assessment of brainstem distortion associated with a supratentorial mass. *J. Neurol. Neurosurg. Psychiatry*, 56(3):280-5, 1993.
- Kaplanoglu, V.; Kaplanoglu, H.; Toprak, U.; Parlak, I. S.; Tatar, I. G.; Deveer, M. & Hekimoglu, B. Anthropometric measurements of the orbita and gender prediction with three-dimensional computed tomography images. *Folia Morphol. (Warsz.)*, 73(2):149-52, 2014.
- Mas, N. G.; Çirpan, S.; Aksu, F.; Demirci, G. N. Y.; Fahrioglu, S. L.; Durmaz, O. & Karabekir, S. Comparison of three methods used for estimating area of foramen magnum. *J. Craniofac. Surg.*, 29(3):792-5, 2018.
- Meral, O.; Toklu, B. B.; Meydan, R.; Kaya, A.; Karadayi, B. & Acar, T. Sex estimation from foramen magnum parameters in adult Turkish population: A computed tomography study. *Leg. Med. (Tokyo)*, 47:101775, 2020.
- Muthukumar, N.; Swaminathan, R.; Venkatesh, G. & Bhanumathy, S. P. A. Morphometric analysis of the foramen magnum region as it relates to the transcondylar approach. *Acta Neurochir. (Wien)*, 147(8):889-95, 2005.
- Naqshi, B. F.; Shahdad, S.; Kawoosa, N. & Shah A. B. Morphological and morphometric study of foramen magnum in dry human skulls of Kashmir. *Glob. J. Res. Anal.*, 6(8):1-3, 2017.
- Patra, A.; Singla, R. K.; Mathur, M.; Chaudhary, P.; Singal, A.; Asghar, A. & Malhotra, V. Morphological and morphometric analysis of the orbital aperture and their correlation with age and gender: a retrospective digital radiographic study. *Cureus*, 13(9):e17739, 2021.
- Rai, R.; Iwanaga, J.; Shokouhi, G.; Loukas, M.; Mortazavi, M. M.; Oskouian, R. J. & Tubbs, R. S. A comprehensive review of the clivus: anatomy, embryology, variants, pathology, and surgical approaches. *Childs Nerv. Syst.*, 34(8):1451-8, 2018.
- Revankar, S.; Shishirkumar, C. N.; Prabhjot, K. C.; Rati, T. & Sharma, D. K. Morphometric analysis of foramen magnum region in adult Indian population. *Eur. J. Mol. Clin. Med.*, 7(10):936-52, 2020.
- Samara, O. A.; Amarin, J. Z.; Badran, D. H.; Al-khayat, O. W.; Suradi, H. H.; Shatarat, A. T. & Hadidi, M. T. Morphometric analysis of the foramen magnum. *Int. J. Morphol.*, 35(4):1270-5, 2017.
- Sung, V.; Bhan, A. & Vernon, S. Agreement in assessing optic discs with a digital stereoscopic optic disc camera (Discam) and Heidelberg retina tomograph. *Br. J. Ophthalmol.*, 86(2):196-202, 2002.
- Tanrisever, S.; Orhan, M.; Bahsi, I. B. & Yalçin, E. D. Anatomical evaluation of the craniovertebral junction on cone-beam computed tomography images. *Surg. Radiol. Anat.*, 42(7):797-815, 2020.
- Ulçay, T.; Kamasak, B.; Görgülü, Ö.; Uzun, A. & Aycan, K. A golden ratio for foramen magnum: an anatomical pilot study. *Folia Morphol. (Warsz.)*, 81(1):220-6, 2021.
- Ulutabanca, H.; Acer, N.; Küçük, A.; Dogan, S.; Tümtürk, A.; Kurtsoy, A.; Sagioglu, A. & Bilgen, M. Chiari type I malformation with high foramen magnum anomaly. *Folia Morphol. (Warsz.)*, 74(3):402-6, 2015.
- Zdilla, M. J.; Russell, M. L.; Bliss, K. N.; Mangus, K. R. & Koons, A. W. The size and shape of the foramen magnum in man. *J. Craniovertebr. Junction Spine*, 8(3):205-21, 2017.

Corresponding author:
Hatice Güler
Department of Anatomy
Faculty of Medicine
Erciyes University
Kayseri
TURKEY

ORCID ID: 0000-0001-9364-5948

E-mail:hsusar@erciyes.edu.tr