

# Maxillary Molar Root Canal Morphology Using Cone-Beam Computed Tomography: An Epidemiological Study from Shandong Province, China

Morfología del Conducto Radicular del Molar Maxilar Mediante Tomografía Computarizada de Haz Cónico: Un Estudio Epidemiológico de la Provincia de Shandong, China

Tongfei Zhang<sup>1</sup>; Mingyue Zhao<sup>1</sup> & Ying Hu<sup>2</sup>

---

ZHANG, T.; ZHAO, M & HU, Y. Maxillary molar root canal morphology using cone-beam computed tomography: An epidemiological study from Shandong province, China. *Int. J. Morphol.*, 41(3):775-784, 2023.

**SUMMARY:** The objective of this study was to evaluate the maxillary molar root canal morphology in individuals from the Shandong province, China, using cone-beam computed tomography (CBCT) and classify it based on Ahmed *et al.* (2017) classification system to obtain a reference for clinical diagnosis and treatment. From December 2020 to June 2021, we screened CBCT data of 1,619 patients at the Jinan Stomatological Hospital who had been indicated for CBCT because of various oral abnormalities. The root and root canal morphologies of all teeth were statistically analyzed, and the root canal morphology was classified based on Ahmed *et al.* (2017) classification system. In the maxillary molars, three roots were the most common, accounting for 99.24 % and 74.61 % of all maxillary first and second molars, respectively. Two roots were the second most common, accounting for 0.66 % and 17.29 % of all maxillary first and second molars, respectively. Root morphology variation, e.g., fusion or furcation defect, was present in 22 (0.76 %) maxillary first molars and 765 (25.39 %) maxillary second molars, with the most common being mesiobuccal and distobuccal root fusion. Detection rates of a second mesiobuccal canal (MB2) in the maxillary first and second molars were 48.5 % and 26.5 %, respectively. Among age groups, the frequency of MB2 was the highest in the 15–24-year-old group and lowest in the 55–64-year-old group. Bilateral MB2 root canals were present in 64.8 % and 48.4 % of the maxillary first and second molars, respectively. Men and women accounted for 60.6 % and 67.8 % of the maxillary first molars, respectively, and 51.7 % and 45.6 % of the maxillary second molars, respectively. According to Ahmed *et al.* (2017) classification of root canal morphology, 18 and 22 root canal configurations were found in 1,453 right maxillary first molars and 1,444 left maxillary first molars, respectively. The right maxillary first molars showed three two-rooted, 14 three-rooted, and one four-rooted type. The left maxillary first molars showed two one-rooted, six two-rooted, and 14 three-rooted types. According to Ahmed *et al.* (2017) classification of root canal morphology, 43 and 45 root canal configurations were found in 1,507 right maxillary second molars and 1,506 left maxillary second molars, respectively. The right maxillary second molars showed 17 one-rooted, 16 two-rooted, eight three-rooted, and two four-rooted types. The left maxillary second molars showed 19 one-rooted, 13 two-rooted, 12 three-rooted, and one four-rooted type. This study showed that the maxillary molar root canal morphology is diverse in the Shandong province. Ahmed *et al.* (2017) classification system provides a clear description of the root canal morphology. CBCT can be used to study complex root and root canal morphologies.

**KEY WORDS:** Maxillary molars; CBCT; Root canal morphology; Root canal classification system.

---

## INTRODUCTION

Currently, root canal treatment is the most effective method to treat pulpal and periapical lesions. Success of root canal treatment depends on adequate disinfection, shaping, and filling of the root canal system. However, root canal morphology is complex and diverse, making root canal treatment difficult for clinicians (Zheng *et al.*, 2010; Dou *et*

*al.*, 2017). With advancements in clinical technology in recent years, people have developed a deeper understanding of the complexity and variability of the root canal system, such as the presence of primary and secondary root canals, intercanal communication, root canal bifurcation, and an irregular shape of root canals. Rare root canal morphologies,

<sup>1</sup> School of Stomatology, Binzhou Medical University, Yantai 264000, China.

<sup>2</sup> Jinan Stomatological Hospital, Jinan 250001, China.

such as bovine dentition and C-shaped canal, have been reported (Yang *et al.*, 2013; Wu *et al.*, 2017). Differences in the number and morphology of roots and root canals by race, sex, and age have been described (Zhang *et al.*, 2011; Yang *et al.*, 2014; Abarca *et al.*, 2020). Variability in the root canal system and influence of various factors complicate root canal treatment.

Therefore, the root canal system has been the topic of numerous experimental studies and clinical case reports for decades. Weine *et al.* (1969) used sectioning and radiographs to classify root canal configurations within a single root into three types based on the furcation pattern of the primary root canal path from the pulp cavity to the root tip. Vertucci (1984) found that the complexity of the root canal system exceeded that determined by Weine *et al.* (1969) classification and proposed another classification system (Vertucci, 1984).

Vertucci (1984) classification system is the most commonly used root canal morphology classification system. It was formulated based on staining results of 2,400 teeth (Vertucci, 1984). According to this system, the permanent teeth have eight types (types I–VIII) of root canal configurations. However, further understanding of the root canal system has revealed that Vertucci (1984) classification system does not accurately describe the complex and varying root canal morphology. In the maxillary molars, the most common form is three roots with three canals, with the incidence of a second mesiobuccal root canal (MB2) exceeding 50 % (Yang *et al.*, 2020). However, the maxillary molars can also have two root canals in the palatal root (Ghoncheh *et al.*, 2017). In such cases, Vertucci (1984) classification system is limited. Further, the classification of the internal tooth anatomy is inconsistent. For example, in the maxillary premolars with three root canals, Vertucci classification is type VIII, with the root canals described as separate and distinct, extending from the pulp cavity to the root apex, but without any description of whether these root canals are present in one, two, or three roots, leading to varying maxillary premolar root morphologies referred to as type VIII in most studies.

Owing to limitations in Vertucci (1984) classification system, we adopted Ahmed *et al.* (2017) classification system. Ahmed *et al.* (2017) classification is more comprehensive and practical because it describes different root canal anatomies of single-, double-, and multirooted teeth separately. The aim of the present study was to investigate the root and root canal configurations of the maxillary first and second molars, incidence of MB2, and symmetry in root and root canal morphologies between the maxillary first and second molars in the Shandong population using cone-beam computed tomography (CBCT).

## MATERIAL AND METHOD

**Study participants.** From December 2020 to June 2021, we screened imaging data of 1,646 patients, including 5,910 maxillary molars, at the Jinan Stomatological Hospital who had been indicated for CBCT because of various oral abnormalities.

### Inclusion criteria

Inclusion criteria for the teeth were: (1) complete root formation; (2) absence of periapical lesions; (3) absence of endodontic treatment; (4) absence of root resorption or calcification; (5) absence of artificial or post crowns; and (6) good CBCT image quality. The exclusion criterion was the presence of pathological tooth defects.

**Research equipment and image evaluation.** CBCT was performed using NewTom 5G XL (NewTom, Italy) in the supine position, significantly enhancing the stability and yielding a clear three-dimensional image. CBCT has advantages of approximately 10 times lesser X-ray dose exposure and better diagnostic images for bone tissue than conventional multislice spiral CT.

An oral radiologist and an endodontist evaluated all images simultaneously. Disagreements were resolved through discussions, and consensus was established. CBCT scans of all maxillary molars were analyzed using CBCT software. The toolbar was adjusted on the axial slice image analysis software, including brightness, contrast, and magnification. The teeth (maxillary first and second molar) centers were determined. Images were analyzed in the sagittal, axial, and coronal planes. After recording the sex and age of the patients, the number of roots, root canal morphology, and Ahmed *et al.* (2017) root canal morphology type of each molar were determined.

### Study content

**Root morphology.** Based on the root morphology, the maxillary molars were divided into one-, two-, three-, and four-rooted types. The one-rooted type showed mesiobuccal, distobuccal, and palatal roots fused into a single root. The two-rooted type showed the following variations: (1) palatal root and fusion of mesiobuccal and distobuccal roots; (2) mesiobuccal root and fusion of palatal and distobuccal roots; and (3) distobuccal root and fusion of palatal and mesiobuccal roots. The three-rooted type showed mesiobuccal, distobuccal, and palatal roots. The four-rooted type showed a palatal root bifurcating into mesiopalatal and distopalatal roots and mesiobuccal and distobuccal roots.

### Root canal morphology

**MB2.** The number of MB2 in the maxillary first and second molars was counted and tabulated by patient age and sex. Age groups were 15–24, 25–34, 35–44, 45–54, 55–64, and >65 years. The proportion of MB2 in the maxillary first and second molars in each age group was analyzed. The number of MB2 was recorded, and the probabilities of unilateral and bilateral occurrences of MB2 in the maxillary first and second molars were determined.

Ahmed *et al.* (2017) root canal morphology classification system. We used Ahmed *et al.* (2017) root canal morphology classification system, which classifies teeth based on three parameters: tooth number (“TN”), root number (“R”), and root canal configuration. The tooth number is represented using any numbering system, such as the Fédération Dentaire Internationale notation, Universal Numbering System, or Palmer notation. When the exact tooth number cannot be determined, the abbreviation of the tooth type is used, e.g., “MFM” for the maxillary first molar. The root number is also represented using the same numbering system so as to distinguish the same root canal configurations among different roots. The root number is written as a superscript and precedes the tooth

number. In determining the number of roots, any bifurcation of a root, whether in the cervical, middle, or apical third, results in a count of two roots. Similarly, a trifurcation results in a count of three roots, and so on. Finally, for the root canal configuration, each root is recorded separately, and the continuous course of root canal change is defined, starting from the root canal orifice (O), passing through the root canal (C), and reaching the apical foramen (F). Single- and multi-rooted teeth are represented as TNO-C-F and R1O-C-FR2O-C-FRnO-C-F, respectively. Table I shows the details.

Table I. The representation of Ahmed's root canal classification system

Tooth type	Code
Single-rooted	1 TNO-C-F
Double-rooted	2TN R1O-C-F R2O-C-F
Multirrooted	nTN R1O-C-FR2O-C-FRnO-C-F

TN, Tooth number; R, Root; O, Orifice; C, Canal; F, Foramen.

**Statistical analysis.** Statistical analyses were performed using SPSS 29.0 software (SPSS Inc, Chicago, IL). Count data are expressed as the number (%) of cases. The chi-square test was performed for inter-group comparisons. A p-value < 0.05 was set to indicate statistical significance.

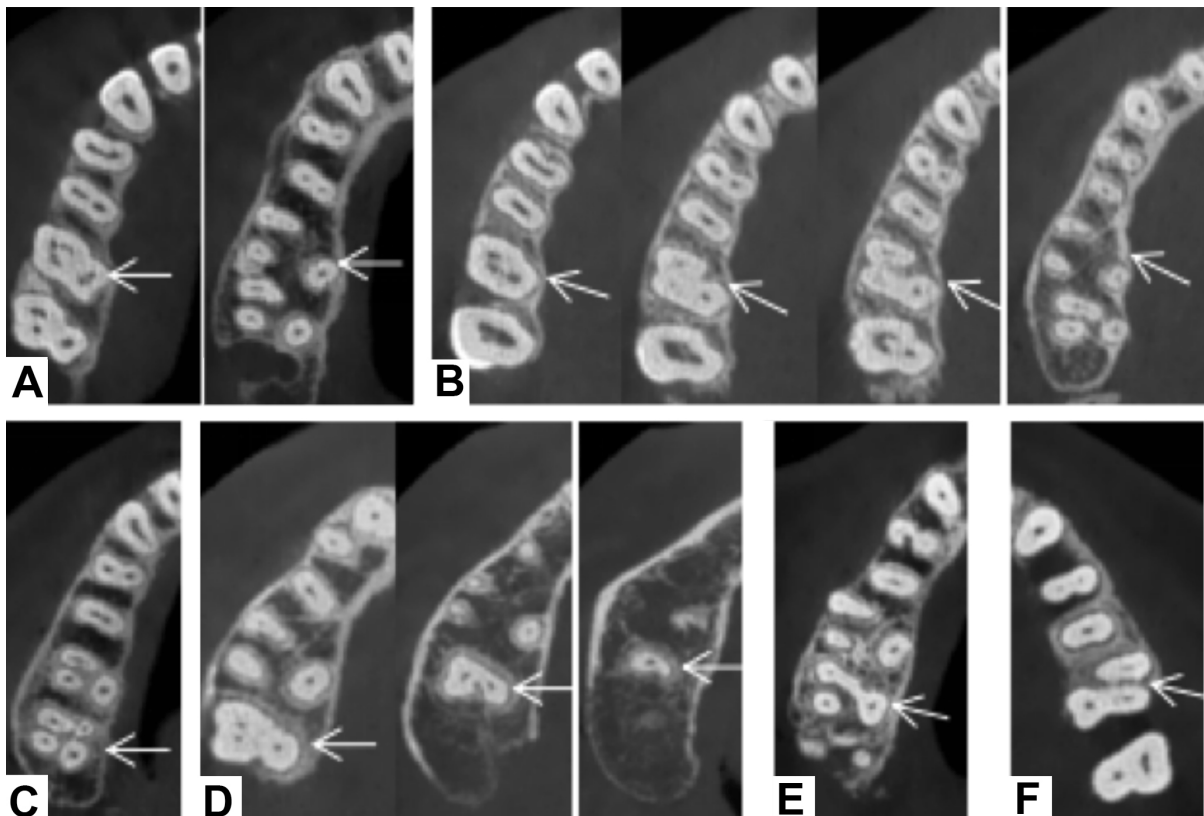


Fig. 1. Some examples of special root canal types. A) 316MB3-2DB2-1P2-1; B) 316MB2-1-2-1DB1P1; C) 417MB1DB1MP1DP1; D) 1 27 3-2-1; E) 217MBP2DB1; F) 227MB1DBP2

## RESULTS

We screened imaging data of 1,619 patients, including 604 (37.3 %) men and 1,015 (62.7 %) women. A total of 5,910 maxillary molars were collected, including 2,897 maxillary first molars (1,453 right and 1,444 left) and 3,013 maxillary second molars (1,507 right and 1,506 left) (Fig. 1).

Root canal morphology distribution. Among the maxillary molars, the three-rooted type was the most common, found in 99.24 % and 74.61 % of the maxillary first and second molars, respectively. The two-rooted type was found in 0.66 % and 17.29 % of the maxillary first and second molars, respectively. The one- and four-rooted types were the least common. Table II shows the number (%) of each root canal morphology type in the maxillary first and second molars by sex. The number of roots of the maxillary first molars did not differ between the sexes ( $c2 = 2.801$ ,  $p = 0.423$ ), whereas that of the maxillary second molars differed between the sexes ( $c2 = 68.591$ ,  $p < 0.001$ ).

Root morphology variation, e.g., fusion or furcation defect, was present in 22 (0.76 %) maxillary first molars and 765 (25.39 %) maxillary second molars, with the most

common being mesiobuccal and distobuccal root fusion (63.6 % and 42.4 %, respectively). The mesiobuccal and palatal roots were fused in 13.6 % of the maxillary first molars, and all roots were fused in 29.9 % of the maxillary second molars. The lowest detection rate was of palatal root bifurcation in the maxillary first molars (one [4.5 %] case) and distobuccal and palatal root fusion in the maxillary second molars (1.7 %). Table III shows the root morphology variations of the maxillary molars. The incidence of root morphology variation differed significantly between the sexes ( $c2 = 13.230$ ,  $p = 0.01$ ).

**MB2.** The detection rates of MB2 in the maxillary first and second molars were 48.5 % and 26.5 %, respectively. Among different age groups, the frequency of MB2 was the highest in the 15–24-year-old group and the lowest in the 55–64-year-old group. Table IV shows the frequency of MB2 in all age groups. The detection rate of MB2 in the maxillary molars did not differ significantly among age groups ( $c2 = 0.973$ ,  $p = 0.965$ ). MB2 in the maxillary first molars was found in 51.9 % and 46.5 % of men and women, respectively, while that in the maxillary second molars was found in 33.9 % and 22.1 % of men and women, respectively. The detection rate of MB2 in the maxillary molars did not differ significantly between the sexes ( $c2 = 0.971$ ,  $p = 0.324$ ).

Table II. Root types of maxillary molars.

	Root type	Male		Female		Total	
		n	%	n	%	n	%
Maxillary first molars	Single root	0	0	2	0.11	2	0.07
	Double roots	5	0.46	14	0.77	19	0.66
	Three roots	1078	99.54	1797	99.06	2875	99.24
	Four roots	0	0	1	0.06	1	0.03
	Total	1083	100	1814	100	2897	100
Maxillary second molars	Single root	47	4.18	182	9.64	229	7.6
	Double roots	140	12.44	381	20.18	521	17.29
	Three roots	931	82.76	1317	69.76	2248	74.61
	Four roots	7	0.62	8	0.42	15	0.5
	Total	1125	100	1888	100	3013	100

n = tooth number; % = frequency of number of roots.

Table III. Root fusion of maxillary molars.

Root type	Maxillary first molars		Maxillary second molars	
	n	%	n	%
All roots fused	2	9.1	229	29.9
MB and DB are fused	14	63.6	324	42.4
MB and P are fused	3	13.6	184	24.1
DB and P are fused	2	9.1	13	1.7
P root bifurcation	1	4.5	15	1.9
Total	22	100	765	100

n = tooth number; % = frequency of number of roots.

Bilateral MB2s were found in 64.8 % and 48.4 % of the maxillary first and second molars, respectively. Bilateral MB2s in the maxillary first molars were found in 60.6 % and 67.8 % of men and women, respectively, while in the maxillary second molars were found in 51.7 % and 45.6 % of men and women, respectively. The detection rate of bilateral MB2s in the maxillary molars did not differ significantly between the sexes ( $c2 = 0.743$ ,  $p = 0.389$ ). Table V shows the frequency of bilateral MB2s in men and women.

Table IV. Detection rate of MB2 in maxillary molars

		Age group						Sex		Total
		15-24	25-34	35-44	45-54	55-64	≥65	Male	Female	
Maxillary first molars	n	745	934	545	462	201	10	1083	1814	2897
	n of MB2	397	474	258	193	79	4	562	843	1405
	%	53.3	50.7	47.3	41.8	39.3	40	51.9	46.5	48.5
Maxillary second molars	n	764	976	574	490	201	8	1125	1888	3013
	n of MB2	234	247	136	133	46	2	381	417	798
	%	30.6	25.3	23.7	27.1	22.9	25	33.9	22.1	26.5

n = tooth number; % = frequency of number of roots.

Ahmed *et al.* (2017) root canal morphology classification of the maxillary first molars. In 1,453 right and 1,444 left maxillary first molars, 18 and 22 types of root canal configurations were found according to Ahmed *et al.* (2017) root canal morphology classification system, respectively. The right maxillary first molars showed three two-rooted, 14 three-rooted, and one four-rooted type. The left maxillary first molars showed two one-rooted, six two-rooted, and 14 three-rooted types. The most common root

canal configurations of the right maxillary first molars were 316MB1DB1P1 (720, 49.6 %), 316MB2DB1P1 (453, 31.2 %), and 316MB2-1DB1P1 (216, 14.9 %). The most common root canal configurations of the left maxillary first molars were 326MB1DB1P1 (747, 51.7 %), 326MB2DB1P1 (451, 31.2 %), and 326MB2-1DB1P1 (187, 13.0 %). Tables VI and VII show the age distribution of root canal morphologies of the right and left maxillary first molars, respectively.

Table V. Bilateral symmetry of MB2 in maxillary molars (n, %),

	Sex	Male		Female		Total	
		MB2	Single	Double	Single	Double	Single
Maxillary first molars	n	127	195	149	314	276	509
	%	60.6		67.8		64.8	
Maxillary second molars	n	114	122	147	123	261	245
	%	51.7		45.6		48.4	

n = tooth number; % = frequency of number of roots.

Table VI. Morphological distribution of Ahmed root canal in right maxillary first molar .

Root canal	Age group						Total
	15-24	25-34	35-44	45-54	55-64	≥65	
<sup>2</sup> 16B <sup>1</sup> P <sup>1</sup>	1 (0.3)	1 (0.2)		2 (0.9)			4 (0.3)
<sup>2</sup> 16B <sup>2</sup> P <sup>1</sup>	2 (0.5)	1 (0.2)		1 (0.4)	1(1.0)		5 (0.3)
<sup>2</sup> 16MBP <sub>2</sub> DB <sup>1</sup>	1 (0.3)						1 (0.1)
<sup>3</sup> 16MB <sup>1</sup> D <sub>B</sub> 1P <sup>1</sup>	166 (44.4)	223 (47.1)	139 (51.3)	130 (55.3)	60 (61.9)	2 (66.7)	720 (49.6)
<sup>3</sup> 16MB <sup>1</sup> D <sub>B</sub> 1P <sup>2</sup>		1 (0.2)					1 (0.1)
<sup>3</sup> 16MB <sup>1-2</sup> D <sub>B</sub> 1P <sup>1</sup>	3 (0.8)	8 (1.7)	3 (1.1)	1 (0.4)	2 (2.1)		17 (1.2)
<sup>3</sup> 16MB <sup>1-2-1</sup> D <sub>B</sub> 1P <sup>1</sup>	4 (1.1)	13 (2.7)	2 (0.7)	2 (0.9)	2 (2.1)		23 (1.6)
<sup>3</sup> 16MB <sup>1-2-1</sup> D <sub>B</sub> 1P <sup>2-1</sup>					1 (1.0)		1 (0.1)
<sup>3</sup> 16MB <sup>2</sup> DB <sup>1</sup> P <sup>1</sup>	139 (37.2)	155 (32.8)	86 (31.7)	57 (24.3)	16 (16.5)		453 (31.2)
<sup>3</sup> 16MB <sup>2</sup> D <sub>B</sub> 1P <sup>2-1</sup>			1 (0.4)				1 (0.1)
<sup>3</sup> 16MB <sup>2-1</sup> D <sub>B</sub> 1P <sup>1</sup>	55 (14.7)	67 (14.2)	39 (14.4)	39 (16.6)	15 (15.5)	1 (33.3)	216 (14.9)
<sup>3</sup> 16MB <sup>2-1</sup> D <sub>B</sub> 1P <sup>2-1</sup>			1 (0.4)	2 (0.9)			3 (0.2)
<sup>3</sup> 16MB <sup>2-1</sup> D <sub>B</sub> 2-1P <sup>1</sup>		2 (0.4)		1 (0.4)			3 (0.2)
<sup>3</sup> 16MB <sup>2-1-2</sup> D <sub>B</sub> 1P <sup>1</sup>	1 (0.3)						1 (0.1)
<sup>3</sup> 16MB <sup>2-1-2-1</sup> D <sub>B</sub> 1P <sup>1</sup>		1 (0.2)					1 (0.1)
<sup>3</sup> 16MB <sup>3-2</sup> D <sub>B</sub> 1P <sup>1</sup>	1 (0.3)						1 (0.1)
<sup>3</sup> 16MB <sup>3-2</sup> D <sub>B</sub> 2-1P <sup>2-1</sup>		1 (0.2)					1 (0.1)
<sup>4</sup> 16MB <sup>1</sup> DB <sup>1</sup> MP <sup>1</sup> DP <sup>1</sup>	1 (0.3)						1 (0.1)
Total	374	473	271	235	97	3	1453

N = numbers in bracket; % = percentage.

Ahmed *et al.* (2017) root canal morphology classification of the maxillary second molars. In 1,507 right and 1,506 left maxillary second molars, 43 and 45 root canal configurations were found according to Ahmed *et al.* (2017) root canal morphology classification system, respectively. The right maxillary second molars showed 17 one-rooted, 16 two-rooted, eight three-rooted, and two four-rooted types. The left maxillary second molars showed 19 one-rooted, 13 two-rooted, 12 three-rooted, and one four-

rooted type. The most common root canal configurations of the right maxillary second molars were 317MB1DB1P1 (702, 46.6 %), 317MB2-1DB1P1 (168, 11.1 %), and 317MB2DB1P1 (187, 12.4 %). The most common root canal configurations of the left maxillary second molars were 327MB1DB1P1 (744, 49.4 %), 327MB2-1DB1P1 (171, 11.4 %), and 327MB2DB1P1 (143, 9.5 %). Tables VIII and IX show the age distribution of root canal configurations of the right and left maxillary second molars, respectively.

Table VII. Morphological distribution of Ahmed root canal in left maxillary first molar (n, %)

Root canal	Age group						Total
	15-24	25-34	35-44	45-54	55-64	≥65	
<sup>1</sup> 26 <sup>3-2</sup>	1 (0.3)						1 (0.1)
<sup>1</sup> 26 <sup>3-1</sup>					1 (1.0)		1 (0.1)
<sup>2</sup> 26B <sup>1</sup> P <sup>1</sup>			1 (0.4)				1 (0.1)
<sup>2</sup> 26B <sup>1-2-3</sup> P <sup>1</sup>				1 (0.4)			1 (0.1)
<sup>2</sup> 26B <sup>2</sup> P <sup>1</sup>	1 (0.3)			1 (0.4)			2 (0.1)
<sup>2</sup> 26B <sup>2-1</sup> P <sup>1</sup>	1 (0.3)						1 (0.1)
<sup>2</sup> 26MB <sup>1</sup> DBP <sup>2</sup>				2 (0.9)			2 (0.1)
<sup>2</sup> 26MBP <sup>2</sup> DB <sup>1</sup>		1 (0.2)	1 (0.4)				2 (0.1)
<sup>3</sup> 26MB <sup>1</sup> DB <sup>1</sup> P <sup>1</sup>	174 (46.9)	232 (50.3)	146 (53.3)	131 (57.7)	60 (57.7)	4 (57.1)	747 (51.7)
<sup>3</sup> 26MB <sup>1</sup> DB <sup>1</sup> P <sup>2-1</sup>				1 (0.4)			1 (0.1)
<sup>3</sup> 26MB <sup>1</sup> DB <sup>1-2-1</sup> P <sup>1</sup>		1 (0.2)					1 (0.1)
<sup>3</sup> 26MB <sup>1-2</sup> DB <sup>1</sup> P <sup>1</sup>	2 (0.5)	6 (1.3)	2 (0.7)	4 (1.8)	1 (1.0)		15 (1.0)
<sup>3</sup> 26MB <sup>1-2-1</sup> DB <sup>1</sup> P <sup>1</sup>	2 (0.5)	7 (1.5)	2 (0.7)	3 (1.3)	7 (6.7)	1 (14.3)	22 (1.5)
<sup>3</sup> 26MB <sup>2</sup> DB <sup>1</sup> P <sup>1</sup>	145 (39.1)	148 (32.1)	83 (30.3)	54 (23.8)	21 (20.2)		451 (31.2)
<sup>3</sup> 26MB <sup>2</sup> DB <sup>1-2</sup> P <sup>1</sup>		1 (0.2)				1 (14.3)	2 (0.1)
<sup>3</sup> 26MB <sup>2</sup> DB <sup>1-2-1</sup> P <sup>1</sup>		1 (0.2)					1 (0.1)
<sup>3</sup> 26MB <sup>2</sup> DB <sup>2</sup> P <sup>1</sup>			1 (0.4)				11 (0.1)
<sup>3</sup> 26MB <sup>2-1</sup> DB <sup>1</sup> P <sup>1</sup>	45 (12.1)	62 (13.4)	36 (13.1)	30 (13.2)	13 (12.5)	1 (14.3)	187 (13.0)
<sup>3</sup> 26MB <sup>2-1</sup> DB <sup>2-1</sup> P <sup>1</sup>		1 (0.2)			1 (1.0)		2 (0.1)
<sup>3</sup> 26MB <sup>2-1</sup> DB <sup>1</sup> P <sup>2-1</sup>			1 (0.4)				1 (0.1)
<sup>3</sup> 26MB <sup>2-3-1</sup> DB <sup>1</sup> P <sup>1</sup>			1 (0.4)				1 (0.1)
<sup>3</sup> 26MB <sup>3-2</sup> DB <sup>1</sup> P <sup>2-1</sup>		1 (0.2)					1 (0.1)
Total	371	461	274	227	104	7	1444

n= numbers in bracket; % = percentage.

## DISCUSSION

Adequate root canal preparation and filling are key to the success of root canal treatment. The position and shape of the maxillary molars vary widely, and the root canal orifices may be hidden. Root canal calcification or curvature or the presence of MB2 increases the difficulty

of root canal treatment. Missing a root canal also leads to treatment failure. Therefore, a clear understanding of the anatomical morphology of the root and root canal system of the maxillary molars can improve the success rate of root canal treatment.

Table VIII. Morphological distribution of Ahmed root canals in right maxillary second molars (n, %).

Root canal	Age group						Total
	15-24	25-34	35-44	45-54	55-64	≥65	
<sup>1</sup> 17 <sup>1</sup>	3(0.8)	7 (1.4)		4 (1.7)	2 (2.0)		16 (1.1)
<sup>1</sup> 17 <sup>1-2</sup>		3 (0.6)					3 (0.2)
<sup>1</sup> 17 <sup>1-2-1</sup>	2 (0.5)	7 (1.4)	1 (0.3)	2 (0.8)			12 (0.8)
<sup>1</sup> 17 <sup>1-2-3-2</sup>		1 (0.2)					1 (0.1)
<sup>1</sup> 17 <sup>1-2-3-2-1</sup>			1 (0.3)				1 (0.1)
<sup>1</sup> 17 <sup>1-3</sup>					1 (1.0)		1 (0.1)
<sup>1</sup> 17 <sup>1-3-2-1</sup>	1 (0.3)						1 (0.1)
<sup>1</sup> 17 <sup>2</sup>	6 (1.6)	3 (0.6)	2 (0.7)	4 (1.7)	1 (1.0)		16 (1.1)
<sup>1</sup> 17 <sup>2-1</sup>	1 (0.3)	3 (0.6)	3 (1.0)	2 (0.8)	1 (1.0)		10 (0.7)
<sup>1</sup> 17 <sup>2-3-2</sup>			1 (0.3)	2 (0.8)			3 (0.2)
<sup>1</sup> 17 <sup>3</sup>	7 (1.8)	10 (2.0)	3 (1.0)	1 (0.4)	2 (2.0)		23 (1.5)
<sup>1</sup> 17 <sup>3-1</sup>	1 (0.3)	7 (1.4)	1 (0.3)	2 (0.8)			11 (0.7)
<sup>1</sup> 17 <sup>3-2</sup>	3 (0.8)	4 (0.8)	2 (0.7)	1 (0.4)	1 (1.0)		11 (0.7)
<sup>1</sup> 17 <sup>3-2-1</sup>			2 (0.7)	1 (0.4)			3 (0.2)
<sup>1</sup> 17 <sup>3-4-3-2-1</sup>			1 (0.3)				1 (0.1)
<sup>1</sup> 17 <sup>4-1</sup>	1 (0.3)						1 (0.1)
<sup>1</sup> 17 <sup>4-2</sup>		1 (0.2)					1 (0.1)
<sup>2</sup> 17 B <sub>1</sub> P <sup>1</sup>	20 (5.2)	23 (4.7)	12 (4.2)	8 (3.3)	4 (4.0)		67 (4.4)
<sup>2</sup> 17 B <sub>1-2</sub> P <sup>1</sup>	4 (1.0)	3 (0.6)	2 (0.7)	1 (0.4)			10 (0.7)
<sup>2</sup> 17 B <sub>1-2-1</sub> P <sup>1</sup>	2 (0.5)	4 (0.8)	1 (0.3)	1 (0.4)	2 (2.0)		10 (0.7)
<sup>2</sup> 17 B <sub>1-2-3</sub> P <sup>1</sup>	1 (0.3)						1 (0.1)
<sup>2</sup> 17 B <sub>1-3</sub> P <sup>1</sup>	1 (0.3)						1 (0.1)
<sup>2</sup> 17 B <sub>2</sub> P <sup>1</sup>	3 (0.8)	9 (1.8)	3 (1.0)	5 (2.1)	2 (2.0)		22 (1.5)
<sup>2</sup> 17 B <sub>2-1</sub> P <sup>1</sup>	10 (2.6)	11 (2.2)	13 (4.5)	5 (2.1)	5 (5.0)		44 (2.9)
<sup>2</sup> 17 B <sub>3</sub> P <sup>1</sup>	1 (0.3)		1 (0.3)				2 (0.1)
<sup>2</sup> 17 B <sub>3-2-1</sub> P <sup>1</sup>			2 (0.7)				2 (0.1)
<sup>2</sup> 17 M B <sup>1</sup> D BP <sup>2</sup>	2 (0.5)		3 (1.0)		1 (1.0)		6 (0.4)
<sup>2</sup> 17 M B <sup>1</sup> D BP <sup>2-1</sup>					1 (1.0)		1 (0.1)
<sup>2</sup> 17 M B P <sup>2</sup> D B <sup>1</sup>	24 (6.3)	30 (6.1)	13 (4.5)	13 (5.4)	8 (8.0)		88 (5.8)
<sup>2</sup> 17 M B P <sup>2-1</sup> D B <sup>1</sup>		1 (0.2)	2 (0.7)				3 (0.2)
<sup>2</sup> 17 M B P <sup>3</sup> D B <sup>1</sup>	1 (0.3)	1 (0.2)			1 (1.0)		3 (0.2)
<sup>2</sup> 17 M B P <sup>3-2</sup> D B <sup>1</sup>			1 (0.3)		1 (1.0)		2 (0.1)
<sup>2</sup> 17 M B P <sup>4</sup> D B <sup>1</sup>		1 (0.2)					1 (0.1)
<sup>3</sup> 17 M B <sup>1</sup> D B <sup>1</sup> P <sup>1</sup>	160 (41.9)	225 (45.7)	143 (49.5)	127 (52.5)	46 (46.0)	1 (50.0)	702 (46.6)
<sup>3</sup> 17 M B <sup>1-2</sup> D B <sup>1</sup> P <sup>1</sup>	5 (1.3)	4 (0.8)	3 (1.0)	3 (1.2)	1 (1.0)		16 (1.1)
<sup>3</sup> 17 M B <sup>1-2-1</sup> D B <sup>1</sup> P <sup>1</sup>	5 (1.3)	11 (2.2)	8 (2.8)	11 (4.5)	7 (7.0)		42 (2.8)
<sup>3</sup> 17 M B <sup>1-2-1-2-1</sup> D B <sup>1</sup> P <sup>1</sup>		1 (0.2)					1 (0.1)
<sup>3</sup> 17 M B <sup>2</sup> D B <sup>1</sup> P <sup>1</sup>	59 (15.4)	56 (11.4)	29 (10.0)	20 (8.3)	4 (4.0)		168 (11.1)
<sup>3</sup> 17 M B <sup>2-1</sup> D B <sup>1</sup> P <sup>1</sup>	56 (14.7)	62 (12.6)	33 (11.4)	28 (11.6)	7 (7.0)	1 (50.0)	187 (12.4)
<sup>3</sup> 17 M B <sup>2-1</sup> D B <sup>1</sup> P <sup>2-1</sup>				1 (0.4)			1 (0.1)
<sup>3</sup> 17 M B <sup>2-1-2</sup> D B <sup>1</sup> P <sup>1</sup>			1 (0.3)		1 (1.0)		2 (0.1)
<sup>4</sup> 17 M B <sup>1</sup> D B <sup>1</sup> M P <sup>1</sup> D P <sup>1</sup>	2 (0.5)	4 (0.8)	2 (0.7)		1 (1.0)		9 (0.6)
<sup>4</sup> 17 M B <sup>2-1</sup> M P <sup>1</sup> D B <sup>1</sup> D P <sup>1</sup>	1 (0.3)						1 (0.1)
Total	382	492	289	242	100	2	1507

n = numbers in bracket; % = percentage.

In the root morphology of the maxillary molars, the number of roots ranges from one to four, and the most common type is the three-rooted type. The present study's findings of the incidence of three-rooted first molars are consistent with those of Abed *et al.* (2013) The detection rate of the three-rooted type of the maxillary first molars was 99.24 %. While one-, two-, and four-rooted types were rare, one- and four-rooted types were found only in women. The detection rates of the three-, two-, and one-rooted types of the maxillary second molars were 74.61 %, 17.29 %, and 7.60 %, respectively. The four-rooted type was found rarely. The shape or number of the maxillary second molars did not differ between the sexes. Tzeng *et al.* (2020) found that the maxillary first molars mostly had three roots with four canals, and the maxillary second molars mostly had three roots with three canals, consistent with the results of the

present study. Compared to the maxillary first molars, the maxillary second molars had greater root variability, similar to Kim *et al.* (2012)'s study. The detection rates of non-three-rooted maxillary second and first molars were 25.39 % and 0.76 %, respectively. Among them, five variants were found. The most common one was fusion of the mesiobuccal and distobuccal roots, with a detection rate of 63.6 %. In the maxillary second molars, the most common one was fusion of the mesiobuccal and distobuccal roots and a single fused root, with detection rates of 42.4 % and 29.9 %, respectively. Compared to Zhang *et al.* (2011)'s study, the variation rate in the maxillary second molars in this study was lower.

The detection rates of MB2 were 48.5 % and 26.5 % in the maxillary first and molars, respectively, showing a significant difference, consistent with Zheng *et al.* (2020)

Table IX. Morphological distribution of Ahmed root canal in the left maxillary second molar (n, %)

Root canal	Age group					Total
	15-24	25-34	35-44	45-54	55-64	
1 17 <sup>1</sup>	3 (0.8)	7 (1.4)		4 (1.7)	2 (2.0)	16 (1.1)
1 17 <sup>1-2</sup>		3 (0.6)				3 (0.2)
1 17 <sup>1-2-1</sup>	2 (0.5)	7 (1.4)	1 (0.3)	2 (0.8)		12 (0.8)
1 17 <sup>1-2-3-2</sup>		1 (0.2)				1 (0.1)
1 17 <sup>1-2-3-2-1</sup>			1 (0.3)			1 (0.1)
1 17 <sup>1-3</sup>					1 (1.0)	1 (0.1)
1 17 <sup>1-3-2-1</sup>	1 (0.3)					1 (0.1)
1 17 <sup>2</sup>	6 (1.6)	3 (0.6)	2 (0.7)	4 (1.7)	1 (1.0)	16 (1.1)
1 17 <sup>2-1</sup>	1 (0.3)	3 (0.6)	3 (1.0)	2 (0.8)	1 (1.0)	10 (0.7)
1 17 <sup>2-3-2</sup>			1 (0.3)	2 (0.8)		3 (0.2)
1 17 <sup>3</sup>	7 (1.8)	10 (2.0)	3 (1.0)	1 (0.4)	2 (2.0)	23 (1.5)
1 17 <sup>3-1</sup>	1 (0.3)	7 (1.4)	1 (0.3)	2 (0.8)		11 (0.7)
1 17 <sup>3-2</sup>	3 (0.8)	4 (0.8)	2 (0.7)	1 (0.4)	1 (1.0)	11 (0.7)
1 17 <sup>3-2-1</sup>			2 (0.7)	1 (0.4)		3 (0.2)
1 17 <sup>3-4-3-2-1</sup>			1 (0.3)			1 (0.1)
1 17 <sup>4-1</sup>	1 (0.3)					1 (0.1)
1 17 <sup>4-2</sup>		1 (0.2)				1 (0.1)
2 17 B <sup>1</sup> P <sup>1</sup>	20 (5.2)	23 (4.7)	12 (4.2)	8 (3.3)	4 (4.0)	67 (4.4)
2 17 B <sup>1-2</sup> P <sup>1</sup>	4 (1.0)	3 (0.6)	2 (0.7)	1 (0.4)		10 (0.7)
2 17 B <sup>1-2-1</sup> P <sup>1</sup>	2 (0.5)	4 (0.8)	1 (0.3)	1 (0.4)	2 (2.0)	10 (0.7)
2 17 B <sup>1-2-3</sup> P <sup>1</sup>	1 (0.3)					1 (0.1)
2 17 B <sup>1-3</sup> P <sup>1</sup>	1 (0.3)					1 (0.1)
2 17 B <sup>2</sup> P <sup>1</sup>	3 (0.8)	9 (1.8)	3 (1.0)	5 (2.1)	2 (2.0)	22 (1.5)
2 17 B <sup>2-1</sup> P <sup>1</sup>	10 (2.6)	11 (2.2)	13 (4.5)	5 (2.1)	5 (5.0)	44 (2.9)
2 17 B <sup>3</sup> P <sup>1</sup>	1 (0.3)		1 (0.3)			2 (0.1)
2 17 B <sup>3-2-1</sup> P <sup>1</sup>			2 (0.7)			2 (0.1)
2 17 M <sup>1</sup> D <sup>1</sup> BP <sup>2</sup>	2 (0.5)		3 (1.0)		1 (1.0)	6 (0.4)
2 17 M <sup>1</sup> D <sup>1</sup> BP <sup>2-1</sup>					1 (1.0)	1 (0.1)
2 17 M <sup>1</sup> D <sup>2</sup> BP <sup>2-1</sup>	24 (6.3)	30 (6.1)	13 (4.5)	13 (5.4)	8 (8.0)	88 (5.8)
2 17 MBP <sup>2-1</sup> D <sup>1</sup> B <sup>1</sup>	1 (0.3)	1 (0.2)	2 (0.7)			3 (0.2)
2 17 MBP <sup>3</sup> D <sup>1</sup> B <sup>1</sup>	1 (0.3)	1 (0.2)	1 (0.3)		1 (1.0)	3 (0.2)
2 17 MBP <sup>3-2</sup> D <sup>1</sup> B <sup>1</sup>					1 (1.0)	2 (0.1)
2 17 MBP <sup>4</sup> D <sup>1</sup> B <sup>1</sup>		1 (0.2)				1 (0.1)
3 17 M <sup>1</sup> D <sup>1</sup> B <sup>1</sup> P <sup>1</sup>	160 (41.9)	225 (45.7)	143 (49.5)	127 (52.5)	46 (46.0)	702 (46.6)
3 17 M <sup>1-2</sup> D <sup>1</sup> B <sup>1</sup> P <sup>1</sup>	5 (1.3)	4 (0.8)	3 (1.0)	3 (1.2)	1 (1.0)	16 (1.1)
3 17 M <sup>1-2-1</sup> D <sup>1</sup> B <sup>1</sup> P <sup>1</sup>	5 (1.3)	11 (2.2)	8 (2.8)	11 (4.5)	7 (7.0)	42 (2.8)
3 17 M <sup>1-2-1-2-1</sup> D <sup>1</sup> B <sup>1</sup> P <sup>1</sup>		1 (0.2)				1 (0.1)
3 17 M <sup>1-2-1-2-1-2-1</sup> D <sup>1</sup> B <sup>1</sup> P <sup>1</sup>	59 (15.4)	56 (11.4)	29 (10.0)	20 (8.3)	4 (4.0)	168 (11.1)
3 17 M <sup>2</sup> D <sup>1</sup> B <sup>1</sup> P <sup>1</sup>	56 (14.7)	62 (12.6)	33 (11.4)	28 (11.6)	7 (7.0)	187 (12.4)
3 17 M <sup>2-1</sup> D <sup>1</sup> B <sup>1</sup> P <sup>1</sup>				1 (0.4)		1 (0.1)
3 17 M <sup>2-1-2</sup> D <sup>1</sup> B <sup>1</sup> P <sup>1</sup>			1 (0.3)		1 (1.0)	2 (0.1)
3 17 M <sup>2-1-2-1</sup> D <sup>1</sup> B <sup>1</sup> P <sup>1</sup>	2 (0.5)	4 (0.8)	2 (0.7)		1 (1.0)	9 (0.6)
4 17 M <sup>2-1</sup> M <sup>1</sup> P <sup>1</sup> D <sup>1</sup> P <sup>1</sup>	1 (0.3)					1 (0.1)
4 17 M <sup>2-1</sup> M <sup>1</sup> P <sup>1</sup> D <sup>1</sup> B <sup>1</sup> D <sup>1</sup> P <sup>1</sup>						
T o t a l	382	492	289	242	100	1507



study but at higher values in the present study. This variation may result from differences in sample size, assessment methods, and CBCT image resolution. The relationship between the detection rate of MB2 and patient age is controversial. Lee *et al.* (2011), showed that the detection rate of MB2 decreased with increasing age. The possible reasons are secondary dentin deposition, smaller pulp cavity, and thinner root canal with increasing age. The complete calcification of MB2 disappeared or was difficult to detect in CBCT images. Gilles & Reader (1990), showed no significant relationship between the detection rate of MB2 in the maxillary second permanent molars and patient age. In the present study, the detection rate of MB2 decreased with increasing age. The detection rates of MB2 in the maxillary first and second molars were higher in men than in women. During clinical diagnosis and treatment, at any age, MB2 should be looked for to prevent missing root canals and thereby failure of root canal treatment.

The detection rates of bilateral MB2s in the maxillary first and second molars were 64.8 % and 48.4 %, respectively, showing a significant difference. Compared to Tzeng *et al.* (2020) study, in the present study, the detection rate of bilateral MB2s was slightly lower in the maxillary first molars and slightly higher in the maxillary second molars. This suggests that the possibility of MB2 should be considered in the treatment of the contralateral eponymous tooth when MB2 is present in the molar on one side. In addition, the detection rate of bilateral MB2s in the maxillary molars differs between the sexes. The detection rate of bilateral MB2s in the maxillary first molars is higher in women than in men, while that in the maxillary second molars is higher in men than in women.

The most common root canal types in the maxillary first molars were 3Mfm MB1DB1P1, 3Mfm MB2DB1P1, and 3Mfm MB2-1DB1P1, accounting for 50.6 %, 31.2 %, and 13.9 % of all types, respectively. The most common root canal types of the maxillary second molars were 3Msm MB1DB1P1, 3Msm MB2-1DB1P1, and 3Msm MB2DB1P1, accounting for 48.0 %, 11.3 %, and 11.0 % of all types, respectively. The most common root canal type in the maxillary molars was three roots with three canals, consistent with Tzeng *et al.* (2020), Zhang *et al.* (2011), and Khademi *et al.* (2017) studies. In the maxillary first molars, the most common three-rooted type had 14 root canal configurations. The most common root canal configuration in the one-rooted type was 1Msm1 and in the two-rooted type was 2Msm MBP2DB1. The left MBP indicated that the mesiobuccal root was fused with the palatal root into a single root. In general, teeth with complex anatomical structures can be better described by Ahmed *et al.* (2017) classification system, which may improve the consistency

of reporting of teeth with complex anatomical structures. For example, 19 root canal configurations were counted for the one-rooted type of the maxillary second molars, and Ahmed *et al.* (2017) classification system clearly represented all types. Similarly, the root canal configuration of each root can be represented for multirouted teeth. Ahmed *et al.* (2017) classification system describes the details of the roots and root canals and helps guide teaching and clinical work.

## ACKNOWLEDGEMENTS

Thanks are due to Binzhou Medical University and Jinan Stomatological Hospital for their support and to tutor Hu for her valuable discussion.

---

**ZHANG, T.; ZHAO, M & HU, Y.** Morfología del conducto radicular del molar maxilar mediante tomografía computarizada de haz cónico: un estudio epidemiológico de la provincia de Shandong, China. *Int. J. Morphol.*, 41(3):775-784, 2023.

**RESUMEN:** El objetivo de este estudio fue evaluar la morfología del conducto radicular del molar superior en individuos de la provincia de Shandong, China, utilizando tomografía computarizada de haz cónico (CBCT) y clasificarla con base en el sistema de clasificación de Ahmed *et al.* (2017) para obtener una referencia para diagnóstico clínico y tratamiento. Desde diciembre de 2020 hasta junio de 2021, analizamos los datos de CBCT de 1619 pacientes en el Hospital Estomatológico de Jinan a quienes se les indicó CBCT debido a diversas anomalías orales. Las morfologías de la raíz y del conducto radicular de todos los dientes se analizaron estadísticamente, y la morfología del conducto radicular se clasificó según el sistema de clasificación de Ahmed *et al.* (2017). En los molares superiores, tres raíces fueron las más comunes, representando el 99,24 % y el 74,61 % de todos los primeros y segundos molares superiores, respectivamente. Dos raíces fueron las segundas más comunes, representando el 0,66 % y el 17,29 % de todos los primeros y segundos molares superiores, respectivamente. La variación de la morfología de la raíz, por ejemplo, fusión o defecto de furcación, estuvo presente en 22 (0,76 %) primeros molares superiores y 765 (25,39 %) segundos molares superiores, siendo la fusión radicular mesiovestibular y distovestibular la más común. Las tasas de detección de un segundo canal mesiovestibular (MB2) en los primeros y segundos molares superiores fueron del 48,5 % y 26,5 %, respectivamente. Entre los grupos de edad, la frecuencia de MB2 fue más alta en el grupo de 15 a 24 años y más baja en el grupo de 55 a 64 años. Los conductos radiculares MB2 bilaterales estaban presentes en el 64,8 % y el 48,4 % de los primeros y segundos molares superiores, respectivamente. En los hombres y en las mujeres representaron el 60,6 % y el 67,8 % de los primeros molares superiores, respectivamente, y el 51,7 % y el 45,6 % de los segundos molares superiores, respectivamente. Según la clasificación de la morfología del conducto radicular de Ahmed *et al.* (2017) se encontraron configuraciones de conducto radicular 18 y 22 en 1453 primeros molares superio-

res derechos y 1444 primeros molares superiores izquierdos, respectivamente. Los primeros molares superiores derechos mostraron tres tipos de dos raíces, 14 de tres raíces y uno de cuatro raíces. Los primeros molares superiores izquierdos mostraron dos tipos de una raíz, seis de dos raíces y 14 de tres raíces. Según la clasificación de la morfología del conducto radicular de Ahmed *et al.* (2017) se encontraron configuraciones de conducto radicular 43 y 45 en 1507 segundos molares superiores derechos y 1506 segundos molares superiores izquierdos, respectivamente. Los segundos molares superiores derechos mostraron 17 tipos de una raíz, 16 de dos raíces, ocho de tres raíces y dos de cuatro raíces. Los segundos molares superiores izquierdos mostraron 19 de una raíz, 13 de dos raíces, 12 de tres raíces y uno de cuatro raíces. Este estudio mostró que la morfología del conducto radicular del molar superior es diversa en la provincia de Shandong. El sistema de clasificación de Ahmed y colaboradores proporciona una descripción clara de la morfología del conducto radicular. CBCT se puede utilizar para estudiar morfologías complejas de raíces y conductos radiculares.

**PALABRAS CLAVE: Molares maxilares; CBCT; Morfología del conducto radicular; Sistema de clasificación de conductos radiculares.**

## REFERENCES

- Abarca, J.; Duran, M.; Parra, D.; Steinfors, K. & Zaror, C. Monardes H. Root morphology of mandibular molars: a cone-beam computed tomography study. *Folia Morphol. (Warsz.)*, 79(2):327-32, 2020.
- Abed, M. F.; Kollahdouzan, S. A. R. & Hashemi, S. P. Usage of cone-beam computed tomography (CBCT) to evaluate root and canal morphology of maxillary first molar. *Bull. Environ. Pharmacol. Life Sci.*, 2(9):19-23, 2013.
- Ahmed, H. M. A.; Versiani, M. A.; De-Deus, G. & Dummer, P. M. H. A new system for classifying root and root canal morphology. *Int. Endod. J.*, 50(8):761-70, 2017.
- Dou, L.; Li, D.; Xu, T.; Tang, Y. & Yang, D. Root anatomy and canal morphology of mandibular first premolars in a Chinese population. *Sci. Rep.*, 7(1):750, 2017.
- Ghoncheh, Z.; Zade, B. M. & Kharazifard, M. J. Root morphology of the maxillary first and second molars in an Iranian population using cone beam computed tomography. *J. Dent. (Tehran)*, 14(3):115-22, 2017.
- Gilles, J. & Reader, A. An SEM investigation of the mesiolingual canal in human maxillary first and second molars. *Oral Surg. Oral Med. Oral Pathol.*, 70(5):638-43, 1990.
- Khademi, A.; Zamani Naser, A.; Bahreinian, Z.; Mehdizadeh, M.; Najarian, M. & Khazaei, S. Root morphology and canal configuration of first and second maxillary molars in a selected Iranian population: a cone-beam computed tomography evaluation. *Iran. Endod. J.*, 12(3):288-92, 2017.
- Kim, Y.; Lee, S. J. & Woo, J. Morphology of maxillary first and second molars analyzed by cone-beam computed tomography in a Korean population: variations in the number of roots and canals and the incidence of fusion. *J. Endod.*, 38(8):1063-8, 2012.
- Lee, J. H.; Kim, K. D.; Lee, J. K.; Park, W.; Jeong, J. S.; Lee, Y.; Gu, Y.; Chang, S. W.; Son, W. J.; Lee, W. C.; *et al.* Mesiobuccal root canal anatomy of Korean maxillary first and second molars by cone-beam computed tomography. *Oral Surg. Oral Med. Oral Pathol. Oral Radiol. Endod.*, 111(6):785-91, 2011.
- Tzeng, L. T.; Chang, M. C.; Chang, S. H.; Huang, C. C.; Chen, Y. J. & Jeng, J. H. Analysis of root canal system of maxillary first and second molars and their correlations by cone beam computed tomography. *J. Formos. Med. Assoc.*, 119(5):968-73, 2020.
- Vertucci, F. J. Root canal anatomy of the human permanent teeth. *Oral Surg. Oral Med. Oral Pathol.*, 58(5):589-99, 1984.
- Weine, F. S.; Healey, H. J.; Gerstein, H. & Evanson, L. Canal configuration in the mesiobuccal root of the maxillary first molar and its endodontic significance. *Oral Surg. Oral Med. Oral Pathol.*, 28(3):419-25, 1969.
- Wu, D.; Zhang, G.; Liang, R.; Zhou, G.; Wu, Y.; Sun, C. & Fan, W. Root and canal morphology of maxillary second molars by cone-beam computed tomography in a native Chinese population. *J. Int. Med. Res.*, 45(2):830-42, 2017.
- Yang, L.; Chen, X.; Tian, C.; Han, T. & Wang, Y. Use of cone-beam computed tomography to evaluate root canal morphology and locate root canal orifices of maxillary second premolars in a Chinese subpopulation. *J. Endod.*, 40(5):630-4, 2014.
- Yang, R.; Yang, C.; Liu, Y.; Hu, Y. & Zou, J. Evaluate root and canal morphology of primary mandibular second molars in Chinese individuals by using cone-beam computed tomography. *J. Formos. Med. Assoc.*, 112(7):390-5, 2013.
- Yang, Y.; Wu, B.; Zeng, J. & Chen, M. Classification and morphology of middle mesial canals of mandibular first molars in a southern Chinese subpopulation: a cone-beam computed tomographic study. *BMC Oral Health*, 20(1):358, 2020.
- Zhang, R.; Wang, H.; Tian, Y. Y.; Yu, X.; Hu, T. & Dummer, P. M. Use of cone-beam computed tomography to evaluate root and canal morphology of mandibular molars in Chinese individuals. *Int. Endod. J.*, 44(11):990-9, 2011.
- Zheng, Q. H.; Wang, Y.; Zhou, X. D.; Wang, Q.; Zheng, G. N. & Huang, D. M. A cone-beam computed tomography study of maxillary first permanent molar root and canal morphology in a Chinese population. *J. Endod.*, 36(9):1480-4, 2010.

Corresponding author:  
Ying Hu  
Jinan Stomatological Hospital  
Jinan 250001  
CHINA

E-mail: huy7963@163.com