

Osteological Study of the Parietal Foramen in the Adult Human Skull Bones and its Clinical and Surgical Correlations

Estudio Osteológico del Foramen Parietal en los Huesos del Cráneo Humano Adulto y sus Correlaciones Clínicas y Quirúrgicas

Rasha M. Salama¹; Hamad Alsaykhan² & Azza I. Farag³

SALAMA, R. M.; ALSAYKHAN, H. & FARAG, A. I. Osteological study of the parietal foramen in the adult human skull bones and its clinical and surgical correlations. *Int. J. Morphol.*, 41(3):831-837, 2023.

SUMMARY: Parietal emissary foramina (PEF) are small holes, which are localized between the middle and posterior thirds of the parietal bone posterior surface close to the sagittal suture. PEF are important structures that protect the parietal emissary vein, which passes through it. During neurosurgery procedures, parietal foramina (PF) knowledge is crucial. This work aimed to evaluate presence and location of the PF in the skull of an adult human. Moreover, measure the distance amidst PF and the sagittal suture's midline to ascertain its clinical repercussions. 74 adult human skulls, without gross pathology, were observed for the PF's existence. The PF's and sagittal suture's midline distance were measured. According to the PF patterns of presence, five groups were distributed. Finally, specimens were photographed and subjected to statistical analysis. The PF was absent in 7 skulls (9.5 %). There were 9 skulls (12.2 %) exhibited central parietal foramen where the parietal foramen lies on the sagittal suture. 17 skulls (23 %) showed right unilateral parietal foramen, whereas 15 skulls (20.3 %) demonstrated left unilateral parietal foramen. The final 26 skulls (35.1 %) exhibited bilateral parietal foramen. This descriptive study supplies valuable information of PF variations, which is crucial for neurosurgeons in modifying surgical techniques and procedures to alleviate injury to PF-emerging structures such as emissary veins.

KEY WORDS: Human skull bones; Parietal foramina; Sagittal suture; Parietal emissary vein.

INTRODUCTION

The parietal foramen (PF) is a tiny irregular opening of the parietal bone at its posterior part close to the sagittal suture (Moore *et al.*, 2018; Magalhães *et al.*, 2018). In this area, the parietal foramina are located on both sides of the sagittal suture and the area is named as "the obelion". The name is derived from the Greek symbol "obelos%" that appears similar to the arrangement of the sagittal suture and the bilateral parietal foramina (Naidoo *et al.*, 2021). Apart from the transmission of vessels, no satisfactory explanation has been given regarding the PF's function; therefore, its function remains unclear and is still being investigated (Agarwal *et al.*, 2015; Mahakkanukrauh *et al.*, 2021). An emissary vein emerges through the PF if present; accordingly the PF is also named as the emissary foramen. Emissary veins drain the neuro-cranium, in addition to the cephalic structures. Ultimately, the superior sagittal sinus is eventually

connected to the scalp veins by the parietal emissary veins (Freire *et al.*, 2013; Murlimanju *et al.*, 2015) .

These veins serve as part of the brain's drainage system, regulating intracranial and extracranial pressures (Gangmei *et al.*, 2018). Additionally, the emissary foramina are associated with skull diploic veins, which act as a path between extracranial veins and the intracranial sinuses. This path facilitates spread of infection intracranially; accordingly, it is clinically significant. The emissary veins are also thought to reduce intracranial pressure by emptying blood from the skull. These emissary foramina and veins are frequently ignored during brain surgery, which results in high incidence of bleeding (Shantharam & Manjunath, 2018). PEF are thought to reduce intracranial pressure by emptying blood from the skull. On occasions where one of the foramina is

¹ Department of Anatomy and Embryology, Faculty of Medicine, Menoufia University, Menoufia, Egypt.

² Department of Basic Medical Sciences, Unaizah College of Medicine and Medical Sciences, Qassim University, Unaizah, Kingdom of Saudi Arabia.

³ Human Anatomy and Embryology Department, Faculty of Medicine, Zagazig University, Zagazig, Egypt.

calcified, the patient may develop migraines, cerebral venous abnormalities, unequal suture fusion, or sagittal suture deviations (Wu *et al.*, 2013). Apart from the transmission of vessels, no satisfactory explanation has been given regarding the PF's function; therefore, its function remains unclear and is still being investigated (Agarwal *et al.*, 2015). Radiological advances have made information about skull foramen size and symmetry increasingly helpful in diagnosing pathological conditions associated with these foramen (Berge & Bergman, 2001; Mahakkanukrauh *et al.*, 2021). It is imperative that neurosurgeons recognize the PF as the emissary veins emerging from them can rupture during surgery, which can cause a postoperative epidural hematoma (Mortazavi *et al.*, 2012). Some articles claim that Polish women's PEF is twice as large as Polish men's. This guide raises the topic of whether the PEF may be used to detect sex in forensic conditions, despite the fact that the manner in which this claim is refuted is documented (Wysocki *et al.*, 2006).

This observational study's goal is to investigate the PF's anatomy, highlight its existence in the adult human skull bones, measure the PF's and sagittal suture's midline distance, and determine its clinical significance to raise the awareness of neurosurgeons about PF when developing and adjusting clinical techniques.

MATERIAL AND METHOD

Seventy-four adult human skulls free of gross pathology were used in this study. The human remains were acquired from the anatomy unit of the basic medical sciences department, Unaizah college of medicine, Qassim University, Saudi Arabia. This study was approved by the Research Ethics Committee of the related institute.

Exclusion criteria: Skulls that were damaged physically or due to pathological condition were excluded from the study.

In this study, parietal foramina were evaluated in adult human skulls regarding their presence, pattern, and patency. A needle was inserted in the foramina to examine patency.

Consequently, the distance between the parietal foramen and midline of the sagittal suture was measured transversely by a digital caliper.

Lastly, Specimens were photographed by a digital single-lens reflex camera (Canon D6 DSLR, Canon, Japan) equipped with a 100 mm macro lens (Canon EF 100mm f2.8 USM Macro Lens, Canon, Japan) in a Lightbox Mini

Photo Studio Light Box with 6 Color Backdrops Photo Tent Kit 80Pcs LED Light Room Foldable Photography Lighting.

The parietal foramen patterns of presence were distributed into five groups as follow (Mahakkanukrauh *et al.*, 2021):

Group I (Absent Parietal Foramen, n=7): where there is no PEF on both parietal bones.

Group II (Center Parietal Foramen, n=9): where there is one PEF is presented on the sagittal suture.

Group III (Right Unilateral Parietal Foramen, n=17): where there is one PEF presented on the right parietal bone.

Group IV (Left Unilateral Parietal Foramen, n=15): where there is one PEF presented on the left parietal bone.

Group V (Bilateral Parietal Foramen, n=26): where there is two PEF, one on each parietal bone.

Statistical analysis: Descriptive statistical analysis as mean, standard deviation and range were applied for all quantitative data. On the other hand, qualitative data was presented as frequency and percentage. The Statistical Package for the Social Sciences version 26 (SPSS 26.0) software (IBM Corp., Armonk, NY, USA) was used to analyze the data.

RESULTS

The parietal foramen was observed in 74 adult human skulls without any gross pathology. The foramen was located between the middle and posterior thirds of the parietal bone.

Frequency and percentage of distribution of parietal foramen existence in the skull is shown in (Table I and Fig.1).

The parietal foramen was absent in 7 skulls (9.5 %) (Fig. 2).

Nine skulls (12.2 %) exhibited central parietal foramen, where the parietal foramen observed on the sagittal suture (Fig. 3).

Unilateral parietal foramen was found on 17 skulls, (23 %) showed right unilateral parietal foramen (Fig. 4) whereas 15 skulls (20.3 %) demonstrated left unilateral parietal foramen (Fig. 5). The 26 remaining skulls (35.1 %) exhibited bilateral parietal foramen (Figs. 6 and 7).

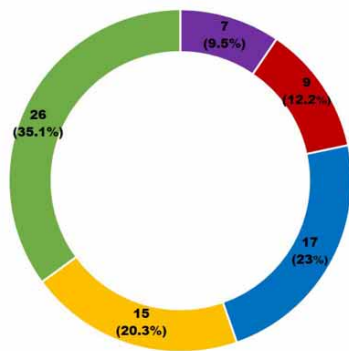


Fig. 1. Frequency and percentage of distribution of existence of parietal foramen in the skull parietal bones (n=74).

Table I. Frequency and percentage of distribution of existence of parietal foramen in the skull parietal bones (n=74).

Distribution of parietal foramen existence	Number	Percent (%)
Absent	7	9.5
Center	9	12.2
Right Unilateral	17	23
Left Unilateral	15	20.3
Bilateral	26	35.1

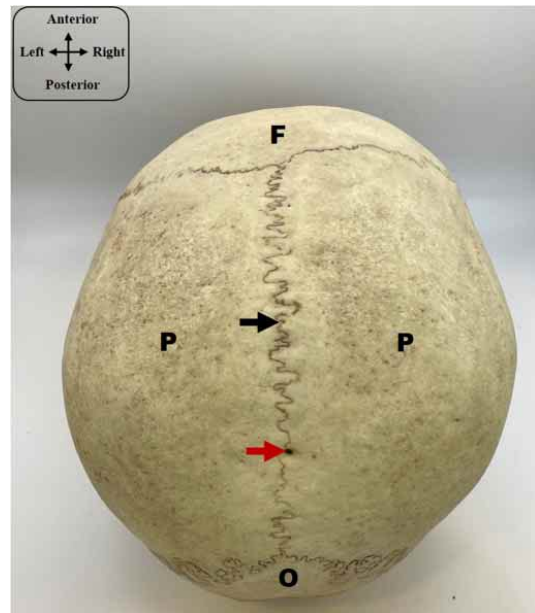


Fig. 3. Skull calvaria depicting the presence of a center parietal foramen (red arrow). Also representing the frontal bone (F), the two parietal bones (P) separated by the sagittal suture (black arrow) and the occipital bone (O). The insert showing the orientation of the skull.

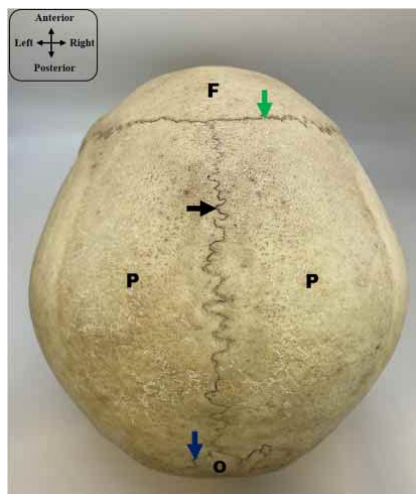


Fig. 2. Skull calvaria depicting the frontal bone (F), the two parietal bones (P) separated by the sagittal suture (black arrow) and the occipital bone (O). Also representing the coronal (green arrow) and the lambdoid suture (blue arrow). Note, the absence of the parietal foramen. The insert showing the orientation of the skull.




Fig. 4. A; Skull calvaria depicting the presence of a right unilateral parietal foramen (red arrow). Also representing the frontal bone (F), the two parietal bones (P) separated by the sagittal suture (black arrow) and the occipital bone (O). The insert showing the orientation of the skull. B; Measuring the distance between the sagittal suture and the right unilateral parietal foramen in the skull calvaria by using the Digital Vernier Caliper Micrometer.



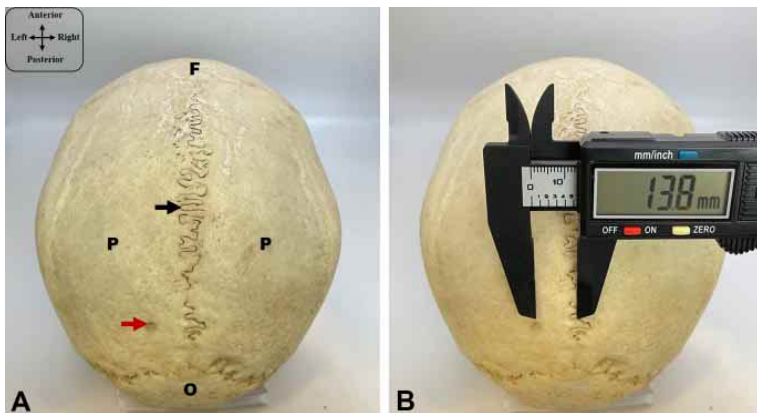


Fig. 5. A; Skull calvaria depicting the presence of a left unilateral parietal foramen (red arrow). Also representing the frontal bone (F), the two parietal bones (P) separated by the sagittal suture (black arrow) and the occipital bone (O). The insert showing the orientation of the skull. B; Measuring the distance between the sagittal suture and the left unilateral parietal foramen in the skull calvaria by using the Digital Vernier Caliper Micrometer.




Fig. 6. A; Skull calvaria depicting the presence of bilateral parietal foramina (red arrow), one in each parietal bone (P). Also representing the frontal bone (F), the occipital bone (O) and the sagittal suture (black arrow). The insert showing the orientation of the skull. B; Measuring the distance between the sagittal suture and the right parietal foramen in the skull calvaria by using the Digital Vernier Caliper Micrometer. C; Measuring the distance between the sagittal suture and the left parietal foramen in the skull calvaria by using the Digital Vernier Caliper Micrometer.

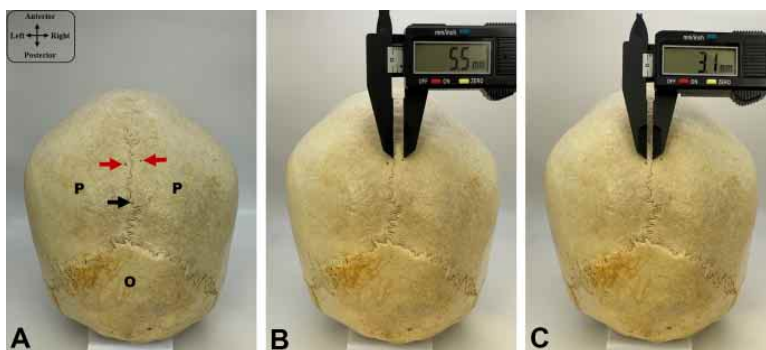


Fig. 7. A; Posterior view of the skull calvaria depicting the presence of bilateral parietal foramina (red arrow), one in each parietal bone (P). Also representing the occipital bone (O) and the sagittal suture (black arrow). The insert showing the orientation of the skull. B; Measuring the distance between the sagittal suture and the right parietal foramen in the skull calvaria by using the Digital Vernier Caliper Micrometer. C; Measuring the distance between the sagittal suture and the left parietal foramen in the skull calvaria by using the Digital Vernier Caliper Micrometer.

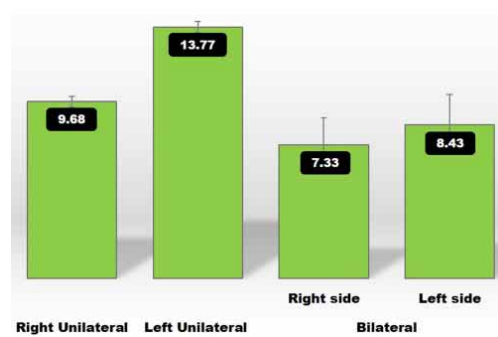


Fig. 8. Mean of distance of parietal foramina from the sagittal suture (n = 74).

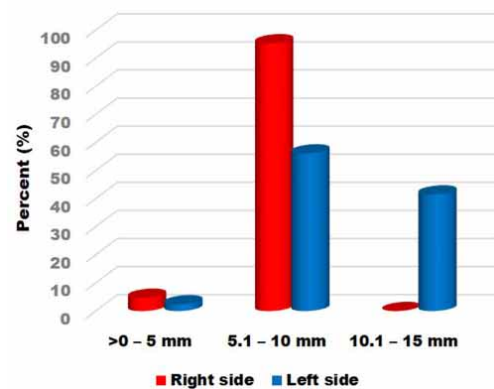


Fig. 9. Comparison of range of distance of unilateral and bilateral parietal foramina from the sagittal suture (n = 58).

In Table II and Figure 8, The mean and range of distance of the PF from the sagittal suture were $(9.68 \pm 0.30 \text{ mm}, 9.2 - 10.0 \text{ mm})$ respectively in right unilateral distribution, while the mean and range of distance of the PF from the sagittal suture were $(13.77 \pm 0.33 \text{ mm}, 13 - 14.2 \text{ mm})$ in left unilateral distribution, respectively. Whereas, in bilateral parietal foramen distribution, the mean and range of distance of the PF from the sagittal suture were $(7.33 \pm 1.46 \text{ mm}, 4.9 - 9.8 \text{ mm})$ on the right side and $(8.43 \pm 1.64 \text{ mm}, 3.1 - 10.3 \text{ mm})$ on the left side.

A comparison between unilateral and bilateral parietal foramina range of distance from the sagittal suture, where 2 (4.7 %) skulls demonstrated the parietal foramen on right side and 1 (2.4 %) skull demonstrated the parietal foramen on left side and their distance from the sagittal suture ranged from >0 mm to 5 mm

Table II. Mean and Range of distance of parietal foramina from the sagittal suture (n = 74).

Distribution of existence of Parietal foramen	Mean±SD	Range
Absent	-----	-----
Center	0.0	0.0
Right Unilateral	9.68 ± 0.30	9.2 – 10.0
Left Unilateral	13.77 ± 0.33	13 – 14.2
Bilateral		
• Right side	7.33 ± 1.46	4.9 – 9.8
• Left side	8.43 ± 1.64	3.1 – 10.3

(Table III and Fig. 9). Whereas, 41 (95.3 %) skull bones showed the parietal foramen on right side and 23 (56.1 %) skull bones showed the parietal foramen on left side and their distance from the sagittal suture ranged from 5.1 mm to 10 mm. Finally, there are 17 (41.5 %) skull bones exhibited the parietal foramen on left side and their distance from the sagittal suture ranged from 10.1 mm to 15 mm.

Table III. Comparison of range of distance of unilateral and bilateral parietal foramina from the sagittal suture (n = 58).

Range of distance (mm)	Right side (n=43)	Left side (n=41)
>0 – 5 mm	2 (4.7 %)	1 (2.4 %)
5.1 – 10	41 (95.3 %)	23 (56.1 %)
10.1 – 15	0 (0.0 %)	17 (41.5 %)

DISCUSSION

The parietal emissary foramina are located on the posterior section of the parietal bones between the middle and posterior thirds of the parietal bone close to the sagittal suture (Naidoo *et al.*, 2021). The emissary vessels emerge through this foramen. The emissary artery has many anastomoses with scalp arteries, these include; occipital, superficial temporal, middle meningeal, and pericranial arteries (Yoshioka *et al.*, 2006). These foramina also aid in the relief of high intracranial pressure and the regulation of cerebral temperature by draining blood (Murlimanju *et al.*, 2015). The PF's margins are pointedly defined, allowing radiologists to distinguish between these foramina and surgical holes performed by neurosurgeons, which has a larger size than the PF's (Shantharam & Manjunath, 2018). The skull is created by intramembranous ossification, and the parietal bone develops at two ossification centers that lie bilaterally on the midline and ultimately fuse.

The third fontanel, also known as the pars obelica, is a "V-shaped" notch that results from extended ossification of the dorsal parietal part of the skull, which causes the formation of the PF, which initially appears as a singular

defect. As a result, the flaw continues to be an oval foramen. Depending on whether the third fontanel shuts, the PF might be unilateral or bilateral (Yılmaz *et al.*, 2014; Agarwal *et al.*, 2015). This statement is consistent with the increased prevalence found in this current study, which found a 35.1 % existence of bilateral PF, that is higher than those of Naidoo *et al.* (2021) 32 % and Debbarma *et al.* (2015) (30 %) (Debbarma *et al.*, 2015; Naidoo *et al.*, 2021). But, this discovery is less than those of Murlimanju *et al.* (2015) (55.2 %) and Gangmei *et al.* (2018) (62.5 %).

According to this study, mean incidence of unilateral PF is 43.3 % of cases (right: 23 %, left: 20.3 %), this finding is higher than the findings of Naidoo *et al.* (2021) (35 %) and Berge & Bergman (2001) (30 %). The recognition of emissary foramina, like the PF, is critical for clarification of regional vasculature and differentiating these foramina from variation anatomy (Shantharam & Manjunath, 2018). This current work found PF in 90.5 % specimens, which is consistent with the findings of Makandar *et al.* (2013) in North Indian females.

The center PF refers to the parietal foramen located on the sagittal suture (Gangmei *et al.*, 2018). The current work illustrated 12.2 % incidence of the center PF, that is higher than that reported by other researchers (Keskil *et al.*, 2003; Naidoo *et al.*, 2021) (5 %). On the other hand, another study on Japanese populations reported (0.7 %) incidence of median PF (Mann *et al.*, 2009).

Due to the possibility of emissary vein rupture during surgical procedures, knowing the topography of the foramen in respect to the sagittal suture is crucial for neurosurgery approaches (Murlimanju *et al.*, 2015; Shantharam & Manjunath, 2018).

This study compared the distance of unilateral and bilateral parietal foramina from the sagittal suture, where 2 (4.7 %) skull bones demonstrated the parietal foramen on right side and 1 (2.4 %) skull bone demonstrated the parietal foramen on left side and their distance from the sagittal suture ranged from (>0 mm to 5 mm). Whereas, 41 (95.3 %) skull bones showed the parietal foramen on right side and 23 (56.1 %) skull bones showed the parietal foramen on left side and their distance from the sagittal suture ranged from (5.1 mm to 10 mm). Finally, there are 17 (41.5 %) skull bones exhibited the parietal foramen on left side and their distance from the sagittal suture ranged from (10.1 mm to 15 mm). These results are nearly similar to those reported by other studies as Naidoo *et al.* (2021); Yoshioko *et al.* (2006) and Murlimanju *et al.* (2015) that disclosed a range of (4.44–18.20 mm), (3.00–12.00 mm), and (0.50–15.00 mm) respectively.

This study recorded the range of distance of unilateral and bilateral parietal foramina from the sagittal suture, where 41 (95.3 %) skull bones showed the parietal foramen on right side and 23 (56.1 %) skull bones showed the parietal foramen on left side and their distance from the sagittal suture ranged from (5.1 mm to 10 mm). This is similar to that reported by other studies which found the mean distance (9.02 mm) (Naidoo *et al.*, 2021). Another 17 skull bones (41.5 %) in this study exhibited the parietal foramen on left side and their distance from the sagittal suture ranged from (10.1 mm to 15 mm), this is higher than that stated by previous studies such as Halagatti & Sagar (2018) and Shantharam & Manjunath (2018) who revealed mean distances of (6.60 mm and 7.34 mm), respectively.

According to previous studies, ethnic differences may have contributed to the disparities between the results of the different researches (Yoshioka *et al.*, 2006; Shantharam & Manjunath, 2018). In addition, Carolineberry & Berry (1967), in a research of cranial differences in humans, noted that the frequency of any given variant is constant across all races. Another study sought to partially fill this blank because an overall examination of the literature revealed a lack of information on the PF in the South African community, highlighting the necessity for population specific information on the PF's anatomical features (Naidoo *et al.*, 2021).

Skull foramina variations are significant because of their connections to disease and surgical ramifications (Berge & Bergman, 2001; Mortazavi *et al.*, 2012; Debbarma *et al.*, 2015). As a result of the high prevalence of PF reported in this current study and other studies (Singh & Raibagkar, 2011), understanding the emissary PF anatomy is crucial since the neurosurgeon will come into contact with the cranial emissary veins.

CONCLUSION

This study supplies a valuable descriptive data of PF's existence, and position. Together with the PF's and sagittal suture's midline distance. Such data is worthy for neurosurgeons in modifying surgical techniques and procedures to alleviate injury of PF-emerging structures such as emissary veins.

LIMITATIONS. Knowledge of the size of the skull foramen is crucial due to radiological breakthroughs using computed tomography and magnetic resonance imaging to diagnose pathological disorders. Such limitation will be addressed in the future.

SALAMA, R. M.; ALSAYKHAN, H. & FARAG, A. I. Estudio osteológico del foramen parietal en los huesos del cráneo humano adulto y sus correlaciones clínicas y quirúrgicas. *Int. J. Morphol.*, 41(3):831-837, 2023.

RESUMEN: Los forámenes emisarios parietales (FEP) son pequeños orificios que se localizan entre los tercios medio y posterior de la superficie posterior del hueso parietal, cerca de la sutura sagital. Los FEP son estructuras importantes que protegen la vena emisaria parietal, que lo atraviesa. Durante los procedimientos de neurocirugía, el conocimiento de los forámenes parietales (FP) es crucial. Este trabajo tuvo como objetivo evaluar la presencia y ubicación del FP en el cráneo de hombres adultos, además, medir la distancia entre el FP y la línea mediana de la sutura sagital para conocer su repercusión clínica. Se examinaron 74 cráneos humanos adultos, sin patología grave, para determinar la existencia del FP. Se midió la distancia de la línea mediana de la sutura sagital y del FP. De acuerdo con los patrones de presencia del FP, se distribuyeron en cinco grupos. Finalmente, los especímenes fueron fotografiados y sometidos a análisis estadístico. El PF estaba ausente en 7 cráneos (9,5 %). Hubo 9 cráneos (12,2 %) que presentaban un PF central localizándose en la sutura sagital. 17 cráneos (23 %) presentaban un FP unilateral derecho, mientras que 15 cráneos (20,3 %) se observó un FP unilateral izquierdo. Los 26 cráneos restantes (35,1 %) exhibieron FP bilaterales. Este estudio descriptivo proporciona información valiosa sobre las variaciones del FP, que es fundamental para los neurocirujanos en el momento de modificar las técnicas y los procedimientos quirúrgicos para aliviar las lesiones de las estructuras emergentes del FP, como las venas emisarias.

PALABRAS CLAVE: Huesos del cráneo humano; Foramen parietal; Sutura sagital; Vena emisaria parietal.

REFERENCES

- Agarwal, P.; Pandey, M.; Baranwal, S. & Roy, K. Large midline persistent parietal foramina with occipital encephalocele and abnormal venous drainage. *J. Cleft Lip Palate Craniofac. Anom.*, 2(1):66-9, 2015.
- Berge, J. K. & Bergman, R. A. Variations in size and in symmetry of foramina of the human skull. *Clin. Anat.*, 14(6):406-13, 2001.
- Carolineberry, A. & Berry, R. J. Epigenetic variation in the human cranium. *J. Anat.*, 101(Pt. 2):361-79, 1967.
- Debbarma, S.; Zaidi, S. H. H.; Mishra, A. & Nirala, K. P. Study of parietal foramen in North Indian population. *Int. J. Basic Appl. Med. Sci.*, 5(2):143-5, 2015.
- Freire, A. R.; Rossi, A. C.; de Oliveira, V. C. S.; Prado, F. B.; Caria, P. H. F. & Botacin, P. R. Emissary foramina of the human skull: anatomical characteristics and its relations with clinical neurosurgery. *Int. J. Morphol.*, 31(1):287-92, 2013.
- Gangmei, G.; Devi, H. S.; Daimei, T.; Remei, E. & Tunglut, J. Variations of parietal foramen in dried adult human skulls. *IOSR J. Dent. Med. Sci.*, 17(5):26-29, 2018.
- Halagatti, M. & Sagar, S. An anatomical study of parietal emissary foramina in dry adult human skulls. *Int. J. Anat. Radiol. Surg.*, 7(2):A020-A022, 2018.
- Keskil, S.; Gözil, R. & Calgüner, E. Common surgical pitfalls in the skull. *Surg. Neurol.*, 59(3):228-31, 2003.

- Magalhães, C. P.; de Souza Ferrira, M. R.; dos Reis, R. S.; da Silva, F. A.; dos Santos, T.R. & de Farias Campina, R. C. Existence of enlarged parietal foramina in bone collections. *J. Morphol. Sci.*, 35(02):125-8, 2018.
- Mahakkanukrauh, C.; Chitapanarux, N.; Kwangsukstith, S.; Navic, P. & Mahakkanukrauh, P. The morphometric study of parietal emissary foramen related with clinical implications in Thais. *Int. J. Morphol.*, 39(5):1283-8, 2021.
- Makandar, U. K.; Kulkarni, P. R. & Suryakar, A. N. Comparative study of incidence of parietal foramina in North and South Indian human crania. *Indian J. Forensic Med. Toxicol.*, 7(2):123-7, 2013.
- Mann, R.; Manabe, J. & Byrd, J. E. Relationship of the parietal foramen and complexity of the human sagittal suture. *Int. J. Morphol.*, 27(2):553-64, 2009.
- Moore, K. L.; Dalley, A. F. & Agur, A. M. R. *Clinically Oriented Anatomy*. 8th ed. Amsterdam, Wolters Kluwer, 2018.
- Mortazavi, M. M.; Tubbs, R. S.; Riech, S.; Verma, K.; Shoja, M. M.; Zurada, A.; Benninger, B.; Loukas, M. & Gadol, A. A. C. Anatomy and pathology of the cranial emissary veins: a review with surgical implications. *Neurosurgery*, 70(5):1312-8, 2012.
- Murlimanju, B. V.; Saralaya, V. V.; Somesh, M.S. ; Prabhu, L. V.; Krishnamurthy, A.; Chettiar, G. K. & Pai, M. M. Morphology and topography of the parietal emissary foramina in South Indians: an anatomical study. *Anat. Cell Biol.*, 48(4):292-8, 2015.
- Naidoo, J.; Luckrajh, J. S. & Lazarus, L. Parietal foramen: incidence and topography. *Folia Morphol. (Warsz.)*, 80(4):980-4, 2021.
- Shantharam, V. & Manjunath, K. Anatomical study of parietal emissary foramina in human skulls. *Int. J. Anat. Radiol. Surg.*, 7(1):AO11-AO14, 2018.
- Singh, D. R. & Raibagkar, C. J. Study of variation in atypical foramina of dry human skull. *Natl. J. Integr. Res. Med.*, 2(2):1-5, 2011.
- Wu, X. J.; Xing, S. & Trinkaus, E. An enlarged parietal foramen in the late archaic Xujia Yao 11 neurocranium from northern China, and rare anomalies among Pleistocene Homo. *PLoS One*, 8(3):e59587, 2013.
- Wysocki, J.; Reymond, J.; Skarz' yn'ski, H. & Wróbel, B. The size of selected human skull foramina in relation to skull capacity. *Folia Morphol. (Warsz.)*, 65(4):301-8, 2006.
- Yılmaz, E.; Yetim, A.; Erol, O. B.; Pekcan, M. & Yekeler, E. Multiple occipital, parietal, temporal, and frontal foramina: a variant of enlarged parietal foramina in an infant. *Balkan Med. J.*, 31(4):345-8, 2014.
- Yoshioka, N.; Rhoton Jr., A. L. & Abe, H. Scalp to meningeal arterial anastomosis in the parietal foramen. *Neurosurgery*, 58(1 Suppl.):ONS123-6, 2006.

Corresponding author:
Rasha Mamdouh Salama
Department of Anatomy and Embryology
Faculty of Medicine
Menoufia University
EGYPT

E-mail: drrashasalama@yahoo.com
rasha.salama@med.menofia.edu.eg

ORCID : 0000-0001-7582-3851