

Internal Structural Connections in the Popliteus Tendon Complex with Posterior Cruciate Ligament and Clinical Implications

Conexiones Estructurales Internas en el Complejo Tendón Poplíteo con Ligamento Cruzado Posterior e Implicaciones Clínicas

Wen-Bin Jiang¹; Chan Li¹; Shi-Zhu Sun¹; Ting-Wei Song¹; Campbell Gilmore²; Wei Tang¹; Sheng-Bo Yu¹ & Hong-Jin Sui¹

JIANG, W. B.; LI, C.; SUN, S. Z.; SONG, T. W.; GILMORE, C.; TANG, W.; YU, S. B. & SUI, H. J. Internal structural connections in the popliteus tendon complex with posterior cruciate ligament and clinical implications. *Int. J. Morphol.*, 41(3):953-958, 2023.

SUMMARY: At present, the anatomical relationship the mid-portion of popliteus tendon complex (PTC) and the surrounding tissues is still unclear, especially its relationship to the posterior cruciate ligament (PCL). It affected the anatomical reconstruction of the posterolateral complex (PLC) injury. A total of 30 cases of the adult human knee joint fixed with formalin were used. Sagittal sections were made in 14 knee joints by the P45 plastination technique and dissection of 16 cases of knee joints. The P45 section revealed that the popliteus muscle fascia ran superiorly over the posterior edge of the tibial intercondylar eminence, and turned forward to be integrated into the PCL. Laterally, near the posterior edge of the lateral tibial plateau, the popliteus tendon penetrates through the articular capsule (AC), where two dense fibrous bundles were given off upwards by the popliteus tendon: one was the ventral fiber bundle, which ran superiorly over the posterior edge of the tibial plateau and then moved forwards to connect with the lateral meniscus; the dorsal fibers bundle ascended directly and participated in the AC. Meanwhile, the popliteus muscle dissection showed that at the posterior edge of the platform of the lateral condyle of the tibia, at the tendon-muscle transition, the PTC and AC were anchored to PCL.

KEY WORDS: Knee; Posterolateral complex; Popliteus tendon complex; Anatomy reconstruction; P45 plastination technique.

INTRODUCTION

Posterolateral corner injuries are rare and are easy to misdiagnose. They occur in less than 2 % of cases (Bonadio *et al.*, 2014). Almost cases of PLC injuries are combined injuries involving the anterior cruciate ligament (ACL) or posterior cruciate ligament (PCL) (Djian, 2015). Without timely and scientific diagnosis and treatment after PLC injury, it could cause posterolateral instability, degeneration of articular cartilage and meniscus, and increased incidence of ACL and PCL reconstruction failures (Porrino *et al.*, 2018).

The PLC of the knee is complex and controversial in terms of its anatomy and biomechanics (Kang *et al.*, 2019; Figueroa *et al.*, 2021). The anatomy of PLC is complex of tendon-muscle and ligament (LaPrade *et al.*, 2003). Some studies have shown the triangular stability structure formed by the two structures of fibular collateral ligament (FCL) and the popliteus tendon complex (PTC) is the main stable

structure of the posterolateral in the knee joint (LaPrade *et al.*, 2003; Djian, 2015; Porrino *et al.*, 2018). The PTC comprises the popliteus tendon-muscle and the popliteofibular ligament (PFL) (LaPrade *et al.*, 2003; Feipel *et al.*, 2003). Therefore, some scholars (Schinhan *et al.*, 2011; Wood *et al.*, 2020; Mutou *et al.*, 2022) speculated that the PLC comprised of popliteus tendon-muscle is a “dynamic” stabilizer, not only playing a role in preventing external rotation of the tibia, counteracting the effect of moving backward and varus of the tibia (Crespo *et al.*, 2015). There was research speculation that the PTC acts as a retractor of the lateral meniscus (Zappia *et al.*, 2018). However, more morphological evidence is needed to prove this speculation due to PTC being more defined as a static structure in terms of treatment (Zabrzynski *et al.*, 2021).

So far, there were numerous morphological studies focusing on PTC (Zeng *et al.*, 2011; Jadhav *et al.*, 2014) but

¹ Department of Anatomy, Dalian Medical University, Dalian 116044, China.

² Medical school, St. George's University of London, London UK.

more were concentrated in the proximal popliteus tendon attachments site (Ullrich *et al.*, 2002; Feipel *et al.*, 2003; Natsis *et al.*, 2020). The morphological relationship between the mid-portion of PTC (Zabrzynski *et al.*, 2021) and the surrounding tissues was still unclear, especially its relationship to the PCL (Feipel *et al.*, 2003; Chuncharunee *et al.*, 2012; Zabrzynski *et al.*, 2021). Consequently, the long-term uncertainty of the PTC attachment might make the actual function of the PTC questionable (Chuncharunee *et al.*, 2012). This might lead to the development of different multimodal treatment strategies for PLC injury (Yoon *et al.*, 2011; Djian, 2015; Mutou *et al.*, 2022). Anatomical research of PTC remains a challenge for most scholars because of the complicated ligamentous, fascia, and soft tissue structures surrounding the knee. P45 sheet plastination technique is capable of displaying the boundary of soft tissue and the shape of fibers in a wide range of high definition *in situ*, which plays an important role in determining the anatomical relationship between adjacent structures (Jiang *et al.*, 2020). Therefore, this study was performed to explore the detailed structures of the popliteus muscle (PM) using the P45 plastination technique, specifically the connection between the PM and the PCL. Subsequently, guided by the P45 results, gross anatomy was also used, which could provide anatomical information for the reconstruction of the PLC.

Ethics Statement. This study was approved by the ethics committee of the Body and Organs Donation Center of Dalian Medical University. The research involved 30 knee specimens of Chinese middle-aged adults from the Body and Organs Donation Center. Written informed consent was obtained from the donors involved in this study prior to death in accordance with the regulation of the ethics committee.

MATERIAL AND METHOD

A total of 30 formalin-fixed adult knee joint specimens were collected. Gross anatomy was performed in 16 cases, and the sagittal P45 plastination section was made in 14 cases. All specimens were obtained from the cadaver after the teaching at the Anatomy Department of Medical University. The continuous sagittal sections of knee joints were prepared by Dalian Hoffen Biotechnology Co., Ltd., using the P45 plastination technique. None of the specimens showed signs of tumor, congenital malformation, fracture, severe osteoarthritis, and other related diseases after diagnosis in the Department of Radiology, The 967 Hospital of The Joint Logistics Support Force of PLA.

P45 sheet plastination technique (Sui & Henry, 2007):

Slice: The specimens were frozen at -70 °C for two weeks, embedded in the embedding box by polyurethane, frozen again at -70 °C for two days, and sliced with a high-speed band saw with a thickness of 3 mm.

Bleaching: The slices were rinsed overnight in cold water and soaked in 5 % hydrogen peroxide overnight.

Dehydration: After slice bleaching, the slices were pre-cooled, then dehydrated in 85 % acetone at -25 °C for five days, then in 93 % acetone at -15 °C for five days, then degreased at room temperature, and finally in 100 % acetone.

Vacuum impregnation: The slice was taken out from the acetone bath, clamped with a double glass plate to make the slice infiltration mold, and then the die was filled with Hoffen polyester P45 (Dalian Hoffen Biotechnology Co., Ltd., Dalian, China). The mold filled with the infiltration and embedding material was placed vertically in the vacuum cabinet for impregnation at room temperature. The pressure was slowly reduced to 20, 10, 5, and 0 mmHg according to the bubble size and release rate. The pressure 0 mmHg was kept until the bubbling stops. The impregnation duration was more than 8 hours.

Curing: After releasing the vacuum, the bubbles were checked and removed from the plate. Clamp the top of the mold with a clip and move it to solidify. Solidify in a hot water bath and place upright in a 40 °C water bath for three days. After curing, the slice was removed from the bathtub and cooled on the shelf to room temperature. The slices were removed from the glass plate and covered adequately with bonded plastic film to provide protection.

Photography and Observation: The slices containing PM were selected. The slices were observed by laying them on the X-ray reading lamp, and photos were taken with a Canon 7D camera (Canon Inc. Tokyo, Japan). The fiber connections between PM and PCL, lateral meniscus *et al.* was observed and analyzed, and the results were recorded.

Dissection. In the popliteal fossa, the superficial structures were removed layer by layer to expose the PM. Identify the articular capsule (AC) of the knee joint. Along the superior edge of the PM, part of the AC was incised, and the knee joint was opened. The PM was amputated at the back of the tibial plateau, and the PM and AC were lifted to observe their connection with the PCL and AC along the articular surface of the tibial plateau. The results of anatomical observation were recorded with a Canon 7D camera (Canon Inc., Tokyo, Japan).

RESULTS

P45 observation results.

In this study, totally 14 numbers knee joints were made into continuous P45 sections of the PM. In the sagittal P45 section of the knee joint through the long axis of the PCL, an overall picture of the PCL and PM was shown sagittally (Fig. 1). The PCL was observed from the inner surface of the medial femoral condyle to the posterior intercondylar area of the tibia, slightly curved shape. On the one hand, the PM extended distally onto the dorsal surface of the tibia. Behind the intercondylar eminences, the upper edge of the PM was located at level of the posterior edge of the tibial plateau. And its fascia bypassed the posterior edge of the tibial plateau, went on forward to the deep surface of the AC, and participated in the formation of the PCL (Fig. 1).

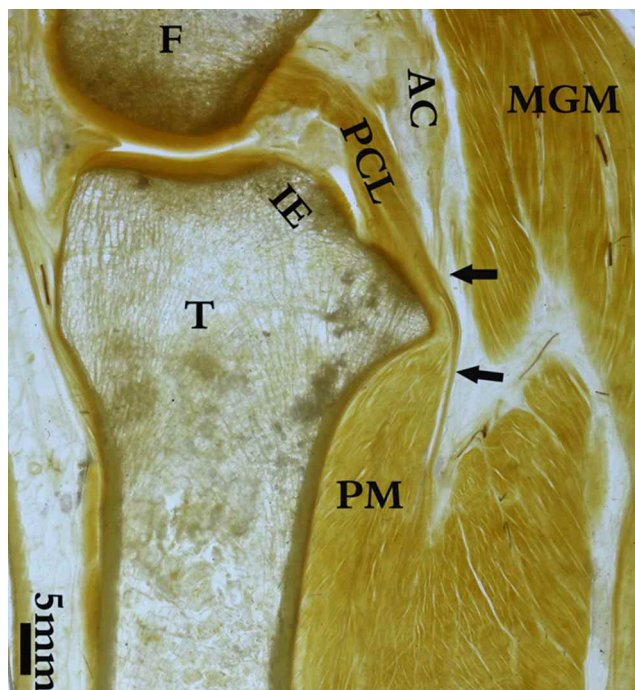


Fig. 1. Sagittal P45 section of the human knee joint through the long axis of the PCL. The PCL was observed from the inner surface of the medial femoral condyle to the caudal intercondylar area of the tibia. The PM extended distally onto the dorsal surface of the tibia. Near the posterior edge of the intercondylar eminence, the dense popliteal fascia bypassed the upper edge of the tibial plateau, moved forwards through the AC of the knee joint, integrated into the PCL and AC, and became part of the PCL and AC. F: Medial femoral condyle; T: Tibia; MGM: Medial head of gastrocnemius muscle; PCL: Posterior cruciate ligament; PM: Popliteus muscle; AC: Articular capsule; IE: Intercondylar eminence. Black arrows: Popliteus fascia.

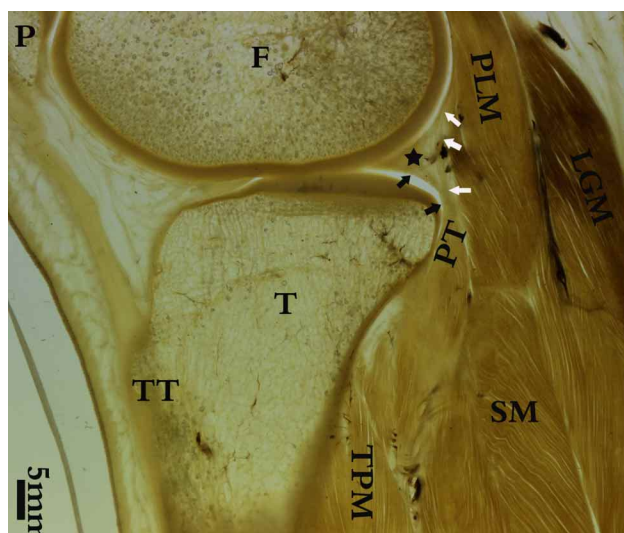


Fig. 2. Sagittal P45 section of the knee joint through the middle part of lateral condyle of the femur. The section showed the articular surface of the lateral condyle of the femur and the lateral tibial plateau. The lateral meniscus could be seen between them. The popliteal tendon was located behind the tibial plateau. The upper margin of the popliteal tendon sent out two dense fibrous bundles at the posterior tibial plateau. One, the ventral fibrous bundle, which bypassed the posterior edge of the tibial plateau and moved forwards to connect with the lateral meniscus; The other was the dorsal fibrous bundle, which ascended upwards and ascended directly into the AC. F: Lateral condyle of femur; T: Lateral part of tibial plateau; TPM: Posterior tibialis muscle; SM: Soleus muscle; PLM: Plantaris muscle; LGM: Lateral head of the gastrocnemius muscle; PT: Popliteus tendon. Black pentagram: Lateral meniscus.

And in other sagittal P45 sections of the knee joint through the middle part of the lateral condyles of femur, the articular surface of the lateral condyles of the femur and the lateral part of the tibial plateau were observed (Fig. 2). The popliteal tendon penetrated the articular capsule and sent two dense fiber bundles upwards: one, the ventral fiber bundle bypassed the posterior edge of the tibial plateau and moved forward to connect with the lateral meniscus; the other, the dorsal fibers ascended directly into the articular capsule.

Anatomic observation results. The dissection results showed that the PM attached to the proximal tibia and tilted upwards from medial to lateral of the lateral condyle of the femur at the bottom of the popliteal fossa, participating in the formation of the lower part of the popliteal fossa. At the level of the posterior edge of the platform of the lateral condyle of the tibia, the PM is obliquely inserted into the articular capsule. We found that many connective tissues appeared around the tibial attachment of the PCL. The fibers

connecting the popliteal muscle to the surrounding structure could have been removed inadvertently during the dissection in the previous studies. Guided by the P45 results, we avoided this error. And we tried to restore these connections. Inside

the mid-portion of PTC, the ventral fibers of the PM fused with the PCL and inner surface of the articular capsule (Fig. 3). When the PM was lifted over, it was noted that a connective between the popliteal tendon and the PCL (Fig. 3).

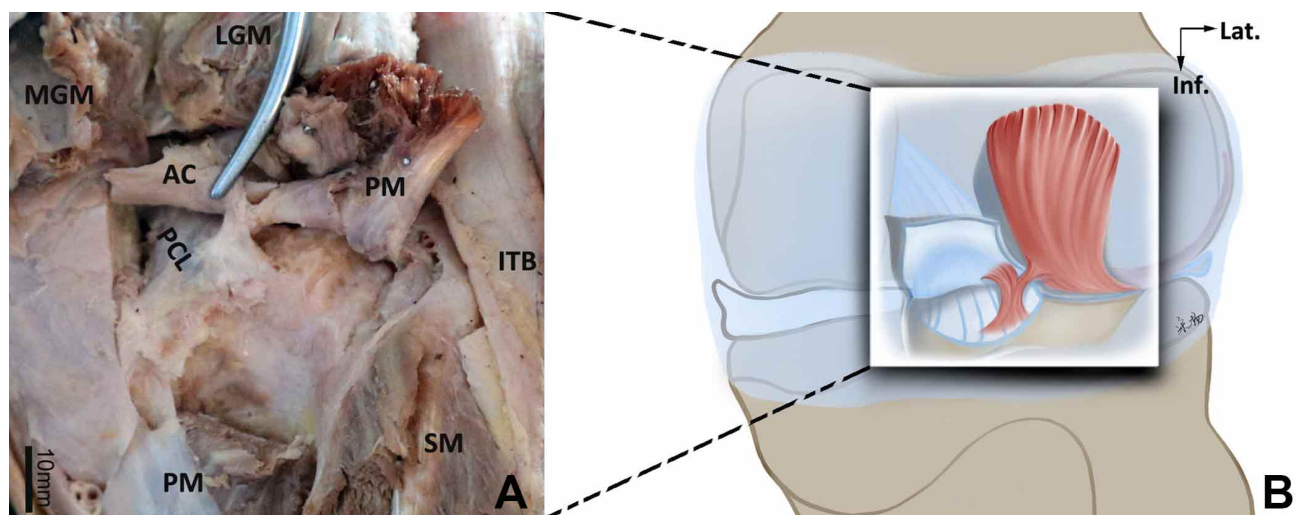


Fig. 3. The posterior view of the right knee joint. (A) Anatomical relationship among the PCL, the AC, and the PM (the PM and AC was lifted upwards). (B) Pattern diagram of (A). The PCL, the AC, and the PM were shown in this figure. At the level of the posterior edge of the platform of the lateral condyle of the tibia, the PM obliquely inserted into the articular capsule. When the PM and AC was lifted upward, at the mid-portion of PM, it could be observed that there was a dense connective tissue band that originated from the deep surface of the PCL, which penetrates to the inner surface of the articular capsule was connected to the tibial end of the PM and the AC. PM: Popliteus muscle; AC: Articular capsule; PCL: Posterior cruciate ligament; SM: Soleus muscle; LGM: Lateral head of the gastrocnemius muscle; MGM: Medial head of gastrocnemius muscle; ITB: iliotibial tract.

DISCUSSION

PLC injury is often associated with complex injury of the knee, clinically, concomitant injuries of posterolateral corner structures with a cruciate injury lead to an increased incidence of ACL and PCL reconstruction failures (Crespo *et al.*, 2015). Thus, the operation should take one not only to reconstruct the cruciate ligament but also to reconstruct the PLC (Fanelli *et al.*, 2011; Fanelli & Edson, 2012; Dean & LaPrade, 2020). PTC is the deep structure of PLC, it is difficult to formulate guidelines for anatomical reconstruction for PLC injury due to PTC's complex and variable anatomy (Ahn *et al.*, 2019; Mutou *et al.*, 2022).

In this study, there were dense connections between the PTC and the PCL, the lateral meniscus, and the lateral articular capsule, in which fiber connections were concentrated the mid-portion of PTC. Combined with P45 and gross anatomy results, the relationship between PTC and PCL is that the PTC is anchored to PCL. Similarly, the AC was also anchored to the PCL. This form of anchoring of the posterior cruciate ligament to the PTC was identified for the first time in comparison with previous studies (Feipel

et al., 2003; Chuncharunee *et al.*, 2012). It has been reported that the popliteus tendon (PT) was considered the fifth ligament of the knee (LaPrade *et al.*, 2010). Based on the morphological results of this study, the PTC function might be segmented. The PTC might have the function of movement when it is below the posterior edge of the tibia platform. The mid-portion of PTC acts as a retractor of the lateral meniscus (Zappia *et al.*, 2018). This form of anchoring of the PCL to the PTC might contribute to limiting the non-physiological displacement of lateral meniscus. Once it exceeds this position, PTC might have the function of stabilizing the knee joint and regulating the mechanical balance among various structures. In particular, there was a study indicating that those higher rates of cruciate graft failure were due to increased force transmitted through the cruciate ligaments if a concomitant posterolateral corner injury was not fixed alongside the cruciate injury (Harner *et al.*, 2000).

The knee joint is the largest and most complex joint of the musculoskeletal system. Hence, it is difficult to determine the boundary of soft tissue by the method of gross

anatomy. However, the adjacent relationship between organizations could be revealed on the premise of retaining the original organizational structure by the P45 sheet plastination technique, because of the characteristics of its high-definition soft tissue display. The anatomical structure observed using the P45 sheet plastination technique could make us more targeted in the process of gross anatomy. This reason might be responsible for the significant difference in the gross anatomical results of this study and previous studies (Feipel *et al.*, 2003; Chuncharunee *et al.*, 2012). Taken together, through the combined method of P45 and gross anatomy, we identified that the fiber connection between PM and PCL was clearly illustrated for the first time. It might suggest that surgeons and radiologists should pay attention to this structure of the popliteal area when treating cruciate ligament injury, PLC injury, and finding the cause of knee pain.

CONCLUSION

The PTC and AC is anchored to PCL. This form of anchoring of the PCL to the PTC might contribute to limiting the non-physiological displacement of lateral meniscus.

LIMITATIONS. In future research, it is necessary to carry out in vivo mechanical experiments on PTC to discuss the mechanical interactions between each part. In addition, this article identified the connection between the posterior cruciate ligament and the popliteal muscle. But, more samples and more studies are needed in the future to report the specific probability of such connections in populations, and the reasons for their occurrence.

ACKNOWLEDGMENTS. We would like to thank Director Yun Zheng of Dalian Hoffen Biotechnology Co., Ltd., for assistance with photography and Director Qiang Xu of Department of Radiology, The 967 Hospital of The Joint Logistics Support Force of PLA, for diagnosis of samples.

JIANG, W. B.; LI, C.; SUN, S. Z.; SONG, T. W.; GILMORE, C.; TANG, W.; YU, S. B. & SUI, H. J. Conexiones estructurales internas en el complejo tendinoso poplíteo con ligamento cruzado posterior e implicaciones clínicas. *Int. J. Morphol.*, 41(3):953-958, 2023.

RESUMEN: En la actualidad, la relación anatómica entre la porción media del complejo tendinoso poplíteo (CTP) y los tejidos circundantes aún no está clara, especialmente su relación con el ligamento cruzado posterior (LCP). Esto afecta la recons-

trucción anatómica de la lesión del complejo posterolateral (LCP). Se utilizaron un total de 30 casos de articulaciones de rodillas humanas de individuos adultos fijadas con formalina. Se realizaron cortes sagitales en 14 articulaciones de rodilla mediante la técnica de plastinación P45 y disección de 16 casos de articulaciones de rodilla. La sección P45 reveló que la fascia del músculo poplíteo discurría superiormente sobre el margen posterior de la eminencia intercondílea tibial y giraba hacia delante para integrarse en el LCP. Lateralmente, cerca del margen posterior de la platillo tibial lateral, el tendón poplíteo penetra a través de la cápsula articular (CA), donde el tendón poplíteo desprendió hacia arriba dos haces fibrosos densos: uno era el haz de fibras ventral, que corría superiormente sobre el margen posterior de la meseta tibial y luego se movió hacia adelante para conectar con el menisco lateral; el haz de fibras dorsales ascendía directamente y participaba en la CA. Por su parte, la disección del músculo poplíteo mostró que en el margen posterior del platillo del cóndilo lateral de la tibia, en la transición tendón-músculo, el CTP y el AC estaban anclados al LCP.

PALABRAS CLAVE: Rodilla; complejo posterolateral; Complejo del tendón poplíteo; Reconstrucción anatómica; Técnica de plastinación P45.

REFERENCES

- Ahn, J. H.; Wang, J. H.; Lee, S. Y.; Rhyu, I. J.; Suh, D. W. & Jang, K. M. Arthroscopic-assisted anatomical reconstruction of the posterolateral corner of the knee joint. *Knee*, 26(5):1136-42, 2019.
- Bonadio, M. B.; Helito, C. P.; Gury, L. A.; Demange, M. K.; Pecora, J. R. & Angelini, F. J. Correlation between magnetic resonance imaging and physical exam in assessment of injuries to posterolateral corner of the knee. *Acta Ortop. Bras.*, 22(3):124-6, 2014.
- Chuncharunee, A.; Chanthong, P. & Lucksanasomboon, P. The patterns of proximal attachments of the popliteus muscle: Form and function. *Med. Hypotheses*, 78(2):221-4, 2012.
- Crespo, B.; James, E. W.; Metsavaht, L. & LaPrade, R. F. Injuries to posterolateral corner of the knee: a comprehensive review from anatomy to surgical treatment. *Rev. Bras. Ortop.*, 50(4):363-70, 2015.
- Dean, R. S. & LaPrade, R. F. ACL and posterolateral corner injuries. *Curr. Rev. Musculoskelet. Med.*, 13(1):123-32, 2020.
- Djian, P. Posterolateral knee reconstruction. *Orthop. Traumatol. Surg. Res.*, 101(1 Suppl.):S159-70, 2015.
- Fanelli, G. C. & Edson, C. J. Surgical treatment of combined PCL-ACL medial and lateral side injuries (global laxity): surgical technique and 2- to 18-year results. *J. Knee Surg.*, 25(4):307-16, 2012.
- Fanelli, G. C.; Beck, J. D. & Edson, C. J. Combined PCL-ACL lateral and medial side injuries: treatment and results. *Sports Med. Arthrosc. Rev.*, 19(2):120-30, 2011.
- Feipel, V.; Simonnet, M. L. & Rooze, M. The proximal attachments of the popliteus muscle: a quantitative study and clinical significance. *Surg. Radiol. Anat.*, 25(1):58-63, 2003.
- Figueroa, F.; Figueroa, D.; Putnis, S.; Guiloff, R.; Caro, P. & Espregueira-Mendes, J. Posterolateral corner knee injuries: a narrative review. *EFFORT Open Rev.*, 6(8):676-85, 2021.
- Harner, C. D.; Vogrin, T. M.; Hoher, J.; Ma, C. B. & Woo, S. L. Biomechanical analysis of a posterior cruciate ligament reconstruction. Deficiency of the posterolateral structures as a cause of graft failure. *Am. J. Sports Med.*, 28(1):32-9, 2000.

- Jadhav, S. P.; More, S. R.; Riascos, R. F.; Lemos, D. F. & Swischuk, L. E. Comprehensive Review of the Anatomy, Function, and Imaging of the Popliteus and Associated Pathologic Conditions. *Radiographics*, 34(2):496-513, 2014.
- Jiang, W. B.; Li, C.; Sun, S. Z.; Chen, W.; Yu, S. B. & Sui, H. J. P45 technology reveals bow-and-arrow sign in human ankle. *Chin. Med. J.*, 133:1373-4, 2020.
- Kang, K. T.; Koh, Y. G.; Nam, J. H.; Jung, M.; Kim, S. J. & Kim, S. H. Biomechanical evaluation of the influence of posterolateral corner structures on cruciate ligaments forces during simulated gait and squatting. *PLoS One*, 14(4):e0214496, 2019.
- LaPrade, R. F.; Wozniczka, J. K.; Stellmaker, M. P. & Wijdicks, C. A. Analysis of the static function of the popliteus tendon and evaluation of an anatomic reconstruction: the "fifth ligament" of the knee. *Am. J. Sports Med.*, 38:543-9, 2010.
- Mutou, M.; Abe, Y.; Kataoka, H.; Fuzisawa, T. & Takahashi, Y. Anatomical reconstruction of the Posterolateral Corner of the knee preserving dynamic function of the popliteus tendon complex. *Asia Pac. J. Sports Med. Arthrosc. Rehabil. Technol.*, 28:1-5, 2022.
- Natsis, K.; Karasavvidis, T.; Kola, D.; Papadopoulos, S. & Totlis, T. Menisocofibular ligament: how much do we know about this structure of the posterolateral corner of the knee: anatomical study and review of literature. *Surg. Radiol. Anat.*, 42(10):1203-8, 2020.
- Porrino, J.; Sharp, J. W.; Ashimolowo, T. & Dunham, G. An update and comprehensive review of the posterolateral corner of the knee. *Radiol. Clin. North Am.*, 56(6):935-951, 2018.
- Schinhan, M.; Bijak, M.; Unger, E. & Nau T. Electromyographic study of the popliteus muscle in the dynamic stabilization of the posterolateral corner structures of the knee. *Am. J. Sports Med.*, 39(1):173-9, 2011.
- Sui, H. J. & Henry, R. W. Polyester plastination of biological tissue: Hoffen P45 technique. *J. Int. Soc. Plastination*, 22:78-81, 2007.
- Ullrich, K.; Krudwig, W. K. & Witzel, U. Posterolateral aspect and stability of the knee joint. I. Anatomy and function of the popliteus muscle-tendon unit: an anatomical and biomechanical study. *Knee Surg. Sports Traumatol. Arthrosc.*, 10(2):86-90, 2002.
- Wood, A.; Boren, M.; Dodgen, T.; Wagner, R. & Patterson, R. M. Muscular architecture of the popliteus muscle and the basic science implications. *Knee*, 27(2):308-14, 2020.
- Yoon, K. H.; Lee, J. H.; Bae, D. K.; Song, S. J.; Chung, K. Y. & Park, Y. W. Comparison of clinical results of anatomic posterolateral corner reconstruction for posterolateral rotatory instability of the knee with or without popliteal tendon reconstruction. *Am. J. Sports Med.*, 39(11):2421-8, 2011.
- Zabrzynski, J.; Huri, G.; Yataganbaba, A.; Paczesny, L.; Szwedowski, D.; Zabrzynska, A.; Lapaj, L.; Gagat, M.; Wisniewski, M. & Pekala, P. Current concepts on the morphology of popliteus tendon and its clinical implications. *Folia Morphol. (Warsz.)*, 80(3):505-13, 2021.
- Zappia, M.; Reginelli, A.; Chianca, V.; Carfora, M.; Di, Pietto, F.; Iannella, G.; Mariani, P. P.; Di, Salvatore, M.; Bartollino, S.; Maggioletti, N.; et al. MRI of popliteo-menisal fasciculi of the knee: a pictorial review. *Acta Biomed.*, 89(1-5):7-17, 2018.
- Zeng, S. X.; Wu, G. S.; Dang, R. S.; Dong, X. L.; Li, H. H.; Wang, J. F.; Liu, J.; Wang, D.; Huang, H. L. & Guo, X. D. Anatomic study of popliteus complex of the knee in a Chinese population. *Anat. Sci. Int.*, 86(4):213-8, 2011.

Correspondence authors:
Hong-Jin Sui and Sheng-Bo Yu
Department of Anatomy
Dalian Medical University
Dalian 116044
REPUBLIC OF CHINA

Email: Hong-Jin Sui: suihj@hotmail.com
Sheng-Bo Yu: ysbdmu@126.com