

Bilateral Variation of the Vertebral Artery: Report of a Case and its Clinical Implication

Variación Bilateral de la Arteria Vertebral; Reporte de un Caso y su Implicancia Clínica

Verónica Inostroza¹; Paulina Araya¹; Sofía González¹; Oscar Inzunza^{1,2}; Jaritza Tramolao¹ & Emilio Farfán^{1,2}

INOSTROZA, V.; ARAYA, P.; GONZÁLEZ, S.; INZUNZA, O.; TRAMOLAO, J. & FARFÁN, E. Bilateral variation of the vertebral artery. Report of a case and its clinical implication. *Int. J. Morphol.*, 41(3):1015-1019, 2023.

SUMMARY: There are many reports on anatomical variations of the vertebral arteries, which may be related to origin, trajectory, caliber, and side. Bilateral variations are less frequent, however, and less common are bilateral variants that differ from each other. The aim of this work was to report the presence of a bilateral variation of the vertebral artery and its functional and clinical implications. Dissection of a female cadaver, fixed in 10 % buffered formaldehyde, which had not undergone any previous surgeries in the study area and had anatomical variations in both vertebral arteries. In each one, follow-up was done from its origin to its end, determining its trajectory, diameters, branching, and anatomical relations. A left vertebral artery was found, starting in the aortic arch and making a sinuous trajectory of 4 curvatures to enter the transverse foramen of C4. The right vertebral artery began as the first branch of the subclavian artery. Its initial trajectory was rectilinear, followed by a right concave curve, a 360° loop that included a second ascending curve, and ended straight before entering the transverse foramen of C6. The coexistence of bilateral variations in the vertebral arteries is possible. This atypical situation can potentially generate vascular and neurological pathologies, but with different symptoms and causes. Knowing these variations and deliberately searching for them will enable the specialist to make a suitable differential diagnosis.

KEY WORDS: Vertebral artery; Bilateral variation; Loop; Aortic origin.

INTRODUCTION

The vertebral artery (VA) is the first branch of the subclavian artery, in addition to being the branch of greatest caliber, presenting four portions, prevertebral, cervical, atlantic, and intracranial (Moore *et al.*, 2018; Federative International Programme for Anatomical Terminology, 2019), described clinically as V1, V2, V3, and V4 respectively. From their origin, the vertebral arteries have an ascending and oblique trajectory medially. Initially, the pre-vertebral portion travels through the space between the longus colli muscle of the neck and anterior scalene muscle, passing anteriorly to the transverse process of C7 and posteriorly to the common carotid artery, with this portion usually not emitting branches. The cervical portion continues through the transverse foramina from C6 to C1, accompanied by the vertebral venous plexus and a branch of the inferior cervical sympathetic ganglion. This portion is vertical and emits branches for the nerve roots and cervical vertebral marrow, as well as for the musculature of the neck. It is worth noting that the C2 transverse foramen is a relatively short conduit

angled laterally so that its inferior opening is on the horizontal plane. By contrast, its cranial end opens in the parasagittal plane, and therefore at this level the vertebral artery forms a small siphon. The atlantic portion is located medially to the rectus capitis lateralis, curving posteriorly and medially, arranged horizontally on the posterior arch of the atlas and behind the lateral mass. At this level, it does not emit branches. The intracranial portion is superior and medial to enter the endocranium by the foramen magnum, remaining oblique until joined with its contralateral pair. At this level, it emits branches for the meninges and the central nervous system (Rouvière & Delmas, 2005; Standring, 2016).

The literature reports numerous cases of variations of the vertebral artery, which may be referring to origin, trajectory, caliber, and laterality (Orts-Llorca, 1970; Standring, 2016; Tubbs *et al.*, 2016); however, the presence of loops in this artery associated with variations in origin is something atypical.

¹ Departamento de Anatomía, Escuela de Medicina, Pontificia Universidad Católica de Chile, Chile.

² Morpho-Clinical Research Lab, Escuela de Medicina, Pontificia Universidad Católica de Chile, Santiago, Chile.

The aim of this work was to report the presence of a bilateral variation of the vertebral artery, and its functional and clinical implications.

MATERIALS AND METHODS

Two vascular variations are described, encountered during a thorax dissection of a female corpse, Caucasian, 87 years of age at the time of death, fixed in 10 % buffered formaldehyde and conserved in a refrigerated chamber at 4°C, which did not present any prior surgeries in the study area and whose cause of death was cardiorespiratory arrest.

During dissection of the superior mediastinum, 4 branches were detected, originating from the aortic arch. To know more about this variation, a detailed dissection was made of these vessels, leaving them completely exposed. Next, the usual branches of the aortic arch were identified, and the supernumerary artery, the left vertebral artery, was studied. Follow-up was made of this variation from its origin to its end within the transverse foramen of the cervical vertebrae, and it was possible to determine its trajectory, diameters, branching, and anatomical relations. Finally, the same parameters were also studied in the right vertebral artery to understand the case better.

The dissections were done with “ad hoc” surgical supplies. The measurements of the structures involved in the study were taken using a Mitutoyo® digital caliper to an accuracy of 0.01 mm. For photographic recording, an Apple iPhone 14 Pro Max was used, with a 48+12+12 MP camera, and the ImageJ 1.51 j8 software was used to measure the angles.

Ethical approval and consent to participate: The body used for this study was obtained from the donation program of bodies for science at the Pontifical Catholic University of Chile. This program fulfills the World Medical Association’s Declaration of Helsinki and national legal and ethical requirements. This study was approved by Scientific Ethics Committee (CEC) CEC-Seg at the Pontifical Catholic University of Chile (No: 220304004).

RESULTS

A left vertebral artery originating as a third branch of the aortic arch was found between the left common carotid and left subclavian arteries. From its origin, there was an anterior ascending trajectory to the subclavian artery and

medially to the left vagus nerve until arriving at the C4 transverse foramen, where it entered together with the vertebral vein. Its initial trajectory was rectilinear, followed by four curvatures. The first was a left concave curve, the second a right concave, the third a left concave, and the fourth a right concave, to finish straight before entering the C4 foramen transverse without emitting any branches (Fig. 1). The biometric data are in Table I.

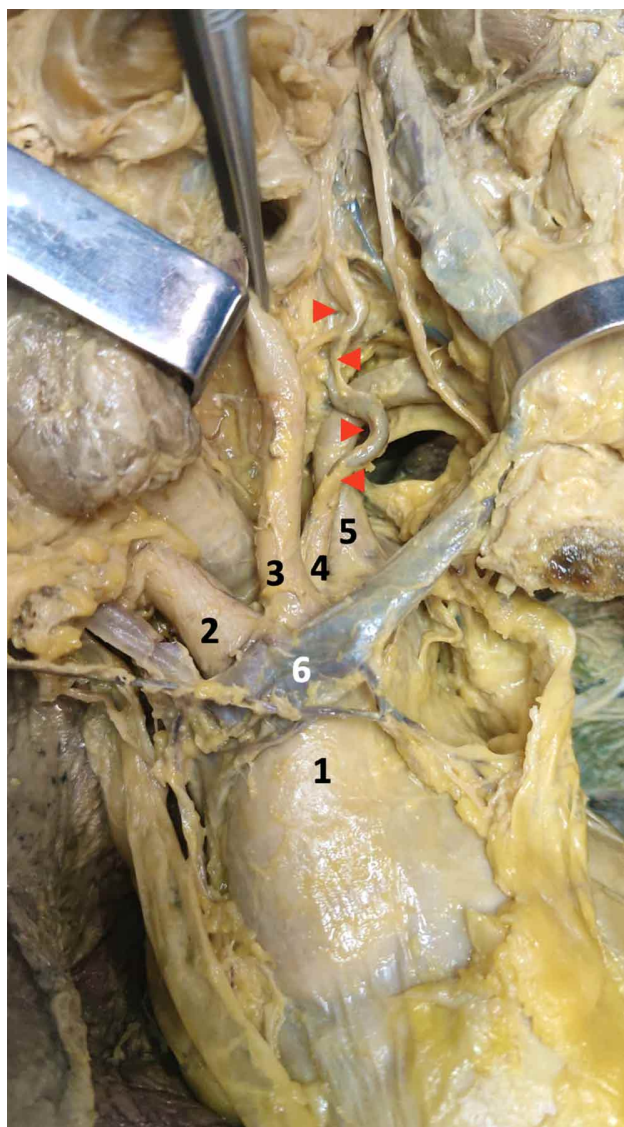


Fig. 1. Dissection of the aortic arch and its branches. 1. Aortic arch; 2. Brachiocephalic trunk; 3. Left common carotid artery; 4. Left vertebral artery; 5. Left subclavian artery; 6. Left brachiocephalic vein. The red arrows indicate the curves of the vertebral artery.

The right vertebral artery originated as the first branch of the subclavian artery, arranged between the anterior scalene muscle and the right lobe of the thyroid gland, anterior to the ventral branch of the eighth cervical vertebral

nerve (C8). From its origin, it ascended anteriorly to the longus colli muscle of the neck and medially to the vertebral vein, arriving at the C6 transverse foramen, where it entered together with the vertebral vein. Its initial trajectory was rectilinear, followed by a right concave curve, a 360° loop that included a second ascending curve and ended straight before entering the C6 transverse foramen without emitting any branches (Fig. 2). The biometric data are in Table I.

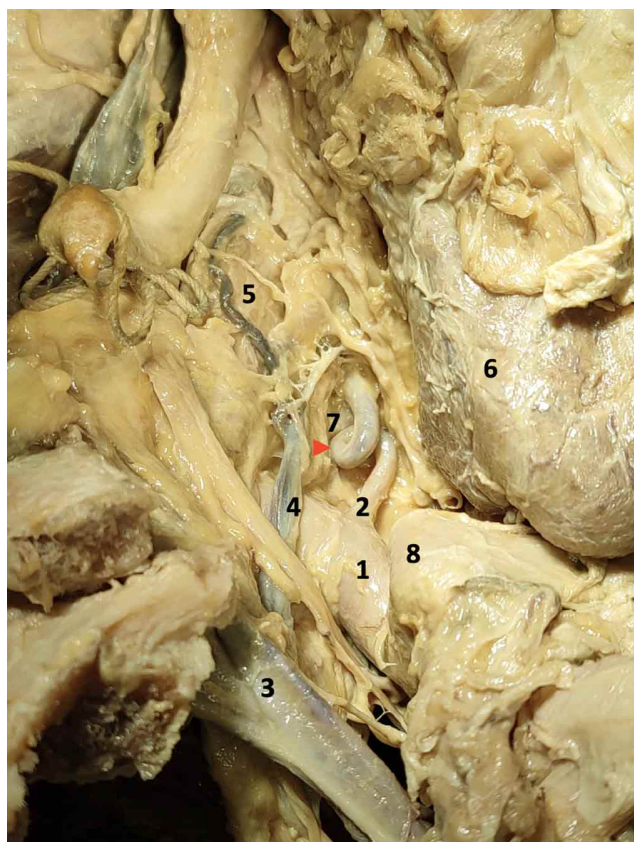


Fig. 2. Dissection of the right subclavian artery at the root of the neck. 1. Right subclavian artery; 2. Right vertebral artery; 3. Right brachiocephalic vein; 4. Right vertebral vein; 5. Right scalene muscle; 6. Right lobe of the thyroid gland; 7. Eighth cervical vertebral nerve; 8. Right common carotid artery. The red arrow indicates the loop of the right vertebral artery.

Table I. Measurements of the prevertebral portion of the VA

Measurements of the prevertebral portion of the VA	VA Right	VA Left
Total length prevertebral portion (mm)	45,44	110,17
Functional length prevertebral portion (mm)	21,59	87,96
Distance between origin and first curve (mm)	6,25	22,22
Cross diameter at the origin (mm)	3,53	4,83
Cross diameter in the middle (mm)	2,11	2,39
Cross diameter at the end (mm)	2,27	3,10
average cross diameter (mm)	2,64	3,44
First curve angle (°)	96	139
Second curve angle (°)	82	114
Third curve angle (°)	*	147
Fourth curve angle (°)	*	124

DISCUSSION

During embryonic development, the vertebral arteries are formed in each antimere from the development of longitudinal anastomoses that connect to the intersegmental arteries, branches of the dorsal aortas. These intersegmental arteries regress, except the seventh, which will form the proximal portion of the subclavian artery, retaining the caudal end of the longitudinal anastomosis, i.e., right at the point of origin of the vertebral artery in the subclavian artery (Inzunza & Burdiles, 2010). Therefore, the origin of the left vertebral artery from the aortic arch could be due to a persistence of the sixth intersegmental artery, which retains the connection with the longitudinal anastomoses (Albayram *et al.*, 2002). This aberrant origin of the vertebral artery is an atypical situation, which, when it occurs, is observed more on the left than on the right and more unilaterally than bilaterally. In particular, the left vertebral artery can have various origins, including the aortic arch, which is observed between 3.1 and 8.3 % of cases. When there is an aortic origin, it has been demonstrated that the entry of the vertebral arteries to the transverse foramen is cranial in the fourth or fifth cervical vertebra (Eskander *et al.*, 2010; Tubbs *et al.*, 2016; Yuan, 2016; Li *et al.*, 2019; Woraputtaporn *et al.*, 2019; Magklara *et al.*, 2021), which is consistent with this case, where it went through the C4 transverse foramen.

On the other hand, vertebral artery loops are considered congenital anomalies of low prevalence, varying between 0.6 and 7.5 % of cases (Chibbaro *et al.*, 2012; Gkekas & Georgakoulis, 2013). When they are present, they are most frequently observed in the prevertebral portion and on the left side, being more prevalent in women, and between the fifth and sixth decade of life (Eksi *et al.*, 2016; Yenigun *et al.*, 2016; Naldemir *et al.*, 2020). Moreover, in a sample of 37 patients with a confirmed vertebral artery loop, there was a distribution of 78.3 % in the prevertebral portion (V1), 21.7 % in the cervical portion (V2) and none in the other two portions (Yenigun *et al.*, 2016). In this case, two anatomical variants of low prevalence appear simultaneously: the aortic origin of the left vertebral artery and the 360° loop in the right vertebral artery, both in the same person, anatomical variants that can give rise to different clinical situations.

Concerning the clinical relevance of these anatomical variations, the patterns of arterial flow, such as the resistance and pulsatility indices, are significantly reduced in the presence of vascular tortuosities like a siphon or loop, which can have a protective

effect for cerebral vascularization (Schubert *et al.*, 2011). On the other hand, the bilateral layout of vertebral arteries with their sinuous trajectory likely provides for a greater range of cervical spine mobility, reducing the negative effect of the movement on the arterial flow. However, negatively, the formation of loops in the vertebral artery can cause other complications, among them bone erosion, intervertebral foramen invasion, neurovascular compression, or vertebrobasilar insufficiency (Doweidar *et al.*, 2014). In this case, the right vertebral artery loop was located anteriorly to the ventral branch of C8, being potentially compressive for this nerve. In fact, loop formations of the vertebral artery can be a rare but potential cause of cervical radiculopathies, and therefore they must be considered as part of the differential diagnosis (Wood *et al.*, 2021; Farshad *et al.*, 2022).

On the other hand, the aberrant origin of the vertebral artery favors hemodynamic alterations, predisposing to cerebrovascular disorders and the formation of intracranial aneurysms (Lazaridis *et al.*, 2018); however, it is not associated with compressive radiculopathies, as can occur with a vertebral artery loop, which contributes to the differential diagnosis. Reasonably, the aberrant origin of the vertebral artery must be considered before undertaking any vascular procedure, for example in the design of vascular prostheses (Yuan, 2016). Hence, it is advisable to deliberately seek such formations in imaging examinations, especially when there is evidence of an enlargement of the intervertebral foramen (Tonsbeek *et al.*, 2020). Moreover, if there is a possibility of a loop formation in the vertebral artery, it is suggested that a magnetic angioresonance or an angiography be performed to confirm the vascular variation (Kim *et al.*, 2010), as well as complementing this with a suitable physical examination.

CONCLUSION

The coexistence of two different anatomical variations in the vertebral arteries in the same individual is possible. This atypical situation can potentially generate vascular neurological pathologies, but with different symptoms and causes. Knowing these variations and deliberately searching for them will enable the specialist to make a suitable differential diagnosis.

FUNDING. This study did not receive any specific sources of financing from the public, private, or not-for-profit sectors.

ACKNOWLEDGMENTS. The authors are grateful to the people who, with great generosity, donate their bodies to science, contributing to the development of new and better professionals.

INOSTROZA, V.; ARAYA, P.; GONZÁLEZ, S.; INZUNZA, O.; TRAMOLAO, J. & FARFÁN, E. Variación bilateral de la arteria vertebral; reporte de un caso y su implicancia clínica. *Int. J. Morphol.*, 41(3):1015-1019, 2023.

RESUMEN: Existen múltiples reportes sobre variaciones anatómicas de las arterias vertebrales, las que se pueden relacionar con origen, trayecto, calibre y lateralidad. Sin embargo, las variaciones bilaterales son menos frecuentes, y menos común es que las variantes bilaterales sean diferentes entre ellas. El objetivo de este trabajo fue reportar la presencia de una variación bilateral de la arteria vertebral y su implicancia funcional y clínica. Disección en un cadáver de sexo femenino, fijado en formaldehído tamponado al 10 %, el cual no presentaba intervenciones quirúrgicas previas en la región de estudio y que tenía variaciones anatómicas en ambas arterias vertebrales. En cada una se realizó seguimiento desde su origen hasta su terminación, pudiendo determinar su trayecto, diámetros, ramificaciones y relaciones anatómicas. Se encontró una arteria vertebral izquierda originada en el arco aórtico, que realizaba un trayecto sinuoso de 4 curvaturas e ingresaba al foramen transverso de C4. La arteria vertebral derecha se originaba como primera rama de la arteria subclavia. Su trayecto inicial era rectilíneo seguido por una curva de concavidad derecha, un loop (giro) de 360° que incluía una segunda curva ascendente y terminaba en dirección recta antes de ingresar al foramen transverso de C6. La coexistencia de variaciones bilaterales en las arterias vertebrales es posible. Esta situación atípica, potencialmente puede generar en la persona patologías neurológicas de origen vascular, pero con sintomatología y causas diferentes. Conocer estas variaciones y realizar una búsqueda intencionada de ellas permitirá al especialista realizar un adecuado diagnóstico diferencial.

PALABRAS CLAVE: Arteria vertebral; Variación bilateral; Loop; Origen aórtico.

REFERENCIAS BIBLIOGRÁFICAS

- Albayram, S.; Gailloud, P. & Wasserman, B. A. Bilateral arch origin of the vertebral artery. *AJNR Am. J. Neuroradiol.*, 23(3):455-8, 2002.
- Chibbaro, S.; Mirone, G.; Yasuda, M.; Marsella, M.; Di Emidio, P. & George, B. Vertebral artery loop--a cause of cervical radiculopathy. *World Neurosurg.*, 78(3-4):375.e11-3, 2012.
- Doweidar, A.; Al-Sayed, S. & Al-Kandery, S. Symptomatic vertebral artery loop: a case report and review of literature. *J. Radiol. Case Rep.*, 8(5):35-41, 2014.
- Eks, i, M. S.; Toktas, Z. O.; Yilmaz, B.; Demir, M. K.; Özcan-Eks, i, E. E.; Bayoumi, A. B.; Yener, Y.; Akakin, A. & Konya, D. Vertebral artery loops in surgical perspective. *Eur. Spine J.*, 25(12):4171-80, 2016.
- Eskander, M. S.; Drew, J. M.; Aubin, M. E.; Marvin, J.; Franklin, P. D.; Eck, J. C.; Patel, N.; Boyle, K. & Connolly, P. J. Vertebral artery anatomy: A review of two hundred fifty magnetic resonance imaging scans. *Spine J.*, 35(23):2035-40, 2010.
- Farshad, M.; Spirig, J. M. & Burkhard, M. D. Anterior artery release, distraction and fusion (ARDF) for radiculopathy caused by a vertebral artery loop. *Eur. Spine J.*, 31(12):3696-702, 2022.
- Federative International Programme for Anatomical Terminology (FIPAT). *Terminologia Anatomica*. Halifax, Dalhousie University, 2019. Disponible en: <https://fipat.library.dal.ca>

- Gkekas, N. & Georgakoulias, N. The medial loop of the V2 segment of the vertebral artery and the importance of this variation in correlation with the resection safe zone and technical characteristics of spinal cages during anterior cervical approaches. *Acta Neurochir. (Wien)*, 155(7):1247-8, 2013.
- Inzunza, H. O. & Burdiles, A. Aberrant left vertebral artery. *Int. J. Morphol.*, 28(1):209-12, 2010.
- Kim, H. S.; Lee, J. H.; Cheh, G. & Lee, S.-H. Cervical radiculopathy caused by vertebral artery loop formation: a case report and review of the literature. *J. Korean Neurosurg. Soc.*, 48(5):465-8, 2010.
- Lazaridis, N.; Piagkou, M.; Loukas, M.; Piperaki, E. T.; Totlis, T.; Noussios, G. & Natsis, K. A systematic classification of the vertebral artery variable origin: clinical and surgical implications. *Surg. Radiol. Anat.*, 40(7):779-97, 2018.
- Li, X.; Guan, L.; Zilundu, P. L. M.; Chen, J.; Chen, Z.; Ma, M.; Zhuang, H.; Zhuang, Z.; Qiu, Y.; Ye, F.; *et al.* The applied anatomy and clinical significance of the proximal, V1 segment of vertebral artery. *Folia Morphol. (Warsz.)*, 78(4):710-9, 2019.
- Magklara, E. P.; Pantelia, E. T.; Solia, E.; Panagouli, E.; Piagkou, M.; Mazarakis, A.; Skandalakis, P.; Troupis, T. & Filippou, D. Vertebral artery variations revised: origin, course, branches and embryonic development. *Folia Morphol. (Warsz.)*, 80(1):1-12, 2021.
- Moore, K. L.; Dalley, A. F. & Agur, A. M. R. *Anatomía con Orientación Clínica*. 8th ed. Philadelphia, Wolters Kluwer, 2018.
- Naldemir, I. F.; Unlu, E. N. & Onbas, O. Tortuous vertebral artery triggering vertebral foramen expansion and radiculopathy in a 19-year-old patient: a case report. *J. Med. Case Rep.*, 14(1):170, 2020.
- Orts-Llorca, F. *Anatomía Humana*. Tomo Primero. Aparato Locomotor. Tronco. Cabeza y Cuello. 4ª ed. Barcelona, Científico-Médica, 1970.
- Rouvière, H. & Delmas, A. *Anatomía Humana Descriptiva. Topográfica y Funcional*. Tomo 3. Miembros. 11st ed. Barcelona, Elsevier Masson, 2005.
- Schubert, T.; Santini, F.; Stalder, A. F.; Bock, J.; Meckel, S.; Bonati, L.; Markl, M. & Wetzel, S. Dampening of blood-flow pulsatility along the carotid siphon: does form follow function? *AJNR Am. J. Neuroradiol.*, 32(6):1107-12, 2011.
- Standring, S. *Gray's Anatomy. The Anatomical Basis of Clinical Practice*. 41st ed. London, Elsevier, 2016.
- Tonsbeek, A. M.; Groen, J. L. & Vleggeert-Lankamp, C. L. A. M. Surgical interventions for cervical radiculopathy caused by a vertebral artery loop: a case report and review of the literature. *World Neurosurg.*, 135:28-34, 2020.
- Tubbs, R. S.; Shoja, M. M. & Loukas, M. *Bergman's Comprehensive Encyclopedia of Human Anatomic Variation*. New Jersey, Wiley Blackwell, 2016.
- Wood, L.; Czyz, M.; Forster, S. & Boszczyk, B. M. The diagnosis and management of a vertebral artery loop causing cervical radiculopathy. *Eur. Spine J.*, 30(12):1-6, 2021.
- Woraputtaporn, W.; Ananteerakul, T.; Iamsaard, S. & Namking, M. Incidence of vertebral artery of aortic arch origin, its level of entry into transverse foramen, length, diameter and clinical significance. *Anat. Sci. Int.*, 94(4):275-9, 2019.
- Yenigun, A.; Ustun, M. E.; Tugrul, S.; Dogan, R. & Ozturan, O. Classification of vertebral artery loop formation and association with cervicogenic dizziness. *J. Laryngol. Otol.*, 130(12):1115-9, 2016.
- Yuan, S. M. Aberrant origin of vertebral artery and its clinical implications. *Braz. J. Cardiovasc. Surg.*, 31(1):52-9, 2016.

Corresponding author:
Dr. Emilio Farfán Cabello
Departamento de Anatomía
Escuela de Medicina
Pontificia Universidad Católica de Chile
Av. Libertador Bernardo O'Higgins #340
Santiago
CHILE

E-mail: efarfanc@uc.cl