

Telocytes in Human Embryonic Development: A Preliminary Microscopic Anatomy Study

Telocitos en el Desarrollo Embrionario Humano: Un Estudio Preliminar de Anatomía Microscópica

Kevin Doello^{1,3,4}; Cristina Mesas^{2,3,4}; Francisco Quiñonero^{2,3,4}; Juan Antonio Mérida-Velasco²;
Gloria Perazzoli^{2,3,4}; Consolación Melguizo^{2,3,4}; Raul Ortiz³ & Jose Prados^{2,4}

DOELLO, K.; MESAS, C.; QUIÑONERO, F.; MÉRIDA-VELASCO, J. A.; PERAZZOLI, G.; MELGUIZO, C.; ORTIZ, R. & PRADOS, J. Telocytes in human embryonic development: A preliminary microscopic anatomy study. *Int. J. Morphol.*, 41(5):1394-1399, 2023.

SUMMARY: Telocytes are a cell population described in 2011 with a multitude of functions such as tissue support, regulation of stem cell niches or intercellular signal transmission. However, there are no studies about their embryonic origin, their function in development, or their moment of appearance. The objective of this work is to try to answer these questions through histological and immunofluorescence studies with samples from the embryological collection of the Department of Anatomy of the University of Granada. In the results obtained, as demonstrated by immunofluorescence for CD34, the presence of these cells can be seen in the fourth week of embryonic development in the perinotochordal region. Its presence is evident from the sixth week of development in a multitude of organs such as the heart, skeletal muscle tissue and supporting tissue of various organs such as the kidney, brain or pericardium. Its function seems to be when the embryonic histological images are analyzed in an evolutionary way, to act as a scaffold or scaffold for the subsequent population by mature tissue elements. In conclusion, telocytes appear at a very early stage of embryonic development and would have a fundamental role in it as scaffolding and directors of organ and tissue growth.

KEY WORDS: Telocytes; Human embryonic development; Microscopic anatomy; CD34; Scaffold.

INTRODUCTION

Telocytes, a cell population discovered by (Popescu & Faussonne-Pellegrini, 2010), have been described in the most diverse tissues from the point of view of ontogeny such as heart, skin or colon, both in different animals and humans (Awad & Ghanem, 2018; Liu *et al.*, 2019; Gandahi *et al.*, 2020; Zurzu *et al.*, 2021). In addition, these cell types have also been detected in tumor tissues (Varga *et al.*, 2019; Aleksandrovykh & Gil, 2021; Díaz-Flores *et al.*, 2023). Morphologically, telocytes are elongated and nucleated cells that are connected by extensions known as telopods (Yang *et al.*, 2023). They are characterized by expressing CD34, CD117 and PDGFR- α , although some authors define them with a single marker as stromal-CD34 positive (Popescu & Faussonne-Pellegrini, 2010; Xu *et al.*, 2019; Díaz-Flores *et al.*, 2021). Various functions such as regulation of tissue stem cell niche, tissue support or transmission of biochemical and

electrical signals have been attributed to telocytes (Babadag & Çelebi-Saltik, 2022). Some studies suggested a role in injury repair, vascular regeneration, and cell communication (Díaz-Flores *et al.*, 2016; Bernier-Latmani *et al.*, 2022). The presence of telocytes in human testicles has been related to blood-testis barrier and angiogenesis process (Marini *et al.*, 2018). In addition, it has been shown that these cells could have their origin in the gastrointestinal stromal tumors (GISTs) and that they would be related to the Cajal interstitial cells that develop nervous functions as constituents of the intestinal myenteric plexus (Rusu *et al.*, 2015; Varga *et al.*, 2019). However, little information is known about the role of telocytes in human embryonic development including organs in which they may be located, time of appearance and functions (Sander, 2002; Medvinsky *et al.*, 2011; Som *et al.*, 2014).

¹ Medical Oncology Service, Virgen de las Nieves Hospital, 18014 Granada, Spain.

² Department of Anatomy and Embryology, University of Granada, Granada 18071, Spain.

³ Institute of Biopathology and Regenerative Medicine (IBIMER), Biomedical Research Center (CIBM), Granada 18100, Spain.

⁴ Instituto de Investigación Biosanitaria de Granada, ibs.GRANADA, Granada 18012, Spain.

Therefore, the objective of this article was to carry out a preliminary study of the presence of telocytes during human embryonic development, their embryological origin and their function.

MATERIAL AND METHOD

Histological sections of human embryos. Histological sections of human embryos were obtained from the embryo histological collection of the Department of Human Anatomy and Embryology (University of Granada) with prior authorization. A detailed study of hematoxylin-eosin stained histological sections of different embryos and stages (Table I) was carried out using a Leica microscope (Wetzlar, Germany).

Table I. Embryos and stages.

Code	Weeks	Days
NOG-1	4	28
SG-1	6	44
EA-3	7	54
AM-1	10	72
X-8	11	79

Immunofluorescence studies. An immunofluorescence study to determine the expression of CD34 was carried out to corroborate the presence of telocytes. In sections, which was exposed to in xylol (5 days) to detach coverslips, were rinsed with PBS, permeabilized with 0.3 % Triton X100 for 15 min and blocked with goat serum for 1 h at room temperature. The sections were incubated with antibodies FITC-conjugated anti-human CD34 (1:100) (BD Biosciences, San Jose, CA, USA; AbCam, Cambridge, UK) for 1 h at room temperature. Finally, after wash with PBS, the nuclei were counterstained using DAPI (Santa Cruz, USA) for 5 min at room temperature. The images were obtained with a photographic microscope (Nikon Eclipse Ni, Melville, USA).

RESULTS

In order to determine the presence of telocytes in human embryos we carried out an immunofluorescence staining in NOG-1 section (4 weeks) showing the existence of a CD34 positive cell populations (CD34 stromal cells/telocytes) distributed homogeneously in the perinotochordal region and in the surrounding regions of the neural tube (Fig.1). This observation was strongly supported by the analysis of the

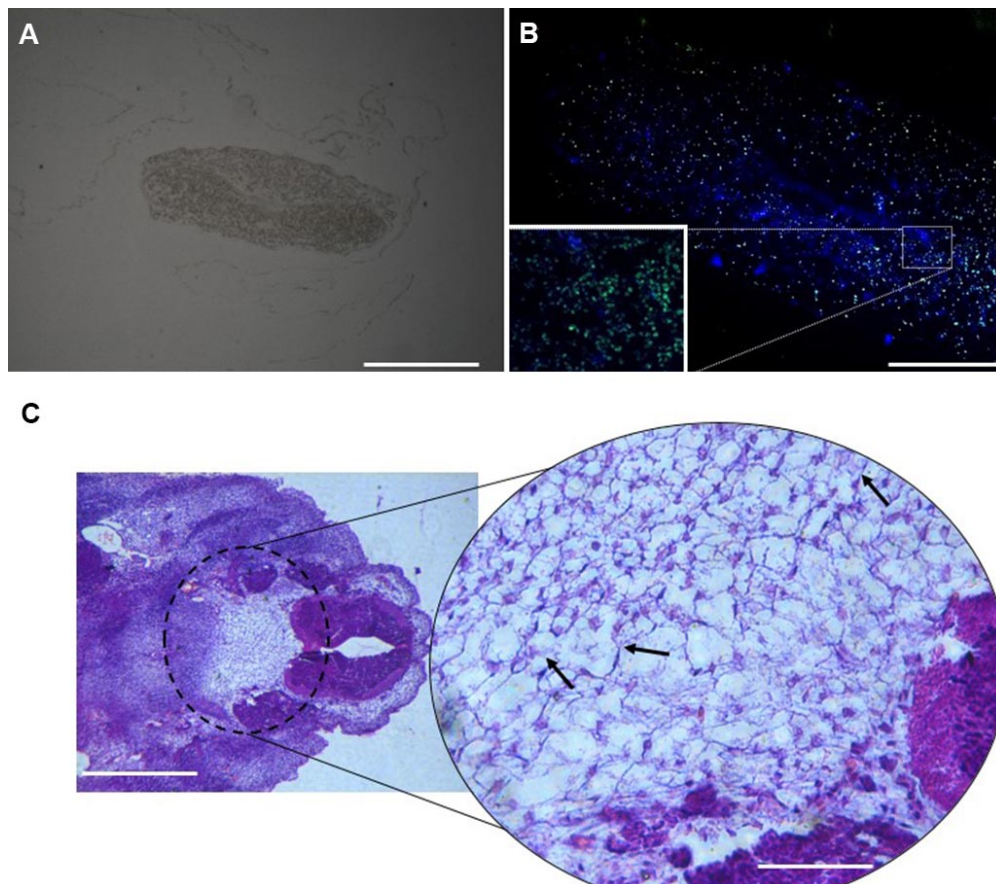


Fig. 1. Telocytes in human embryo. Telocytes in human embryo. A. Human embryo section (NOG-1 section) at the fourth week of development. Scale bar, 500 μm ; B. CD34 immunofluorescence staining (NOG-1 section) showing a positive and homogeneous telocytes population throughout the perinotochordal region and surrounding neural tube. Scale bar, 200 μm . C. Hematoxylin and eosin images of human embryo (SG-1 section) at the sixth week of embryonic development showing the presence of telocytes as elongated cells attached to each other (arrows). Scale bar, 500 μm . Detail of the image (right) Scale bar, 100 μm .

hematoxylin-eosin images at the sixth week of embryonic development showing cells morphologically compatible with telocytes with an elongated morphology and extensions compatible with telopods. Interestingly, these cells were observed in the perinotochordal region next to the neural tube (Fig. 1C)

In the weeks after, telocytes appeared in different regions. In fact, in the seventh week they were observed in the perirenal, pericardial and periencephalic tissue, in the perivertebral region and in the hand subcutaneous tissue

(Fig. 2). In the eleventh week of development, telocytes were observed for the first time in the myocardial and endocardial region (Fig. 2F).

Interestingly, the embryonic supporting tissues with telocytes were populated in the following weeks by other cell types. For example, the perivertebral telocytes observed at the seventh week of development (Fig. 3) were replaced by striated muscle cells that were clearly visible at the tenth week.

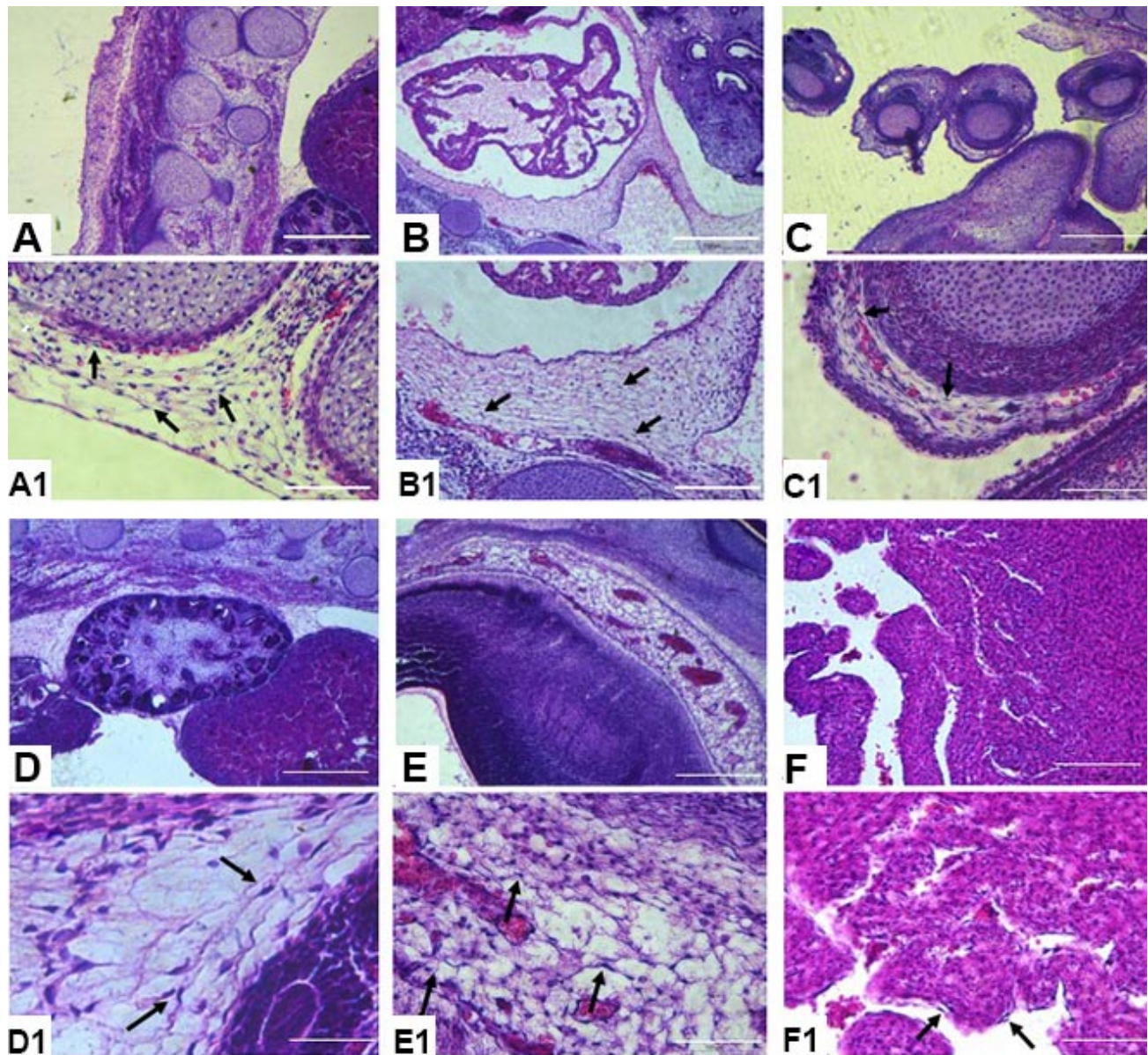


Fig. 2. Hematoxylin-eosin images of human embryo development. Embryo sections from seventh, tenth and eleventh weeks (SG-1, EA-3 and X-8, respectively) were used. A, Perivertebral region; B, Pericardiac tissue; C, Subcutaneous tissue of the hand; D, Perirenal tissue; E, Periencephalic tissue; F, Myocardial and endocardial tissue. Scale bar, 500 μ m and 200 μ m in F. From A1 to F1 show image details of the same tissues. Telocytes appear as elongated cells attached to each other (arrows). Scale bar: 100 μ m in A1, C1, E1 and F1; 200 μ m in B1, and 50 μ m in D1.

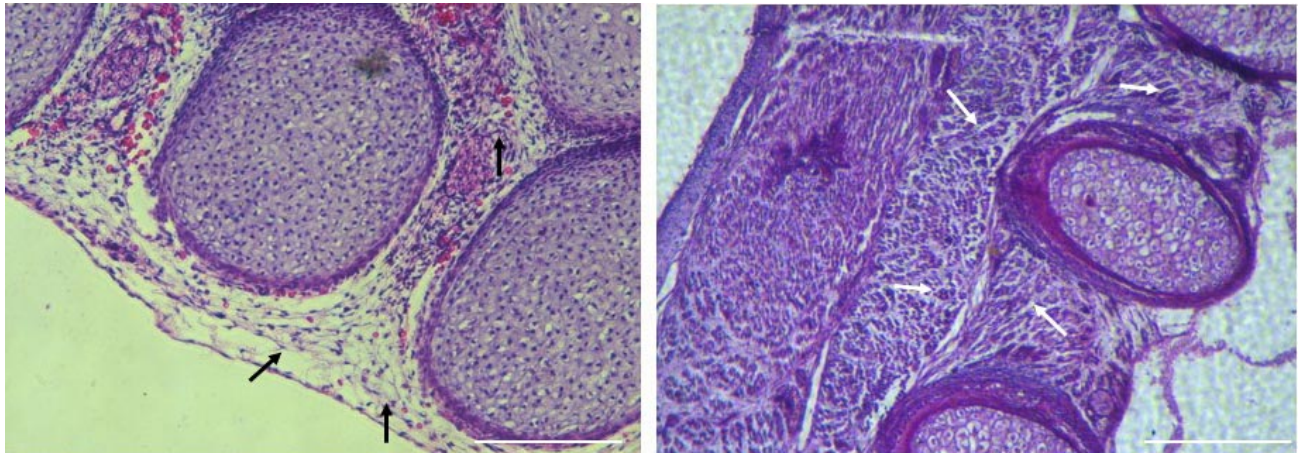


Fig. 3. Hematoxylin-eosin images of human embryo development (vertebral region). Embryo sections from seventh and tenth weeks (EA-3 and AM-1, respectively) were used. A. EA-3 section showing telocytes as elongated cells attached to each other (black arrows). Scale bar, 500 μ m; B. AM-1 section showing striated muscle tissue (white arrows). Scale bar, 200 μ m.

DISCUSSION

Morphologically, the cells detected in the histological analyzes presented are telocytes since they present elongated morphology and extensions compatible with telopods. In fact, articles published by Bani *et al.*, (2010) and Rusu *et al.* (2015) show cells in the embryonic heart between 6-8 weeks morphologically similar to those we described that are positive for CD34, which would reinforce that they are telocytes or CD34 positive stromal cells.

In our study, telocytes were clearly visible from the sixth week of embryonic development in different human embryonic tissues. For example, in the sixth-seventh week of development they were observed in different regions such as perinotochordal or supporting tissues. In the heart of morphological form they were observed in the eleventh week of human embryonic development.

Another remarkable phenomenon to describe is that the supporting tissues at the embryonic level that present telocytes were populated in the subsequent weeks by other cell types. For example, by the seventh week of development, perivertebral telocytes were seen, which were replaced by striated muscle cells by the tenth week. This seems to indicate that telocytes act as a kind of scaffolding during embryonic development that allows the direction and anchoring of other cell populations, thus allowing tissue growth. In tissue engineering, it is usually referred to scaffolds, which are nothing more than biological or synthetic scaffolds where cells settle when artificial tissues are developed (Rahmati *et al.*, 2018; Eltom *et al.*, 2019). In this discipline, the use of scaffolds is essential for the growth and development of these tissues *in vitro* or in bioreactors from stem cells. It is very

likely that telocytes are the natural scaffold that embryonic tissues present and that allows development and growth during this stage. If so, it is possible that these cells in coculture with stem cells could promote the regeneration of damaged organs by helping to direct their growth, development, and regeneration. They could be something like the “Holy Grail of Regenerative Medicine”.

These cells appear very early in embryonic development. When performing immunofluorescence studies with CD34, we observed positivity in human embryos at 4 weeks of development in the perinotochordal region and surrounding neural tube. Undifferentiated embryonic cells do not usually express CD34 but rather other markers such as Nanog, OCT4 or SOX2; while hematopoietic stem cells are not found in this region of the embryo but in the primitive yolk sac or lecytocele (Takahashi & Yamanaka, 2006). For all these reasons, this cellular positivity suggests that they are telocytes or CD34 positive stromal cells. Our hypothesis, taking into account their place of appearance, is that they are mixed cells between ectoderm and mesoderm arising from Hensen's node or primitive pit and that move perinotochordally populating the embryonic tissues progressively (Fig. 4). In addition, to reinforce all this, it should be noted that in the sixth week of development, cells morphologically compatible with telocytes were observed in the perinotochordal region, as shown in the hematoxylin-eosin images.

The biological importance of telocytes in embryonic development is confirmed by the fact that they have been found in lower animals such as the leech or the bee (De

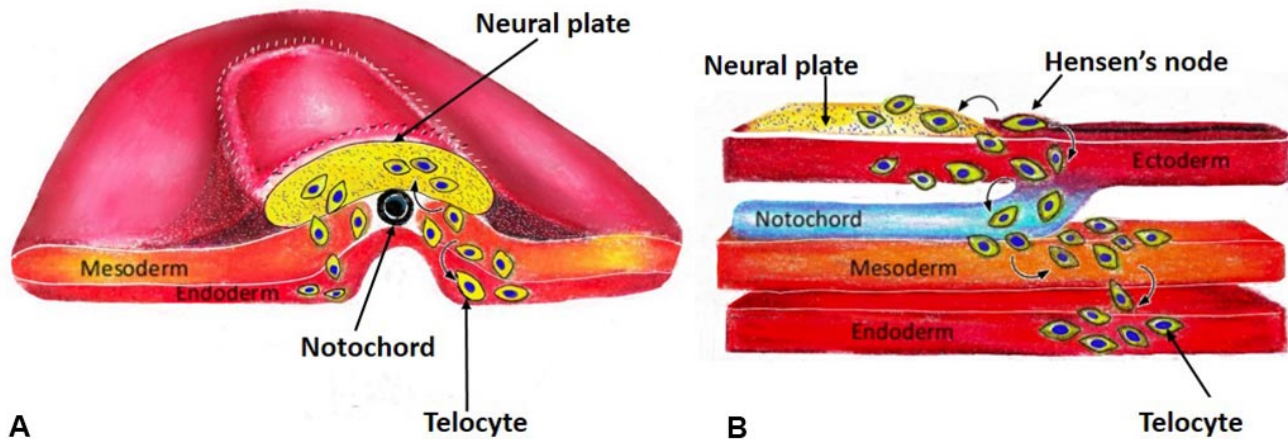


Fig. 4. Schematic representation of the telocyte hypothesis in A) coronal B) sagittal (detail) of an human embryo of 3-4 week of development. Telocytes originate very early in the human embryo (3-4 weeks or earlier) and migrate from Hensen's node in a perinotochordal manner into surrounding tissues such as the ectoderm and neural plate, mesoderm and endoderm.

Paula *et al.*, 2022). If we take into account Ernest Haeckel's phrase "ontogeny is a recapitulation of phylogeny", the presence of these cells in lower animals would justify their presence in early stages of development, which shows that the function of these cells is very likely essential for embryonic development (Pulze *et al.*, 2017).

Finally, in view of our preliminary results, telocytes appear very early in embryonic development at the perinotochordal region and the surrounding neural tube and are replaced by other cell types throughout development. These data allow us to hypothesize that telocytes could be cells between the ectoderm and the mesoderm that arise from Hensen's node or primitive fossa and that move perinotochordally, progressively populating the embryonic tissues (Fig. 4).

CONCLUSION

Telocytes appear very early in human embryonic development (3rd week of development) and are present in a wide variety of tissues, indicating a basic and essential function that could be related to their action as scaffolds and regulators of embryonic stem cells. Most likely, they will be a crucial element in the coming times in the development of disciplines such as tissue engineering and regenerative medicine.

ACKNOWLEDGEMENTS. The authors are grateful to María Dubus Martos for the design of Figure 4.

DOELLO, K.; MESAS, C.; QUIÑONERO, F.; MÉRIDA-VELASCO, J. A.; PERAZZOLI, G.; MELGUIZO, C.; ORTIZ, R. & PRADOS, J. Telocitos en el desarrollo embrionario humano: Un estudio preliminar de anatomía microscópica. *Int. J. Morphol.*, 41(5):1394-1399, 2023.

RESUMEN: Los telocitos son una población celular descrita en 2011 con multitud de funciones como el sostén tisular, la regulación de los nichos de células madre o la transmisión de señales intercelulares. Sin embargo, no existen estudios acerca del origen embrionario de los mismos, su función en el desarrollo ni su momento de aparición. El objetivo de este trabajo es tratar de responder a estos interrogantes mediante estudios histológicos y por inmunofluorescencia con muestras de la colección embriológica del Departamento de Anatomía de la Universidad de Granada. En los resultados se puede observar como se demuestra mediante inmunofluorescencia para CD34, la presencia de estas células en la cuarta semana del desarrollo embrionario en la región perinotocordal. Su presencia se evidencia a partir de la sexta semana del desarrollo en multitud de órganos como corazón, tejidos músculo esqueléticos y tejidos de sostén de diversos órganos como riñón, encéfalo o pericardio. Su función parece ser al ser analizadas las imágenes histológicas embrionarias de forma evolutiva, la de actuar como un andamiaje o scaffold para el posterior poblamiento por elementos tisulares maduros. Como conclusión, los telocitos aparecen en un momento muy precoz del desarrollo embrionario y presentarían una función fundamental en el mismo como andamiajes y directores del crecimiento de los órganos y tejidos.

PALABRAS CLAVE: Telocitos; Desarrollo embrionario humano; Anatomía microscópica; CD34; Andamiaje.

REFERENCES

- Aleksandrovych, V. & Gil, K. Telocytes in the Tumor Microenvironment. *Adv. Exp. Med. Biol.*, 1329:205-16, 2021.
- Awad, M. & Ghanem, M. E. Localization of telocytes in rabbits testis: Histological and immunohistochemical approach. *Microsc. Res. Tech.*, 81(11):1268-74, 2018.
- Babadag, S. & Çelebi-Saltik, B. A cellular regulator of the niche: Telocyte. *Tissue Barriers*, 2131955, 2022.
- Bani, D.; Formigli, L.; Gherghiceanu, M. & Faussone-Pellegrini, M. S. Telocytes as supporting cells for myocardial tissue organization in developing and adult heart. *J. Cell. Mol. Med.*, 14(10):2531-8, 2010.
- Bernier-Latmani, J.; Mauri, C.; Marcone, R.; Renevey, F.; Durot, S.; He, L.; Vanlandewijck, M.; Maclachlan, C.; Davanture, S.; Zamboni, N.; et al. ADAMTS18+ villus tip telocytes maintain a polarized VEGFA signaling domain and fenestrations in nutrient-absorbing intestinal blood vessels. *Nat. Commun.*, 13(1):3983, 2022.
- Díaz-Flores, L.; Gutiérrez, R.; García, M. P.; González-Gómez, M.; Rodríguez-Rodríguez, R.; Hernández-León, N.; Díaz-Flores, L. & Carrasco, J. L. Cd34+ stromal cells/telocytes in normal and pathological skin. *Int. J. Mol. Sci.*, 22(14):7342, 2021.
- Díaz-Flores, L.; Gutiérrez, R.; González-Gómez, M.; Díaz-Flores, L.; Vellido, F.; Rancel, N.; Sáez, F. J. & Madrid, J. F. Telocyte behaviour during inflammation, repair and tumour stroma formation. *Adv. Exp. Med. Biol.*, 913:177-91, 2016.
- Díaz-Flores, L.; Gutiérrez, R.; González-Gómez, M.; García, M. del P.; Palmas, M.; Carrasco, J. L.; Madrid, J. F. & Díaz-Flores, L. Delimiting CD34+ stromal cells/telocytes are resident mesenchymal cells that participate in neovessel formation in skin kaposi sarcoma. *Int. J. Mol. Sci.*, 24(4):3793, 2023.
- Eltom, A.; Zhong, G. & Muhammad, A. *Scaffold Techniques and Designs in Tissue Engineering Functions and Purposes: A Review*. In: *Advances in Materials Science and Engineering*. London, Hindawi Limited, 2019. Available from: <https://go.gale.com/ps/i.do?p=AONE&sw=w&tssn=16878434&v=2.1&it=r&id=GALE%7CA624028353&sid=googleScholar&linkaccess=abs>
- Gandahi, N. S.; Ding, B.; Shi, Y.; Bai, X.; Gandahi, J. A.; Vistro, W. A.; Chen, Q. & Yang, P. Identification of telocytes in the pancreas of turtles—A role in cellular communication. *Int. J. Mol. Sci.*, 21(6):2057, 2020.
- Liu, Y.; Liang, Y.; Wang, S.; Tarique, I.; Vistro, W. A.; Zhang, H.; Haseeb, A.; Gandahi, N. S.; Iqbal, A.; An, T.; et al. Identification and characterization of telocytes in rat testis. *Aging (Albany NY)*, 11(15):5757-68, 2019.
- Marini, M.; Rosa, I.; Guasti, D.; Gacci, M.; Sgambati, E.; Ibba-Manneschi, L. & Manetti, M. Reappraising the microscopic anatomy of human testis: Identification of telocyte networks in the peritubular and intertubular stromal space. *Sci. Rep.*, 8(1):14780, 2018.
- Medvinsky, A.; Rytsov, S. & Taoudi, S. Embryonic origin of the adult hematopoietic system: Advances and questions. *Development*, 138(6):1017-31, 2011.
- Popescu, L. M. & Faussone-Pellegrini, M.-S. TELOCYTES - a case of serendipity: the winding way from Interstitial Cells of Cajal (ICC), via Interstitial Cajal-Like Cells (ICLC) to TELOCYTES. *J. Cell. Mol. Med.*, 14(4):729-40, 2010.
- Rahmati, M.; Pennisi, C. P.; Mobasheri, A. & Mozafari, M. Bioengineered Scaffolds for Stem Cell Applications in Tissue Engineering and Regenerative Medicine. In: Turksen, K. (Ed.). *Cell Biology and Translational Medicine*, Volume 3. *Advances in Experimental Medicine and Biology*. Vol. 1107. Cham, Springer, 2018.
- Rusu, M. C.; Poalelungi, C. V.; Vrapciu, A. D.; Nicolescu, M. I.; Hostiuc, S.; Mogoanta, L. & Taranu, T. Endocardial tip cells in the human embryo – Facts and hypotheses. *PLoS One*, 10(1):e0115853, 2015.
- Sander, K. Ernst Haeckel's ontogenetic recapitulation: Irritation and incentive from 1866 to our time. *Ann. Anat.*, 184(6):523-33, 2002.
- Som, P. M.; Streit, A. & Naidich, T. P. Illustrated review of the embryology and development of the facial region, part 3: an overview of the molecular interactions responsible for facial development. *AJNR Am. J. Neuroradiol.*, 35(2):223-9, 2014.
- Takahashi, K. & Yamanaka, S. Induction of pluripotent stem cells from mouse embryonic and adult fibroblast cultures by defined factors. *Cell*, 126(4):663-76, 2006.
- Varga, I.; Polák, S.; Kyselovic, J.; Kachlík, D.; Danisovic, L. & Klein, M. Recently discovered interstitial cell population of telocytes: distinguishing facts from fiction regarding their role in the pathogenesis of diverse diseases called "telocytopathies". *Medicina (Kaunas)*, 55(2):56, 2019.
- Xu, Y.; Tian, H.; Cheng, J.; Liang, S.; Li, T. & Liu, J. Immunohistochemical biomarkers and distribution of telocytes in ApoE^{-/-} mice. *Cell Biol. Int.*, 43(11):1286-95, 2019.
- Yang, D.; Yuan, L.; Chen, S.; Zhang, Y.; Ma, X.; Xing, Y. & Song, J. Morphological and histochemical identification of telocytes in adult yak epididymis. *Sci. Rep.*, 13(1):5295, 2023.
- Zurzu, M.; Nicolescu, M. I.; Mogoanta, L.; Pantea, S. & Rusu, M. C. Telocytes and lymphatics of the human colon. *Life*, 11(10):1001, 2021.

Corresponding authors:

Raul Ortiz
Department of Anatomy and Embryology
University of Granada
Granada 18071
SPAIN

E-mail: roquesa@ugr.es

Corresponding author:

Jose Prados
Department of Anatomy and Embryology
University of Granada
Granada 18071
SPAIN

E-mail: jcprados@ugr.es