

Interleukin-37 has A Promising Cardioprotective Effect on Isoproterenol-Induced Myocardial Infarction

La Interleucina-37 tiene un Efecto Cardioprotector Prometedor sobre el Infarto de Miocardio Inducido por Isoproterenol

Hany A. Elkattawy^{1,2}; Ahmed El-Sayed Hassan^{2,3}; Amira Ebrahim Alsemeh⁴; Ola A. Abdelwahab⁴; Mamdouh Eldesoqui^{1,5}; Mohamed El-Sherbiny^{1,5}; Hasnaa Ali Ebrahim⁶; Nermine Samir Nosseir⁷; Vishnu Priya Veeraraghavan⁸; Mohamed Ghazala⁹; Mohammed A. Attia^{1,10} & Shima Hadhoud²

ELKATTAWY, H. A.; EL-SAYED HASSAN, A. E.; EBRAHIM, A. A.; ABDELWAHAB, O. A.; ELDESOQUI, M.; EL-SHERBINY, M.; EBRAHIM, H. A.; NOSSEIR, N. S.; VEERARAGHAVAN, V. P.; GHAZALA, M.; ATTIA, M. A.; HADHOUD, S. Interleukin-37 has A promising cardioprotective effect on isoproterenol-induced myocardial infarction. *Int. J. Morphol.*, 41(5):1427-1438, 2023.

SUMMARY: The main cause of mortality and disability globally is myocardial infarction (MI). Isoproterenol (ISO), a β -adrenoceptor agonist, has been used to induce rat myocardial necrosis. Whereas interleukin-37 (IL-37) has anti-inflammatory and cytoprotective properties. The study aimed to investigate the potential protective effects of IL-37 administration on cardiac architecture, oxidative stress, and inflammatory markers during ISO-induced MI in rats. Three groups of adult male rats were used in this study, the normal control group (n=8), ISO-induced MI group (n=8) that received isoproterenol hydrochloride (ISO) (100 mg/kg/day, SC, for the first 2 consecutive days), and IL-37-treated group (ISO+IL-37) (n=8) that received recombinant human IL-37 (40 μ g/kg /day, intraperitoneally, for 2 weeks during and after ISO injections. Heart rate (HR.) and ECG changes were monitored. Some oxidative stress markers such as superoxide dismutase (SOD), nitric oxide (NOx), malondialdehyde (MDA), and glutathione (GSH) tissue levels in the tissue homogenate were assayed. Interleukin-6 (IL-6), tumor necrosis factor- α (TNF- α), caspase-8, P53, and C-reactive protein (CRP) were among the inflammatory markers examined. In addition, serum levels of creatinine kinase (CK-MB) and lactate dehydrogenase (LDH) were analyzed to evaluate the myocardial injury. For histological analysis, tissues were sectioned, fixed in paraffin, and stained with hematoxylin and eosin (H&E), Masson Trichrome and immunohistochemical against NF- κ B, TNF- α , and Caspase-9. IL-37 improved ECG changes, cardiac enzyme markers, and some inflammatory markers of oxidative stress in ISO-induced MI. It also improved the histopathological and immunohistochemical changes in MI. In conclusion: IL-37 might be a promising therapeutic modality in myocardial infarction.

KEY WORDS: IL-37; Isoproterenol; Myocardial; Infarction; Rats.

INTRODUCTION

Cardiovascular disease (CVD) is a serious global health concern that has grown to epidemic levels in limited nations, accounting for 78 % of all deaths. The prevalence of CVD has dropped in developed nations due to the application

of efficient preventative and treatment measures (Kopeček *et al.*, 2016), even though, sedentary habits, obesity, and diabetes mellitus continue to jeopardize these benefits from efficient treatment methods (Patel & Mehta, 2013).

¹ Department of Basic Medical Sciences, College of Medicine, AlMaarefa University, PO Box 71666, Riyadh, Saudi Arabia.

² Department of Medical Physiology, College of Medicine, Zagazig University, Egypt.

³ Department of Basic Medical Sciences, College of Medicine, Sulaiman Al Rajhi University, Qassim, Saudi Arabia.

⁴ Department of Human Anatomy and Embryology, College of Medicine, Zagazig University, Egypt.

⁵ Department of Anatomy and Embryology, Faculty of Medicine, Mansoura University, P.O. Box 35516, Mansoura, Egypt.

⁶ Department of Basic Medical Sciences, College of Medicine, Princess Nourah bint Abdulrahman University, P.O. Box 84428, Riyadh 11671, Saudi Arabia.

⁷ Department of Biomedical Sciences, College of Medicine, Gulf Medical University (GMU), United Arab Emirates and Anatomy Department, College of Medicine, Suez University, Egypt.

⁸ Centre of Molecular Medicine and Diagnostics, Saveetha Dental College and Hospitals, Saveetha Institute of Medical and Technical Sciences, Saveetha University, Chennai, India.

⁹ Department of Clinical Sciences, College of Medicine, Sulaiman Al-Rajhi University, Al-Bukairiyah, Saudi Arabia.

¹⁰ Department of Clinical Pharmacology, Faculty of Medicine, Mansoura University, 35516, Mansoura, Egypt.

Even though myocardial infarction treatment has evolved significantly over the last few years, most current medications were created without clear molecular targets (Goyal & Mehta, 2013). Nevertheless, Many therapeutic pathways have been established due to an increased understanding of the biochemical and cellular changes that occur in myocardial infarction (Patel & Mehta, 2012).

Acute myocardial infarction can result in severe myocardial ischemia, which activates autoimmunity and draws a lot of inflammatory cells to the region of the infarction, and produces a lot of cytokines involved in the inflammatory response (Kain *et al.*, 2014). It has been shown that excessive inflammatory cytokines harm myocardial cells, speed up myocardial cell apoptosis, and subsequently decrease cardiac function (Liu *et al.*, 2016). A large influx of inflammatory cells may also release a lot of inflammatory mediators to contribute to inflammation. These inflammatory mediators contribute to the necrosis and apoptosis of cardiac cells as well as the dysfunction of endothelial cells (Hori & Nishida, 2009).

In the current study, we focused on interleukin (IL)-37 as a therapeutic candidate in myocardial infarction using the isoproterenol (ISO)-induced myocardial infarction rat model. Isoproterenol is a synthetic catecholamine that rapidly produces oxidative products leading to the cellular impairment detected in myocardial hypoxia, acute coronary insufficiency, angina, and subendocardial infarct (Zhuang *et al.*, 2017).

Interleukin-37 is a member of the IL-1 family that contains both pro-inflammatory cytokines such as IL-1 α , IL-18, IL-33, and IL-36, and anti-inflammatory members like IL-37 and IL-38 (Cecilia *et al.*, 2013). IL-37 is a major inhibitor of both innate and acquired immune responses (Nold *et al.*, 2010). Animals that overexpress IL-37 are protected from colitis, hepatitis, and endotoxic shock (Nold *et al.*, 2010; McNamee *et al.*, 2011). IL-37 improves the inflammation and immune reactions in psoriasis (Teng *et al.*, 2014). IL-37 is secreted by dendritic cells, macrophages, endothelial, and smooth muscle cells (Busfield *et al.*, 2000; Boraschi *et al.*, 2011). IL-37 controls the differentiation of several immune cells and suppresses innate inflammation (Dinarello *et al.*, 2016). The advancement of cardiovascular disorders may be associated with IL-37 (Zhuang *et al.*, 2017). It was determined that individuals with acute myocardial infarction have increased amounts of IL-37 in their blood (Ji *et al.*, 2014). The purpose of this research is to assess IL-37's impact on myocardial infarction in rat experimental models by investigating cardiac function, cardiac microscopic architecture, and its anti-inflammatory, anti-fibrotic, and anti-oxidative mechanisms.

MATERIAL AND METHOD

The experimental animals. Twenty-four male adult Wistar rats (weighing 160–210 g) were obtained from the Faculty of Veterinary Medicine's animal house, Zagazig. The experimental animals were housed in steel wire cages (3–4 per cage) at room temperature, on a natural light/dark cycle, with unrestricted access to food and water. The animals were acclimated to their environment for one week prior to the initiation of the studies. Appropriate animal health and well-being indicators were continuously monitored, and the College of Medicine Ethics Committee at Zagazig University has approved the procedures for using animals in research (Approval number: ZU-IACUC/3/F/107/2022).

Chemicals. Recombinant human IL-37 was obtained from (Adipogen AG, Liestal, Switzerland). Unless otherwise specified, Sigma-Aldrich Chemical Co. provided the kits, chemicals, and reagents utilized in this investigation (St. Louis, MO, USA).

Induction of Experimental MI. Isoproterenol hydrochloride was dissolved in normal saline (100 mg/kg), then the rats were SC injected for two next days. The used dose was selected in accordance with prior research (Rayabarapu & Patel, 2014). Elevated levels of blood creatine kinase-MB (CK-MB) and lactate dehydrogenase (LDH) in rats indicated ISO-induced MI.

Animal Grouping and Experimental Protocol. Twenty-four male (Wistar) albino rats were randomly divided into three groups. Group I (normal control; n=8): animals received 200 μ l normal saline; intraperitoneally (vehicle) for two weeks. Group II (ISO; n=8): animals received 200 μ l of normal saline (vehicle) intraperitoneally for two weeks during and after receiving isoproterenol hydrochloride (ISO) subcutaneously (100 mg/kg/day, SC, for the first 2 consecutive days for induction of MI). Group III (ISO+IL-37; n=8): animals received recombinant human IL-37 (40 μ g/kg/day), dissolved in 200 μ l normal saline and injected intraperitoneally (Cavalli *et al.*, 2016) for 2 weeks during and after the administration of ISO (100 mg/kg/day, SC, for the first 2 days).

ECG monitoring. The rats were weighed, an electrocardiogram (ECG), and blood samples were taken at the end of the two-week period. Thiopental (45 mg/kg, i.p.) was used to anesthetize the animals, and they were maintained warm using a heating light to prevent hypothermia. Peripheral limb electrode needles were implanted subcutaneously into each rat's forepaw pads and tail. ECG was recorded and analyzed. The data was collected with a Power Lab System (4/3 with bridge amplifier) and analyzed with Lab Chart Pro

software (AD Instruments Pty Ltd, New South Wales, Australia) to determine heart rate (HR.) and ECG changes.

Biochemical assessment. After rats were euthanized, blood was collected for biochemical analysis as previously described (Qian *et al.*, 2019). The hearts were dissected, washed, dried, and weighed. The Heart Weight Index (HWI) was calculated (heart weight in milligrams to body weight in grams ratio). For the biochemical assessment, one portion of the heart was mixed with a 10 % (w/v) homogenate in phosphate buffer (pH 7.4) according to previously mentioned technique (Goyal *et al.*, 2015). The cardiac homogenate was prepared to assay the oxidative stress biomarkers following Rayabarapu & Patel (2014). The superoxide dismutase (SOD) (Cat. No. 19160), nitric oxide (NOx) (Cat. No. MAK454), malondialdehyde (MDA) (Cat. No. MAK085), and glutathione (GSH) (Cat.No.MAK453) tissue levels were assessed spectrophotometrically according to directions of the used assay kits (Sigma-Aldrich Chemical Co., St. Louis, MO, USA). Standard commercial enzyme-linked immunosorbent assays (ELISA) kits from Sigma-Aldrich Chemical Co. (St. Louis, MO, USA) were used to measure serum levels of tissue inflammatory markers [interleukin-6 (IL-6) (Cat. No. RAB0311), tumor necrosis factor- α (TNF- α) (Cat. No. RAB0479), and C- reactive protein (CRP) (Cat. No. RAB0097). Moreover, the serum levels of creatine kinase (CK-MB) and lactate dehydrogenase (LDH) were assessed by ELISA kits to evaluate the myocardial damage. The cardiac apoptotic markers p53 was measured in tissue using sandwich ELISA kits (Cat. No. ERA47RB, Thermo Fisher Co., Waltham, Massachusetts, U.S.) together with caspase-8 (cat No ab39700, Abcam, USA) according to the manufacturer's instructions.

Histopathologic evaluation of cardiac injury

Light microscopic study. The heart tissues were fixed in 10 % formalin followed by histological processing and paraffin wax encasement. Then, 5 μ m longitudinal sections of the left ventricular myocardium were stained by Masson trichrome and Hematoxylin and Eosin (H&E) for histopathological examination.

Immunohistochemical study. Paraffin tissue sections 4 μ m were prepared and immunohistochemically stained according to the avidin-biotin complex (ABC) immunoperoxidase technique for the localization of NF- κ B, TNF- α , and Caspase-9. The slides were washed with hydrogen peroxide and incubated with the primary rabbit polyclonal antibody against NF- κ B (p65) (Labvision, Thermo scientific, USA, RB-1638, 1:100 dilution) and TNF- α (Abcam Cambridge, MA, USA, ab9635, 1:100 dilution) and caspase-9 (Abcam Cambridge, MA, USA, ab202068,

1:100 dilution). Diaminobenzidine chromogen was applied for 5 minutes to the slides to visualize the immunoreaction 18. A light microscope (The Leica DM500 microscope) with a digital camera (Leica ICC50 W Camera Modul, D) was used to examine the slides.

Morphometrical study. Cardiomyocyte diameters in hematoxylin and eosin-stained sections among all groups were measured throughout the nucleus-corresponding area. Only longitudinally cut cardiomyocytes with visible nuclei and cellular boundaries were considered for the analysis (Kangussu *et al.*, 2021). Area % of collagen fibers, NF- κ B, TNF α , immunoreactions were also estimated using (ImageJ) computer software for image analysis (Wayne Rasband, NIH, Bethesda, Maryland, USA).

Statistical analysis. Of the collected data was performed utilizing SPSS version 26 and GraphPad Prism version 9. Using the Kolmogorov-Smirnov and Bartlett tests, the normality and homogeneity of the variance of all the data were determined. The results are reported as mean \pm SD, and statistical significance was established using one-way ANOVA and Tukey's *post hoc* test. All statistical tests had a fixed significance level of $p < 0.05$.

RESULTS

IL-37 improved Cardiac weight index and ECG modifications in ISO-induced IM. Our results showed a significant increase in heart weight index (HWI) in the cardiac ischemic group (ISO-treated) compared to the control group, indicating hypertrophy. However, IL-37 treatment significantly improved the HWI alleviating ISO effects. Moreover, the ISO group exhibited a significant increase in HR, T wave inversion, QTc interval prolongation, wide QRS (demonstrating ischemia and conduction defects), and significant ST-segment depression (indicating the progression of ischemia-induced MI). Contrarywise, IL-37 treatment improved ECG abnormalities secondary to ISO delivery, as shown in Table I.

Biochemical parameters

IL-37 treatment improved cardiac enzyme markers in MI. As shown in Table II, the two days of administration of ISO led to a significant elevation in the serum LDH and CK- MB, respectively, in the cardiac ischemic group (ISO-treated) compared to the control group. Conversely, IL-37 treatment (2 μ g/kg/day, intraperitoneally) normalized the serum LDH and CK- MB levels in the cardiac ischemic+ IL-37 group.

Table I. Impact of IL-37 therapy on HWI and ECG alterations in rats with ISO-induced MI.

Parameter	Control Group (n=8)	ISO Group (n=8)	ISO+IL-37 Group (n=8)
HWI (mg/g)	3.42 ± 0.18	4.92 ± 0.26 *	3.53 ± 0.27 #
Heart rate (bpm)	311.71 ± 14.8	391.41 ± 15.6 *	379.6 ± 12.64 *
ST-height amplitude (mV)	0.039 ± 0.008	-0.14 ± 0.007 *	0.028 ± 0.005 #
T wave amplitude (mV)	0.107 ± 0.008	-0.019 ± 0.003 *	0.018 ± 0.004 *
QTc (ms)	130.1 ± 5.2	278.4 ± 5.9 *	138.6 ± 5.8 #
QRS duration (ms)	23.1 ± 1.8	29.1 ± 1.7	23.7 ± 1.4 #

Values expressed as mean ± SD, * Significance versus the control group at p<0.05. #Significance versus the ISO group at p<0.05

Table II. Effect of IL-37 treatment on cardiac enzymes and lipid profile among the studied group's.

Parameter	Control Group (n=8)	ISO Group (n=8)	ISO+IL-37 Group (n=8)
LDH (IU/L)	610.20 ± 40.10	1420.15 ± 43.93 *	650.40 ± 41.20 #
CK- MB (IU/L)	512.31 ± 24.30	1286.25 ± 29.90 *	625.12 ± 25.3 #
TC (mg/dl)	108.26 ± 7.38	194 ± 21.65*	122 ± 16.3#
HDL-C (mg/dl)	54.21 ± 4.72	35 ± 3.82*	45 ± 4.56#
LDL-C (mg/dl)	42.32 ± 7.61	110 ± 14.61*	56 ± 11.54#
TG (mg/dl)	85.42 ± 15.35	142 ± 17.23*	96 ± 12.64#

Values expressed as mean ± SD, * Significance versus the control group at p<0.05. # Significance versus the ISO group at p<0.05

IL-37 treatment improved inflammatory markers in MI. The ISO group revealed a significant elevation of the inflammatory markers (TNF-α, IL-6, and CRP) in the cardiac ischemic group (ISO-treated) versus the control group. However, compared to the ISO-treated group, their levels were considerably lower after IL-37 therapy as shown in Figure 1.

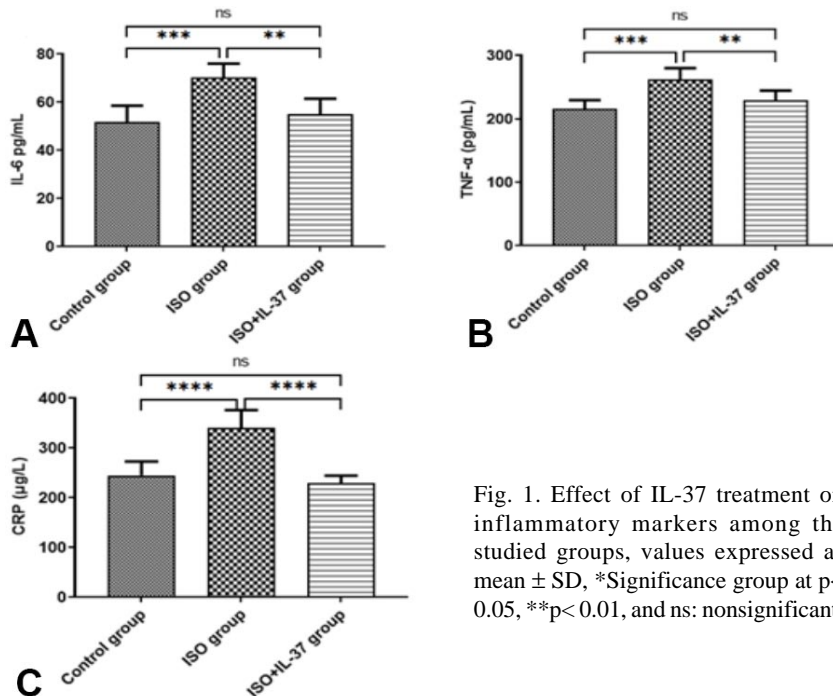


Fig. 1. Effect of IL-37 treatment on inflammatory markers among the studied groups, values expressed as mean ± SD, *Significance group at p<0.05, **p<0.01, and ns: nonsignificant.

IL-37 treatment improved oxidative stress markers in MI. Regarding oxidative stress markers, the administration of ISO significantly increased cardiac MDA and NOx content with a reduction in myocardial GSH, GPx, and SOD in comparison to the control group. Interestingly, IL-37 treatment succeeded in normalizing MDA and NOx tissue content and improved GSH content, GPx, and SOD activities compared to the cardiac ischemic group, as shown in Figure 2.

IL-37 treatment ameliorated apoptotic markers in MI. ISO significantly increased the myocardial p53, and caspase-8 content in the cardiac ischemic group (ISO-treated) compared to the control group. However, treatment with IL-37 ameliorated the p53 and caspase-8 contents, as shown in Figure 3.

IL-37 treatment ameliorated lipid profile in MI. ISO significantly increased the total cholesterol (TC), low-density lipoprotein cholesterol (LDL-C), and triglyceride (TG) serum

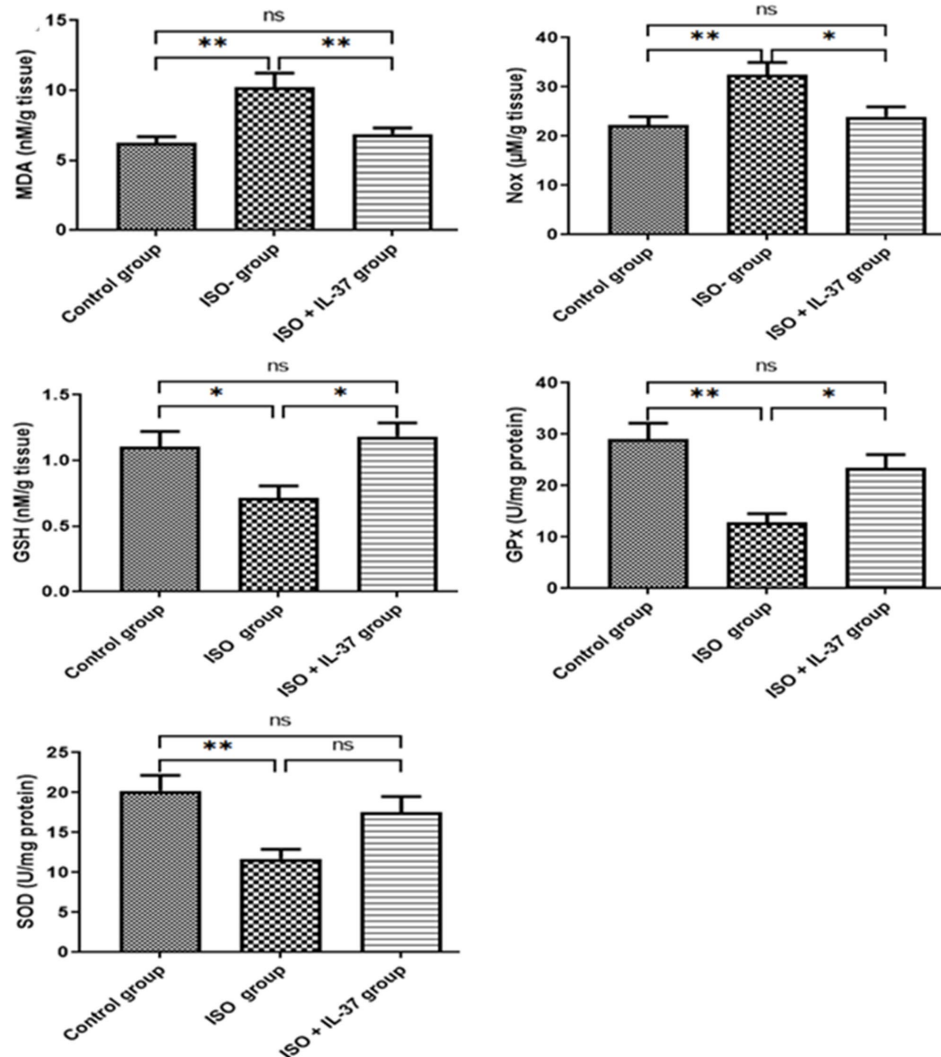


Fig. 2. The effect of IL-37 therapy on oxidative stress indicators among the studied groups, values expressed as mean \pm SD, * Significance group at $p < 0.05$, ** $p < 0.01$, and ns: nonsignificant.

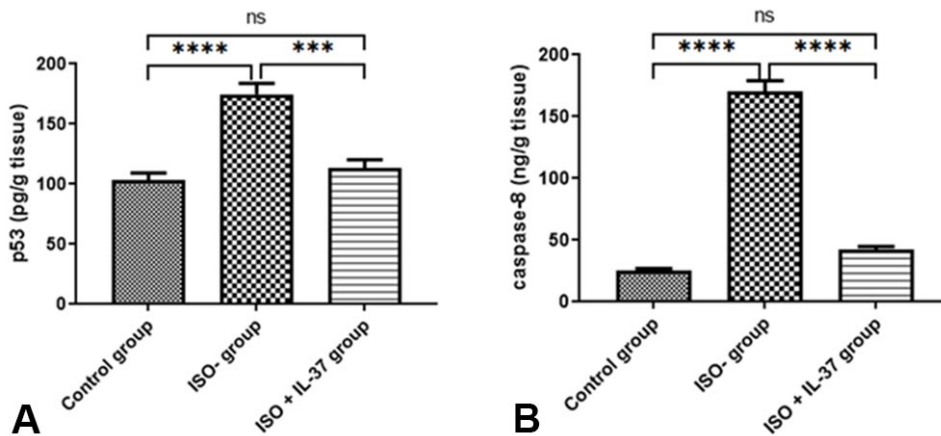


Fig. 3. Effect of IL-37 treatment on apoptotic markers among the studied groups, values expressed as mean \pm SD, Significance group at $p < 0.05$, ** $p < 0.01$, and ns: nonsignificant.

levels while decreasing high-density lipoprotein cholesterol (HDL-C) in the cardiac ischemic group (ISO-treated) compared to the control group. However, IL-37 treatment ameliorated approximately succeeded in normalizing the lipid profile in the (ISO+IL37) group, as shown in Table II.

IL-37 treatment improved histological and immunohistochemical changes in MI.

Sections stained with Hematoxylin and Eosin revealed that the control group exhibited normal histological character; parallel myocardial fibers had branching with an anastomosing pattern, central oval vesicular nuclei, and visible intercalated discs. Fibroblasts with elongated dark nuclei and blood capillaries were seen in the interstitial space between the cardiac muscle fibers (Fig. 4a).

Cardiac ischemic group (ISO treated), H&E-stained myocardial sections showed marked histologic changes in the ventricular myocardium in the form of disorganized myocardial fibers with pyknotic nuclei, absence of the intercalated discs and widening of the interstitial spaces showed mononuclear cellular infiltration, red blood cells, and prominent fibrous tissue. Also, congested blood capillaries and hemorrhage within the myocardial fibers were seen. Some intensely eosinophilic, fragmented, and wavy myocardial fibers were seen. Also, cytolysis of myocardial fibers was observed (Fig. 4b-d). In the

Cardiac ischemic+ IL-37 group, most of the normal histological features of the myocardium were restored; there were parallel myocardial fibers with branching and anastomosing patterns, central oval vesicular nuclei, and visible intercalated discs. Less widened interstitial spaces, some congested capillaries, and pyknotic nuclei were still seen (Fig. 4e).

Masson's trichrome staining was performed to detect the fibrotic changes in the different experimental groups, as shown in Figure 5. The Control group revealed scanty blue collagen fibers in interstitial space (Fig. 5a). In contrast, the cardiac ischemic group exhibited abundant basophilic collagen fibers in interstitial space and around the blood vessels (Fig. 5b-c). Interestingly, in the Cardiac ischemic+IL-37 group, few basophilic collagen fibers in interstitial space and around the blood vessels were observed compared to the cardiac ischemic group (Fig. 5d). These results were confirmed morphometrically and statistically as a percentage

of collagen fiber distribution. In the cardiac ischemic group revealed a significant increase compared to the control group at $P < 0.05$. However, the area % of collagen fibers in the Cardiac ischemic+ IL-37 group exhibited a significant decrement compared to the Cardiac ischemic group but still revealed a significant difference from the control group at $P < 0.05$ (Fig. 5e).

Immunohistochemical results: Assessment of the NF-KB, TNF- α , and caspase-9 immunoexpression in cardiac tissue revealed negative to weak expression in the control group (Fig. 6a, 7a, 8a), strong expression in the cardiac ischemic group (Fig. 6b, 7b, 8b), and weak to moderate expression of the three proteins in the cardiac ischemic +IL37 group (Fig. 6c, 7c, 8c). The immunoexpression of the proteins NF-KB, TNF- a, and caspase-9 was significantly higher in the cardiac ischemia group compared to the control group and significantly lower in the cardiac is-chemic +IL37 group compared to the cardiac ischemic group at $P < 0.05$. (Fig. 6d, 7d, 8d).

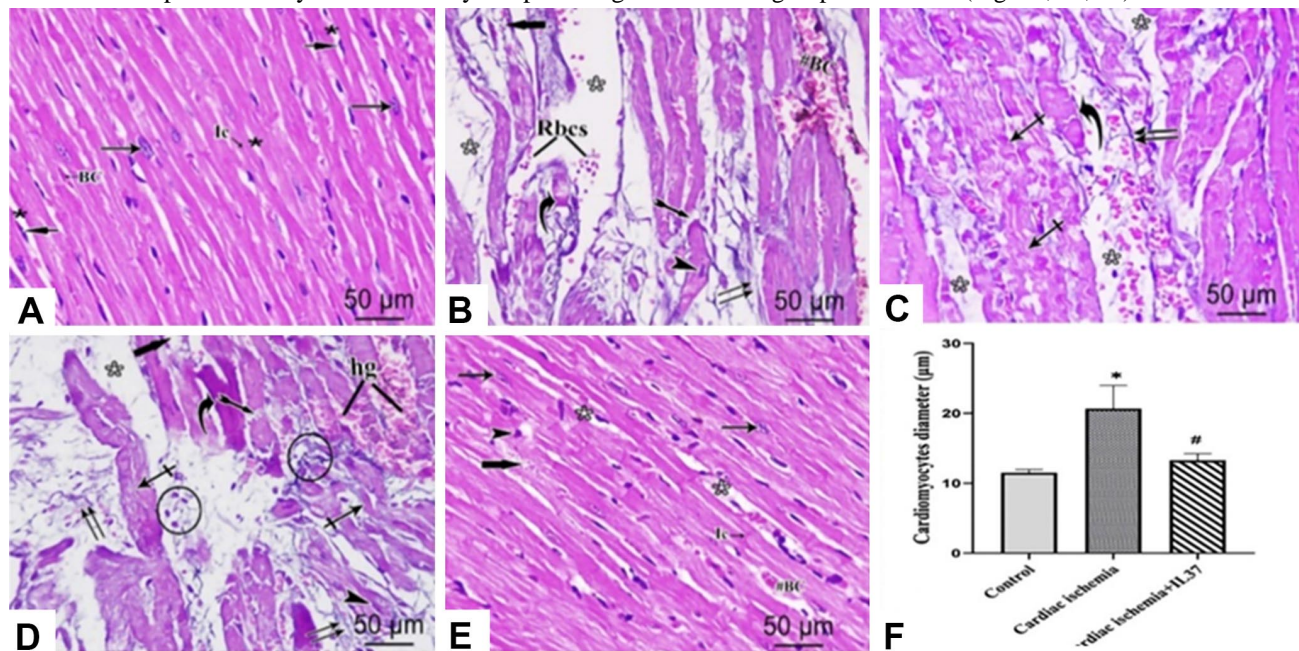


Fig. 4. Photomicrographs of sections of rat left ventricular myocardium from different experimental groups. (a): The control group shows parallel myocardial fibers with branching and anastomosing patterns, central oval vesicular nuclei (arrow), and visible intercalated discs (Ic). Fibroblasts (short arrow) with elongated dark nuclei and blood capillaries (BC) are seen in the interstitial space (black Asterix). (b): Cardiac ischemic group exhibits disorganized myocardial fibers with pyknotic nuclei (arrowhead) and the absence of the intercalated discs, widening the interstitial spaces (white Asterix). A mononuclear cellular infiltration (circle), red blood cells (RBCs), and prominent fibrous tissue (double arrow) are seen in the widened interstitial spaces. Congested blood capillaries (# BC), intensely eosinophilic (curved arrow) and fragmented (bifid arrow) myocardial fibers, and cytolysis (thick arrow) of the myocardial fibers are observed. (c): Cardiac ischemic group shows wavy (crossed arrow) and intensely eosinophilic (curved arrow) myocardial fibers, blood cells (RBCs), and prominent fibrous tissue (double arrow) in the widened interstitial spaces (white Asterix). (d): Cardiac ischemic group exhibits hemorrhage within the myocardial fibers, intensely eosinophilic (curved arrow), fragmented (bifid arrow), and wavy myocardial fibers (crossed arrow). The myocardial fibers' cytolysis (thick arrow) is seen with wide interstitial spaces (white Asterix). (e): Cardiac ischemic+IL37 group showing parallel myocardial fibers with branching and anastomosing pattern, central oval vesicular nuclei (arrow), and visible intercalated discs (Ic). Less widened interstitial spaces (white Asterix), some congested capillaries, and pyknotic nuclei are still seen. (f): A chart displays the cardiomyocytes diameters of the left ventricular wall among experimental groups. *, $p < 0.05$ compared with the control group; #, $p < 0.05$ compared with the cardiac ischemia group. Scale bar= 50 µm, x400.

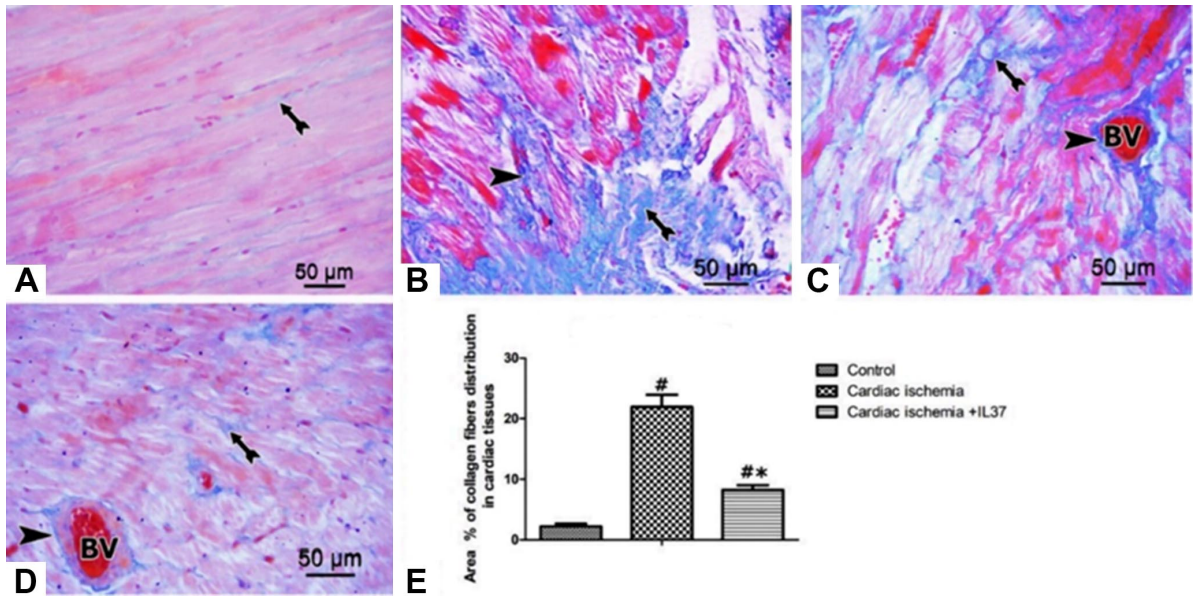


Fig. 5. Photomicrographs of Masson's trichrome stained sections; (a) control, (b, c) Cardiac ischemic groups; (d) Cardiac ischemic +IL37 group. (arrowhead) and (bifid arrow) demonstrates the collagen fibers distribution around the blood vessels (BV) and interstitial space, respectively. Scale bar= 50 μ m, x400. (e) A chart displays the Area % of blue staining of collagen fibers in the ventricular myocardium of different experimental groups. Data are presented as mean \pm SD (n = 8); #, significance versus control and *, significance versus the Cardiac ischemic group at P < 0.05.

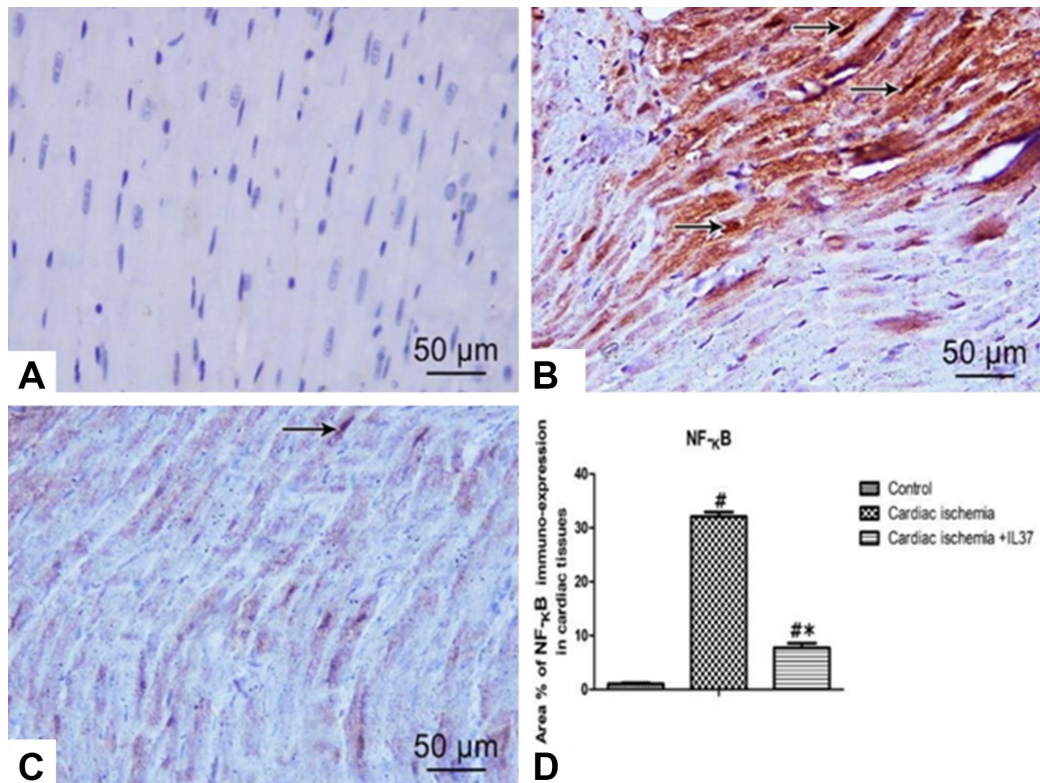


Fig. 6. Photomicrographs of NF- κ B immunostained sections showing the expression of NF- κ B; (a) Control group, (b) Cardiac ischemic group, (c) Cardiac ischemic +IL37 group. Positive staining is well-defined as brown-yellow staining (arrow). Scale bar= 50 μ m, x 400. (d) A chart displays the quantification and statistical analysis of the area % of the ventricular myocardium of different experimental groups. Data are presented as mean \pm SD (n = 8); #, significantly different from control *, significance versus the Cardiac ischemic group at P < 0.05.

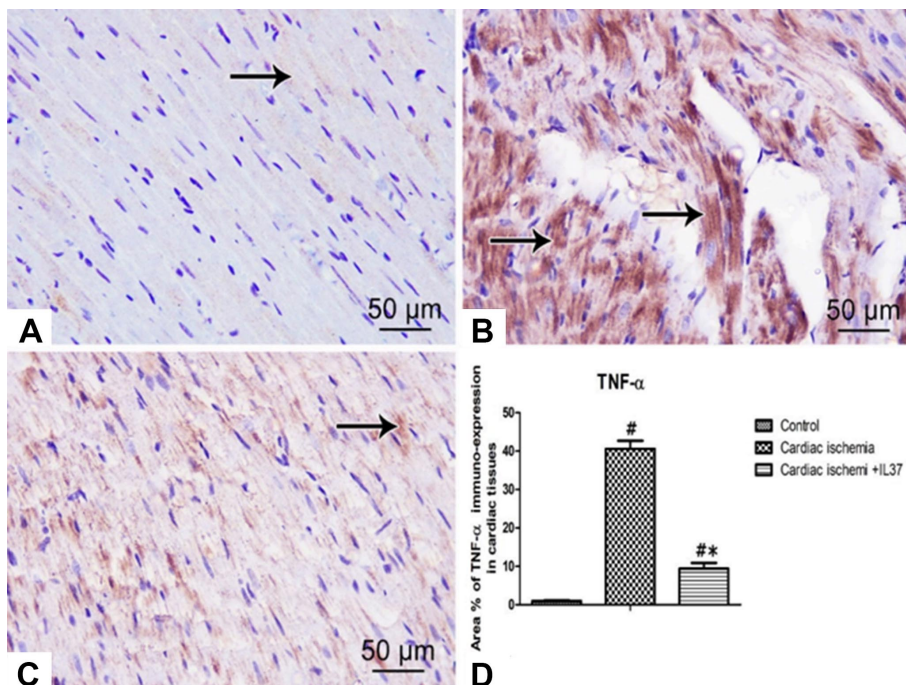


Fig. 7. Photomicrographs of TNF- α immunostained sections showing the expression of TNF- α ; (a) Control group, (b) Cardiac ischemic group, (c) Cardiac ischemic +IL37 group. Positive staining was well-defined as brown-yellow staining (arrow). Scale bar= 50 μ m, x 400. (d) A chart displays the quantification and statistical analysis of the area percent of TNF- α . Data are presented as mean \pm SD (n = 8); #, significantly different from control *, significance *versus* the Cardiac ischemic group at P < 0.05.

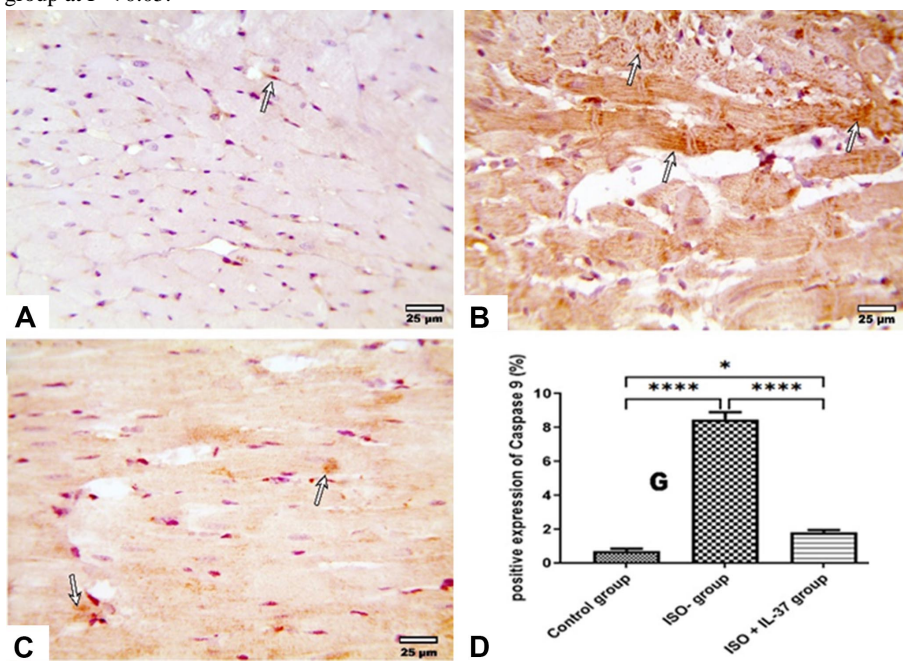


Fig. 8. Photomicrographs of Caspase-9 immunostained sections showing the expression of Caspase-9; (a) Control group, (b) Cardiac ischemic group, (c) Cardiac ischemic +IL37 group. Positive staining was well-defined as brown-yellow staining (arrow). Scale bar= 50 μ m, x 400. (d) A chart displays the quantification and statistical analysis of the area percent of caspase-9 in the ventricular myocardium of different experimental groups. Data are presented as mean \pm SD (n = 8); #, significantly different from control *, significantly different from the Cardiac ischemic group at P < 0.05.

DISCUSSION

The current research investigates the potential treatment function of exogenous IL-37 for the ISO-induced myocardial infarction rat model. The model of ISO-induced MI is characterized by less invasive techniques without complications of general anesthesia when compared with the occlusion of the coronary artery (Rayabarapu & Patel, 2014).

Our results revealed that IL-37 treatment ameliorated rat myocardial infarction, as demonstrated by restricted inflammatory responses, reduced oxidative stress, inhibited cardiomyocyte apoptosis, and improved cardiac function.

The serum LDH and CK- MB levels are sensitive indices for assessing myocardial infarction severity (Saeed & Ahmed, 2006). Our findings showed that the serum CK-MB and LDH activities of ISO-intoxicated rats were significantly increased due to their leakage from the area of cardiac necrosis induced by ISO (Manjula *et al.*, 1992). IL-37 treatment significantly lowered these marker enzymes compared with ISO-intoxicated animals establishing the cardioprotective role of IL-37 by conserving the myocardial membrane structural and functional integrity.

Moreover, as dyslipidemia contributes to MI, ISO was found to activate cAMP formation, enhancing lipid biosynthesis and developing hyperlipidemia (Ithayarasi & Devi, 1997). In the current study, it was found that rats treated with ISO had significantly higher levels of TC, LDL-C, and TG serum, which were dramatically reduced by treatment with IL-37 and improved HDL-C levels. These findings support the adjunct usage of IL-37 to improve dyslipidemia and consequently reduce the risk of MI. In accordance, it has been revealed that IL-37 has a protective effect against atherosclerosis involving the inhibition of Rho-kinase (ROCK) activity, which might be the mechanism preventing hyperlipidemia (Yang *et al.*, 2017). Rho-kinase activity is amplified in atherosclerosis, acting as an atherosclerotic burden marker suggesting a probable relationship between IL-37 and atherosclerosis (Shaoyuan *et al.*, 2015).

Serum concentrations of CRP, TNF- α , and IL-6 in rats (ISO-treated) increased significantly. However, IL-37 treatment dramatically reduced the elevated serum levels of CRP, TNF- α , and IL-6. Consequently, by lowering cardiac stress biomarkers and lowering the production of inflammatory cytokines, IL-37 has an anti-inflammatory

influence. In agreement with our findings, a study revealed that the transgenic expression of human IL-37 in a mouse macrophage line considerably inhibited the generation of the pro-inflammatory cytokines (Sharma *et al.*, 2008). Moreover, recombinant IL-37 inhibited pro-inflammatory cytokines limiting the inflammatory burden in inflammatory arthritis (Cavalli *et al.*, 2016), following acute lung injury (Moretti *et al.*, 2014), and obesity (Nold-Petry *et al.*, 2015). Furthermore, it suppressed the inflammatory response and elevated oxidative respiration, improving exercise tolerance (Cavalli *et al.*, 2017). IL-37 inhibited also the inflammasome bioactivity, IL-1 β , and IL-18 (Rudloff *et al.*, 2020).

The plasma level of IL-37 is significantly elevated with acute coronary syndrome (Rudloff *et al.*, 2020). Patients with raised baseline IL-37 levels at admission have poorer outcomes. Therefore, IL-37 may serve as a mortality-predictive biomarker in acute coronary syndrome (ACS) (Yang *et al.*, 2017). The higher IL-37 levels in ACS patients could be considered the compensatory response to a greater inflammatory reaction owing to its anti-inflammatory properties.

The generation of reactive oxygen species in MI can dramatically disrupt cardiac homeostasis, increasing the antioxidant system's demand (Singal *et al.*, 1982). The increase in myocardial MDA and NOx content in the current investigation, along with the decrease in GSH, GPx, and SOD levels, point to the development of oxidative stress in the ISO-treated rats. The decrease in the levels of cardiac MDA and NOx may be ascribed to IL-37's antioxidant response to the free radicals brought on by ISO's auto-oxidation. Administration of IL-37 significantly reduced this oxidative stress while maintaining cardiovascular function. Additionally, the effect of IL-37 dramatically reduced the ISO-induced myocardial apoptotic markers such as p53 and caspase-8 content. As a result, the improvement in exercise tolerance that follows IL-37 therapy can therefore be attributed to the antioxidant activity of IL-37, which results in a decrease in oxidative stress-related metabolic markers and an increase in the antioxidant glutathione, trying to delay muscle fatigue and improving muscle contraction (Cavalli *et al.*, 2017).

Treatment with IL-37 considerably reduced the hypertrophy observed in the ISO group as shown by the elevated heart weight index (HWI). Additionally, IL-37 was effective in alleviating ECG abnormalities brought on by ISO administration, including elevated HR, inverted T wave, prolonged QTc interval, and QRS duration (indicating ischemia and conduction abnormalities), and significantly depressed ST-segment amplitude (indicating

the progression of ischemia-induced MI). Moreover, treatment with IL-37 declined elevated systolic and diastolic blood pressure and heart rate induced by ISO administration. In agreement with our findings, many studies reported that IL-37 decreased the area of myocardial infarction, inhibited dendritic cell maturation, reversed cardiac remodeling, increased IL-10 expression alleviated myocardial injury induced by ischemia/reperfusion (Wu *et al.*, 2014; Zhu *et al.*, 2016).

As previously noted, densely stained myocardial fibers and widened interstitial spaces were observed in the cardiac ischemic (ISO) group, which are consistent with interstitial edema and the coagulative necrosis of the myocardial fibers seen by deep cytoplasmic eosinophilia as the first signs of myocardial infarction (Afroz *et al.*, 2016; Michaud *et al.*, 2020). Additionally, congested blood vessels, mononuclear cellular infiltration, and red blood cells were observed in the interstitial spaces. These findings are compatible with increased vascular permeation and neutrophil infiltration in the ischemic myocardium resulting in necrosis and muscle degeneration (Portran *et al.*, 2017).

According to earlier studies, the observed wavy myocardial fibers associated with interstitial edema are a characteristic finding in early and acute infarction. The increased hydrostatic pressure of the edematous interstitial space causes the myocardial fibers to be compressed and stretched, giving the impression of being wavy. Sections stained with Masson trichrome revealed significant deposition of collagen fibers in the interstitial space and around blood vessels in the cardiac ischemic (ISO) group, which aligns with fibroblast ingrowth within myocardium in late stages of infarction as an initial step to scarring following engulfment of dead cardiomyocytes by macrophage and neutrophil infiltration (Michaud *et al.*, 2020).

Contrary, the cardiac ischemia (ISO)+IL-37 group showed preserved histological structure of the myocardium with fewer collagen fibers deposition, which is consistent with reported beneficial effects of IL37 on cardiac pathology including its ability to alleviate cardiac infarction and hinders the expansion of atheromatous plaque (Yang *et al.*, 2019). Additionally, IL-37 was also found to have anti-fibrotic effects by modulating fibroblasts by inhibiting TGF- β 1 (Kim *et al.*, 2019).

TGF- β 1 plays a significant role in inducing heart fibrosis; it stimulates fibroblast proliferation, and through phosphorylation of its downstream mediators, Smad2/Smad3 collagen deposition and fibrosis are induced (Saadat *et al.*, 2021).

Marked immunoexpression of NF- κ B and TNF- α was observed in the ischemic group, which aligns with the reported stimulation of the NF- κ B pathway by ischemia and myocardial necrosis. NF- κ B can both shield cells from ischemia and act as a cytotoxic agent by extending inflammation. In addition, monocytes in the neutrophil infiltration secrete some cytokines like TNF- α , which acts through TNF receptor 1 (TNFR1), exaggerating remodeling and fibrosis (Michels da Silva *et al.*, 2019).

In the IL-37 treated group, there was moderate immunoexpression of NF- κ B and TNF- α , which is consistent with amelioration of the inflammatory status. IL37 is known to induce anti-inflammatory effects through the reduction of the pro-inflammatory cytokines production and upregulation of anti-inflammatory ones (Su & Tao, 2021). Moreover, IL37 regulates the activity of NF- κ B, which is essential for numerous macrophage functions (Yang *et al.*, 2019).

Notably, our data demonstrated that IL-37 protects against inflammatory load and oxidative stress in ISO-intoxicated rats. Further study on the efficacy and possible adverse effects of IL-37 in MI patients is highly recommended.

CONCLUSION

This study showed that IL-37 could greatly reduce the myocardial damage caused by oxidative stress and inflammation during ISO-induced myocardial infarction in rats. As a result, it can be utilized as an adjunct therapy to prevent myocardial infarction. This might be advantageous for avoiding the development of heart failure. To verify the mechanisms of action, additional research is needed. The limitations of this study, that it is a rat study, that future proof is needed in large animals and future studies should compare the effects of IL-37 on different types of myocardial infarction models to better understand its mechanisms and potential clinical applications.

AUTHORS' CONTRIBUTIONS. Project design, experimentation, data analysis, and manuscript writing were all handled by HAE. AEH: Designed the study, conducted experiments, evaluating information, ME and M. EL ran statistical calculations. Histopathological tests were carried out by AA, ME and OA, respectively. SH: performed experiments, examined data, ran statistical calculations, and gave the experimental plan a close look. Each author read the final draft of this text and approved of its contents.

HUMAN AND ANIMAL RIGHTS. In the study, no humans were involved. The Animal Research Ethical Committee at the Zagazig Scientific and Medical Research Center (ZSMRC), College of Medicine - Zagazig University, provided the guidelines for all animal research.

FUNDING. This research was funded by Princess Nourah bint Abdulrahman University Researchers Supporting Project number (PNURSP2023R171), Princess Nourah bint Abdulrahman University, Riyadh, Saudi Arabia and by AlMaarefa University, Riyadh, Saudi Arabia.

ELKATTAWY, H. A.; EL-SAYED HASSAN, A. E.; EBRAHIM, A. A.; ABDELWAHAB, O. A.; ELDESOQUI, M.; EL-SHERBINY, M.; EBRAHIM, H. A.; NOSSEIR, N. S.; VEERARAGHAVAN, V. P.; GHAZALA, M.; ATTIA, M. A.; HADHOUD, S. La interleucina-37 tiene un efecto cardioprotector prometedor sobre el infarto de miocardio inducido por isoproterenol. *Int. J. Morphol.*, 41(5):1427-1438, 2023.

RESUMEN: La principal causa de mortalidad y discapacidad a nivel mundial es el infarto de miocardio (IM). El isoproterenol (ISO), un agonista de los receptores adrenérgicos β , se ha utilizado para inducir necrosis miocárdica en ratas. Mientras que la interleucina-37 (IL-37) tiene propiedades antiinflamatorias y citoprotectoras. El estudio tuvo como objetivo investigar los posibles efectos protectores de la administración de IL-37 en la arquitectura cardíaca, el estrés oxidativo y los marcadores inflamatorios durante el infarto de miocardio inducido por ISO en ratas. En este estudio se utilizaron tres grupos de ratas macho adultas, el grupo control normal (n=8), el grupo con IM inducido por ISO (n=8) que recibió clorhidrato de isoproterenol (ISO) (100 mg/kg/día, SC, durante los primeros 2 días consecutivos) y el grupo tratado con IL-37 (ISO+IL-37) (n=8) que recibió IL-37 humana recombinante (40 μ g/kg/día, por vía intraperitoneal, durante 2 semanas durante y después de las inyecciones de ISO. Se monitorearon la frecuencia cardíaca (FC) y los cambios en el ECG. Se analizaron algunos marcadores de estrés oxidativo como la superóxido dismutasa (SOD), el óxido nítrico (NOx), el malondialdehído (MDA) y los niveles tisulares de glutatión (GSH) en el homogenizado de tejido. La interleucina-6 (IL-6), el factor de necrosis tumoral- α (TNF- α), la caspasa-8, la P53 y la proteína C reactiva (CRP) se encontraban entre los marcadores inflamatorios examinados. Se analizaron los niveles de creatinoquinasa (CK-MB) y lactato deshidrogenasa (LDH) para evaluar la lesión miocárdica; para el análisis histológico se seccionaron los tejidos, se fijaron en parafina y se tiñeron con hematoxilina y eosina (H&E), Tricromo de Masson e inmunohistoquímica contra NF- κ B, TNF- α y Caspasa-9. IL-37 mejoró los cambios de ECG, los marcadores de enzimas cardíacas y algunos marcadores inflamatorios de estrés oxidativo en el IM inducido por ISO. Además mejoró los cambios histopatológicos e inmunohistoquímicos en MI. En conclusión: la IL-37 podría ser una modalidad terapéutica prometedora en el infarto de miocardio.

PALABRAS CLAVE: IL-37; Isoproterenol; Miocardio; Infarto; Ratas.

REFERENCES

- Afroz, R.; Tanvir, E.; Karim, N.; Hossain, M.; Alam, N.; Gan, S. H. & Khalil, M. Sundarban honey confers protection against isoproterenol-induced myocardial infarction in Wistar rats. *Biomed Res. Int.*, 2016:6437641, 2016.
- Boraschi, D.; Lucchesi, D.; Hainzl, S.; Leitner, M.; Maier, E.; Mangelberger, D.; Oostingh, G. J.; Pfaller, T.; Pixner, C.; Posselt, G.; et al. IL-37: a new anti-inflammatory cytokine of the IL-1 family. *Eur. Cytokine Netw.*, 22(3):127-47, 2011.
- Busfield, S.; Comrack, C.; Yu, G.; Chickering, T.; Smutko, J.; Zhou, H.; Leiby, K.; Holmgren, L.; Gearing, D. & Pan, Y. Identification and gene organization of three novel members of the IL-1 family on human chromosome 2. *Genomics*, 66(2):213-6, 2000.
- Cavalli, G.; Justice, J. N.; Boyle, K. E.; D'Alessandro, A.; Eisenmesser, E. Z.; Herrera, J. J.; Hansen, K. C.; Nemkov, T.; Stienstra, R.; Garlanda, C.; et al. Interleukin 37 reverses the metabolic cost of inflammation, increases oxidative respiration, and improves exercise tolerance. *Proc. Natl. Acad. Sci. U. S. A.*, 114(9):2313-8, 2017.
- Cavalli, G.; Koenders, M.; Kalabokis, V.; Kim, J.; Tan, A. C.; Garlanda, C.; Mantovani, A.; Dagna, L.; Joosten, L. A. & Dinarello, C. A. Treating experimental arthritis with the innate immune inhibitor interleukin-37 reduces joint and systemic inflammation. *Rheumatology (Oxford)*, 55(12):2220-9, 2016.
- Cecilia, G.; Dinarello, C. & Mantovani, A. The interleukin-1 family: back to the future. *Immunity*, 39(6):1003-18, 2013.
- Dinarello, C. A.; Nold-Petry, C.; Nold, M.; Fujita, M.; Li, S.; Kim, S. & Bufler, P. Suppression of innate inflammation and immunity by interleukin-37. *Eur. J. Immunol.*, 46(5):1067-81, 2016.
- Goyal, B. & Mehta, A. Diabetic cardiomyopathy: pathophysiological mechanisms and cardiac dysfunction. *Hum. Exp. Toxicol.*, 32(6):571-90, 2013.
- Goyal, S. N.; Sharma, C.; Mahajan, U. B.; Patil, C. R.; Agrawal, Y. O.; Kumari, S.; Arya, D. S. & Ojha, S. Protective effects of cardamom in isoproterenol-induced myocardial infarction in rats. *Int. J. Mol. Sci.*, 16(11):27457-69, 2015.
- Hori, M. & Nishida, K. Oxidative stress and left ventricular remodeling after myocardial infarction. *Cardiovasc. Res.*, 81(3):457-64, 2009.
- Ithayarasi, A. P. & Devi, C. Effect of alpha-tocopherol on lipid peroxidation in isoproterenol induced myocardial infarction in rats. *J. Physiol. Pharmacol.*, 41(4):369-76, 1997.
- Ji, Q.; Zeng, Q.; Huang, Y.; Shi, Y.; Lin, Y.; Lu, Z.; Meng, K.; Wu, B.; Yu, K.; Chai, M.; et al. Elevated plasma IL-37, IL-18, and IL-18BP concentrations in patients with acute coronary syndrome. *Mediators Inflamm.*, 2014:165742, 2014.
- Kain, V.; Prabhu, S. D. & Halade, G. V. Inflammation revisited: inflammation versus resolution of inflammation following myocardial infarction. *Basic Res. Cardiol.*, 109(6):444, 2014.
- Kangussu, L. M.; Melo-Braga, M. N.; De Souza Lima, B. S.; Santos, R. A.; De Andrade, H. M. & Campagnole-Santos, M. J. Angiotensin-(1-7) central mechanisms after ICV infusion in hypertensive transgenic (mRen2) 27 rats. *Front. Neurosci.*, 15:624249, 2021.
- Kim, M. S.; Baek, A. R.; Lee, J. H.; Jang, A. S.; Kim, D. J.; Chin, S. S. & Park, S. W. IL-37 attenuates lung fibrosis by inducing autophagy and regulating TGF- β 1 production in mice. *J. Immunol.*, 203(8):2265-2275, 2019.
- Kopeček, J. A.; Carson, A. R.; Mctiernan, C. F.; Chen, X.; Klein, E. C. & Villanueva, F. S. Cardiac gene expression knockdown using small inhibitory RNA-loaded microbubbles and ultrasound. *PLoS One*, 11(7):e0159751, 2016.
- Liu, J.; Wang, H. & Li, J. Inflammation and inflammatory cells in myocardial infarction and reperfusion injury: a double-edged sword. *Clin. Med. Insights Cardiol.*, 10:79-84, 2016.

- Manjula, T.; Geetha, A.; Ramesh, T. & Devi, C. S. Reversal of changes of myocardial lipids by chronic administration of aspirin in isoproterenol-induced myocardial damage in rats. *J. Physiol. Pharmacol.*, 36(1):47-50, 1992.
- McNamee, E. N.; Masterson, J. C.; Jedlicka, P.; McManus, M.; Grenz, A.; Collins, C. B.; Nold, M. F.; Nold-Petry, C.; Bufler, P.; Dinarello, C. A.; *et al.* Interleukin 37 expression protects mice from colitis. *Proc. Natl. Acad. Sci. U. S. A.*, 108(40):16711-6, 2011.
- Michaud, K.; Basso, C.; d'Amati, G.; Giordano, C.; Kholová, I.; Preston, S. D.; Rizzo, S.; Sabatasso, S.; Sheppard, M. N.; Vink, A.; *et al.* Diagnosis of myocardial infarction at autopsy: AECVP reappraisal in the light of the current clinical classification. *Virchows Arch.*, 476(2):179-94, 2020.
- Michels da Silva, D.; Langer, H. & Graf, T. Inflammatory and molecular pathways in heart failure—ischemia, HFpEF and transthyretin cardiac amyloidosis. *Int. J. Mol. Sci.*, 20(9):2322, 2019.
- Moretti, S.; Bozza, S.; Oikonomou, V.; Renga, G.; Casagrande, A.; Iannitti, R. G.; Puccetti, M.; Garlanda, C.; Kim, S.; Li, S.; *et al.* IL-37 inhibits inflammasome activation and disease severity in murine aspergillosis. *PLoS Pathog.*, 10(11):e1004462, 2014.
- Nold-Petry, C. A.; Lo, C. Y.; Rudloff, I.; Elgass, K. D.; Li, S.; Gantier, M. P.; Lotz-Havla, A. S.; Gersting, S. W.; Cho, S. X.; Lao, J. C.; *et al.* IL-37 requires the receptors IL-18R α and IL-1R8 (SIGIRR) to carry out its multifaceted anti-inflammatory program upon innate signal transduction. *Nat. Immunol.*, 16(4):354-65, 2015.
- Nold, M. F.; Nold-Petry, C. A.; Zepp, J. A.; Palmer, B. E.; Bufler, P. & Dinarello, C. A. IL-37 is a fundamental inhibitor of innate immunity. *Nat. Immunol.*, 11:1014-22, 2010.
- Patel, B. M. & Mehta, A. A. Aldosterone and angiotensin: Role in diabetes and cardiovascular diseases. *Eur. J. Pharmacol.*, 697(1-3):1-12, 2012
- Patel, B. M. & Mehta, A. A. Choice of anti-hypertensive agents in diabetic subjects. *Diab. Vasc. Dis. Res.*, 10(5):385-96, 2013.
- Portran, D.; Schaedel, L.; Xu, Z.; Théry, M. & Nachury, M. V. Tubulin acetylation protects long-lived microtubules against mechanical ageing. *Nat. Cell. Biol.*, 19(4):391-8, 2017.
- Qian, X.; Zhu, M.; Qian, W. & Song, J. Vitamin D attenuates myocardial ischemia–reperfusion injury by inhibiting inflammation via suppressing the RhoA/ROCK/NF- κ B pathway. *Biotechnol. Appl. Biochem.*, 66(5):850-7, 2019.
- Rayabarapu, N. & Patel, B. M. Beneficial role of tamoxifen in isoproterenol-induced myocardial infarction. *Can. J. Physiol. Pharmacol.*, 92(10):849-57, 2014.
- Rudloff, I.; Ung, H. K.; Dowling, J. K.; Mansell, A.; D'Andrea, L.; Ellisdon, A. M.; Whisstock, J. C.; Berger, P. J.; Nold-Petry, C. A. & Nold, M. F. Parsing the IL-37-mediated suppression of inflammasome function. *Cells*, 9(1):178, 2020.
- Saadat, S.; Noureddini, M.; Mahjoubin-Tehran, M.; Nazemi, S.; Shojaie, L.; Aschner, M.; Maleki, B.; Abbasi-Kolli, M.; Rajabi Moghadam, H. & Alani, B. Pivotal role of TGF- β /Smad signaling in cardiac fibrosis: non-coding RNAs as effectual players. *Front. Cardiovasc. Med.*, 7:588347, 2021.
- Saeed, S. A. & Ahmed, S. Role of cyclooxygenase-2 in myocardial infarction and ischaemia. *J. Coll. Physicians Surg. Pak.*, 16(5):324-8, 2006.
- Shaoyuan, C.; Ming, D.; Yulang, H. & Hongcheng, F. Increased IL-37 in Atherosclerotic Disease could be Suppressed by Atorvastatin Therapy. *Scand. J. Immunol.*, 2(4):328-36, 2015.
- Sharma, S.; Kulk, N.; Nold, M. F.; Gräf, R.; Kim, S. H.; Reinhardt, D.; Dinarello, C. A. & Bufler, P. The IL-1 family member 7b translocates to the nucleus and down-regulates proinflammatory cytokines. *J. Immunol.*, 180(8):5477-82, 2008.
- Singal, P.; Kapur, N.; Dhillon, K.; Beamish, R. & Dhalla, N. Role of free radicals in catecholamine-induced cardiomyopathy. *Can. J. Physiol. Pharmacol.*, 60(11):1390-7, 1982.
- Su, Z. & Tao, X. Current understanding of IL-37 in human health and disease. *Front. Immunol.*, 12:696605, 2021.
- Teng, X.; Hu, Z.; Wei, X.; Wang, Z.; Guan, T.; Liu, N.; Liu, X.; Ye, N.; Deng, G.; Luo, C.; *et al.* IL-37 ameliorates the inflammatory process in psoriasis by suppressing proinflammatory cytokine production. *J. Immunol.*, 192(4):1815-23, 2014.
- Wu, B.; Meng, K.; Ji, Q.; Cheng, M.; Yu, K.; Zhao, X.; Tony, H.; Liu, Y.; Zhou, Y.; Chang, C.; *et al.* Interleukin-37 ameliorates myocardial ischaemia/reperfusion injury in mice. *Clin. Exp. Immunol.*, 176(3):438-51, 2014.
- Yang, T.; Fang, F.; Chen, Y.; Ma, J.; Xiao, Z.; Zou, S.; Zheng, N.; Yan, D.; Liao, S.; Chen, S. J. O.; *et al.* Elevated plasma interleukin-37 playing an important role in acute coronary syndrome through suppression of ROCK activation. *Oncotarget*, 8(6):9686-95, 2017.
- Yang, Z.; Kang, L.; Wang, Y.; Xiang, J.; Wu, Q.; Xu, C.; Zhou, Y.; Chen, S.; Fang, H. & Liu, J. Role of IL-37 in cardiovascular disease inflammation. *Can. J. Cardiol.*, 35(7):923-30, 2019.
- Zhu, R.; Sun, H.; Yu, K.; Zhong, Y.; Shi, H.; Wei, Y.; Su, X.; Xu, W.; Luo, Q.; Zhang, F.; *et al.* Interleukin-37 and dendritic cells treated with interleukin-37 plus troponin I ameliorate cardiac remodeling after myocardial infarction. *J. Am. Heart Assoc.*, 5(12):e004406, 2016.
- Zhuang, X.; Wu, B.; Li, J.; Shi, H.; Jin, B. & Luo, X. The emerging role of interleukin-37 in cardiovascular diseases. *Immun. Inflamm. Dis.*, 5(3):373-9, 2017.

Corresponding author:

Dr. Hasnaa A. Ebrahim

Department of Basic Medical Sciences

College of Medicine

Princess Nourah Bint Abdulrahman University

Riyadh

SAUDI ARABIA

E-mail: haebrahim@pnu.edu.sa