

Neuroprotective Potential of a Novel Soluble Guanylate Cyclase Stimulator the Riociguat Alone or in a Combination Manner with Resveratrol in Experimental Stroke Model in Rats

Potencial Neuroprotector del Novedoso Estimulador de Guanilato Ciclasa Soluble, el Riociguat solo o en Combinación con Resveratrol en un Modelo Experimental de Ataque Cerebrovascular en Ratas

Baris Aslanoglu¹; Seval Kaya²; Sezer Onur Gunara¹; Burak Atlas¹; Ugur Seker³; Baris Can Guzel⁴ & Yahya Turan¹

ASLANOGLU, B.; KAYA, S.; GUNARA, S.O.; ATLAS, B.; SEKER, U.; GUZEL, B.C. & TURAN, Y. Neuroprotective potential of the novel soluble guanylate cyclase stimulator the Riociguat alone or in a combination manner with resveratrol in experimental stroke model in rats. *Int. J. Morphol.*, 42(4):984-990, 2024.

SUMMARY: In this study we aimed to examine the effect of novel vasodilatory drug Riociguat co-administration along resveratrol to recover neurodegeneration in experimental stroke injury. For that purpose, thirty-five adult female rats were divided into five groups (Control, MCAO, MCAO + R, MCAO + BAY, MCAO + C) of seven animals in each. Animals in Control group did not expose to any application during the experiment and sacrificed at the end of the study. Rats in the rest groups exposed to middle cerebral artery occlusion (MCAO) induced ischemic stroke. MCAO + R group received 30 mg/kg resveratrol, and MCAO + BAY group received 10 mg/kg Riociguat. The MCAO + C group received both drugs simultaneously. The drugs were administered just before the reperfusion, and the additional doses were administered 24h, and 48h hours of reperfusion. All animals in this study were sacrificed at the 72nd hour of experiment. Total brains were received for analysis. Results of this experiment indicated that MCAO led to severe injury in cerebral structure. Bax, IL-6 and IL-1 β tissue levels were up-regulated, but anti-apoptotic Bcl-2 immunoexpression was suppressed ($p < 0.05$). In resveratrol and Riociguat treated animals, the neurodegenerations and apoptosis and inflammation associated protein expressions were improved compared to MCAO group, but the most success was obtained in combined treatment exposed animals in MCAO + C group. This study indicated that the novel soluble guanylate cyclase stimulator Riociguat is not only a potent neuroprotective drug in MCAO induced stroke, but also synergistic administration of Riociguat along with resveratrol have potential to increase the neuroprotective effect of resveratrol in experimental cerebral stroke exposed rats.

KEY WORDS: Stroke; Resveratrol; Riociguat; Apoptosis; Inflammation.

INTRODUCTION

Ischemia-Reperfusion (I/R) induced stroke may lead to permanent disability in adults, and it was reported that stroke is 3rd cause of death globally (Johnston *et al.*, 2009). Ischemic condition in cerebral environment leads decreased blood flow to the brain which resulted with hypoxia thus pathological alterations such as totally or partially dysfunction of central nervous system (CNS) (Puig *et al.*, 2018). When reperfusion occurs following ischemia, the oxygen reaches the ischemic tissues, causing an increase in free oxygen radicals and inducing paradox secondary damage (Arpa & Ozturk, 2022). Until today both experimental and clinical observations indicated that the underlying reasons of CNS dysfunction following brain stroke are related with numerous

molecular signaling such as oxidative stress, apoptosis, inflammation (Puig *et al.*, 2018). More detailed examinations indicated that, even though, reperfusion is provided to the brain with various interventions, the accumulated reactive oxygen species increase the severity of the cerebral injury due to spread of reactive oxygen substances (ROS) and generation of new oxidant molecules due to pathological outcomes such as apoptosis, necrosis, and inflammation (Ashafaq *et al.*, 2021). It is also believed that following reperfusion, cellular protein homeostasis is disrupted, and the irregular protein expression increase neuronal degeneration and increase the severity of the CNS injury, a process called I/R injury (White *et al.*, 2000). The pivotal process in ROS

¹ Department of Neurosurgery, Faculty of Medicine, Dicle University, Diyarbakir, Turkey.

² Department of Histology and Embryology, Faculty of Medicine, Istanbul Aydin University, Istanbul, Turkey.

³ Department of Histology and Embryology, Faculty of Medicine, Mardin Artuklu University, Mardin, Turkey.

⁴ Department of Veterinary Anatomy, Faculty of Veterinary Medicine, Siirt University, Siirt, Turkey.

FUNDED. Dicle University Scientific Research and Project Coordinatorship with grant no: TIP.21.013.

generation and I/R injury is associated with lipid peroxidation. Lipid peroxidation end units and ROS related substances can be observed until the 72nd hour of I/R injury (Bromont *et al.*, 1989). Until today, numerous studies were performed to understand the underlying exactmolecular signaling of cerebral I/R injury and these studies aimed to explore any treatment protocols to protect neurons and glia cells to improve the functionality of CNS. Current literature indicates that treatment strategies such as hyperbaric oxygen, targeting ferroptosis, miRNA applications, and antioxidant supplementations providing promising results to recover organ functions (Li *et al.*, 2008; Pan *et al.*, 2022). In addition, cheap, easily accessible, and wide spectral properties of the antioxidants are probably the reason that researchers are aiming to find the most optimum modality. One of the mostly examined antioxidant drug in cerebral stroke is Resveratrol. This phytochemical drug is reported to bear antioxidant, anti-inflammatory and antiapoptotic properties (Cui *et al.*, 2022). However, due to multifunctionality, the underlying neuroprotective mechanism of this drug has not been clearly explored yet. In addition, previous examinations indicated that the drugs with vasodilatory properties have capability to recover brain from harmful effects of cerebral I/R injury and stroke (Melani *et al.*, 2010). However, studies based on this modality are very limited. For that reason, in this study we aimed to examine if the novel soluble guanylate cyclase (sGC) stimulator drug, Riociguat, has the potential to improve neuroprotection in cerebral stroke in alone or combined manner with resveratrol in rats.

MATERIAL AND METHOD

Study design. This study was performed with the approval of Local Experimental Animal Ethics Committee of Dicle University (2020/39). The obtained mature 250-300 g weighing female rats were divided into 5 groups (control, MCAO, MCAO + R, MCAO + BAY, MCAO + C) of 7 Rats in each. Animals in Control group did not receive any application or treatment during the study. Rats in the rest of the groups were exposed to middle cerebral artery occlusion at the right hemisphere of the animals for induction of cerebral ischemia as described previously (Yang *et al.*, 2022). The blood flow to the brain ceased for 2 hours. Animals in MCAO + R received 30 mg/kg resveratrol (Carl Roth, Karlsruhe, DE), and the animals in MCAO + BAY received 10 mg/kg Riociguat (Key Organics, Camelford, UK) just before reperfusion. The rats in MCAO + C group received both 30 mg/kg resveratrol and 10 mg/kg Riociguat. The animals were exposed to two additional doses of the drugs 24th, and 48th hours of reperfusion. All animals were sacrificed with exsanguination just after the administration of the last drug application. Brain samples were received to use for biochemical and histological examinations.

Measurement of tissue IL-1 β and IL-6 levels. Obtained brain tissue samples were homogenized in PBS (pH 7.4) and the homogenates were centrifuged for 20 min at 3000 rpm at 4 °C. The supernatants were collected and stored -20 °C for farther analyzes. Before determination of tissue IL-1 β and IL-6 levels, total protein in tissue biopsies were measured with a commercial BCA kit (SMART BCA Protein Assay Kit, Intron Biotechnology). Protocols for BCA were performed with manufacturer's directions and tissue homogenates were 1:4 diluted before ELSA. IL-1 β and IL-6 were obtained with ready to use commercial kits (Sunredbio, Shanghai, China). All steps for the ELISA were performed according to manufacturer's directions, and measurement performed with a microplate reader and optical density (OD) were obtained under 450 nm wavelength. Tissue levels of interest proteins were reached through considering OD of standards and unknown samples. Obtained data sets were evaluated statistically and results are expressed as pg/mg.

Tissue processing for microscopic examinations. The obtained tissue samples were exposed to routine histopathological tissue processing protocol as described previously (Seker *et al.*, 2021). For that purpose, right hemisphere of the animals were removed and following excision of biopsy samples for biochemical analyzes, whole right hemisphere were fixed in 10 % formalin. Tissue samples were washed under tap water and dehydrated through increasing alcohol series and embedded into paraffin blocks. Five μ m thick sections were received with a rotary microtome for histological staining protocols. Obtained sections from each brain samples were stained with H&E for routine histopathological observations. Remaining sections were used for immunohistochemistry of Bax and Bcl-2.

Immunohistochemistry protocol. Pro-apoptotic Bax and anti-apoptotic Bcl-2 expression were examined immunohistochemically. For that purpose, obtained sections were deparaffinized, rehydrated and washed in PBS as described in a previous study (Seker *et al.*, 2021). Citrate buffer (Ph 6.0) was used for antigen retrieval and samples were heated in buffer until obtaining sub-boiling temperature. The sections were washed with PBS and blocking solution was used for inhibition of non- specific binding. The antibodies of Bax (Santa Cruz Biotechnology, Dallas, Texas, USA. cat no: sc-7480) ve Bcl-2 (Santa Cruz Biotechnology, Dallas, Texas, USA. cat no: sc-7382) were 1:100 diluted and dropped on samples. Hydrophobic encircled sections were incubated at +4 °C overnight and washed in PBS. Secondary antibody and enzyme were administered to the sections and chromogenic reaction was developed with a ready to use kit DAB (Thermo Scientific, Waltham, MA, USA), counterstained with hematoxylin and mounted with entellan. Prepared

immunohistochemistry sections were evaluated under a light microscope and micrographs were captured.

Quantification of the immunodensity. Obtaining semi-quantitative data from immunohistochemistry samples were performed in Image J software. For that purpose, tissue sections from each animal were divided into equally sized areas under highest magnification. Randomly selected 3 regions from each animal and totally 21 area from each group were used for immunohistochemistry quantification. Results were obtained with comparing the brown intensity to total tissue area automatically. Obtained measurements were converted into ratio and results are expressed as percentage.

Statistical analysis. Obtained immunohistochemistry intensity and ELISA Assay results were analyzed statistically. For that purpose, immunopositivity ratios were analyzed with non-parametric Kruskal Wallis test. Multiple comparisons among the groups were considered with post-hoc Tamhane's test and results were shown as mean \pm SD, and $P < 0.05$ was considered as statistically significant.

RESULTS

ELISA results. Tissue levels of IL-1 β and IL-6 are shown in Table I. When we consider IL-1 β , the lowest tissue level was obtained in control group, but the tissue level of IL-1 β was significantly higher in MCAO group compared to control group ($p < 0.01$). Our analysis indicated that IL-1 β level in MCAO group was significantly higher than MCAO + R ($p < 0.01$) and MCAO + BAY ($p < 0.05$) groups, but the levels between MCAO + R and MCAO + BAY groups were

similar ($p > 0.05$). When IL-1 β level in combined treated animals in MCAO + C group were evaluated, IL-1 β result of this group was similar ($p < 0.01$) to Control, MCAO + R and MCAO + BAY groups, and results of this group was significantly different ($p < 0.01$) than MCAO group. When tissue levels of IL-6 were evaluated among the groups, the lowest tissue inflammatory cytokine level was obtained in Control group and results of this group was similar ($p > 0.05$) to MCAO + R, MCAO + BAY, and MCAO + C groups. When tissue IL-6 was evaluated in MCAO group, there were significantly increase ($p < 0.05$) compared to Control, MCAO + R, and MCAO + C groups, but results in this group was similar ($p > 0.05$) to MCAO + BAY group. Moreover, the results of MCAO + BAY group was similar ($p > 0.05$) to MCAO + R, and MCAO + C groups.

Histopathologic results. Our observations indicated that cerebral stroke led to severe morphological injury in cerebral structure compared to control group. We observed wide focal hemorrhagic areas (Fig. 1). Neurons and glial cell pyknosis

Table I. Statistical analysis results of immunopositivity of Bax and Bcl-2.

| | Bax Immunodensity (%) | Bcl-2 Immunodensity (%) |
|-----------|----------------------------------|-------------------------------|
| Control | 15.68 \pm 3.89 ^a | 11.97 \pm 4.20 ^b |
| MCAO | 41.25 \pm 12.92 ^d | 5.39 \pm 1.80 ^a |
| MCAO+ R | 25.08 \pm 10.46 ^{b,c} | 9.37 \pm 2.67 ^b |
| MCAO+ BAY | 26.86 \pm 9.12 ^c | 9.67 \pm 3.30 ^b |
| MCAO+ C | 17.79 \pm 7.91 ^{b,a} | 9.86 \pm 2.62 ^b |

Different superscripts on the results between every group at the same column indicate statistical significance. ^{a,b} $P < 0.01$, ^{a,c} $P < 0.01$, ^{a,d} $P < 0.01$, ^{b,c} $P < 0.05$, ^{b,d} $P < 0.01$.

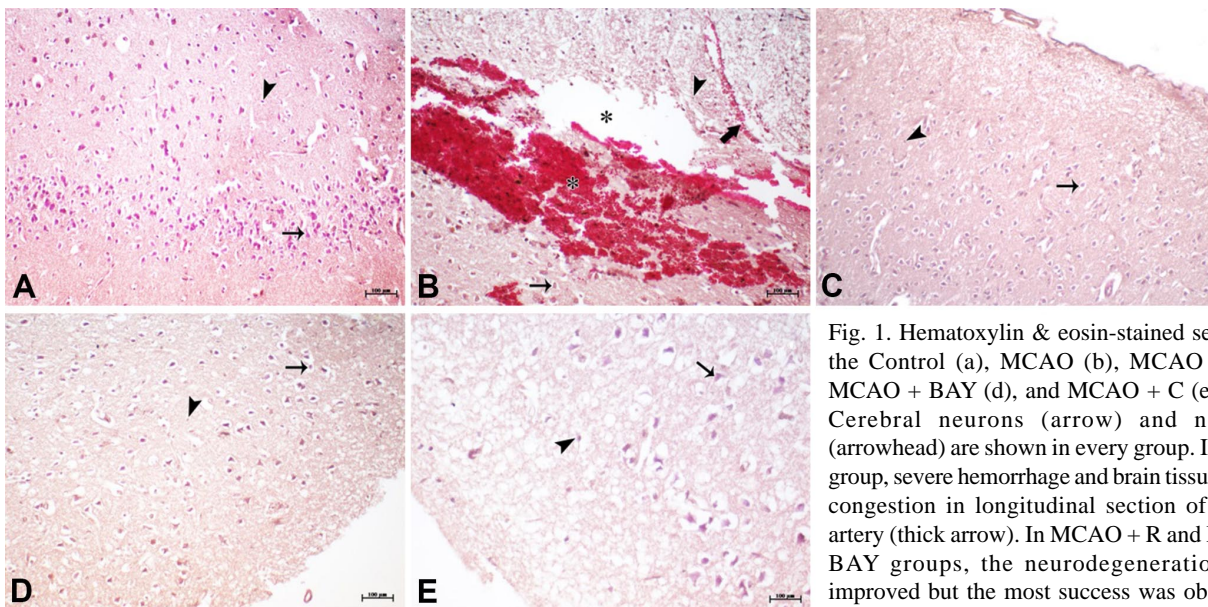


Fig. 1. Hematoxylin & eosin-stained sections of the Control (a), MCAO (b), MCAO + R (c), MCAO + BAY (d), and MCAO + C (e) groups. Cerebral neurons (arrow) and neuroglia (arrowhead) are shown in every group. In MCAO group, severe hemorrhage and brain tissue loss (*), congestion in longitudinal section of cerebral artery (thick arrow). In MCAO + R and MCAO + BAY groups, the neurodegenerations were improved but the most success was observed in co-treated MCAO + C group. Staining: Hematoxylin and eosin. Bar: 100 μ m.

were widespread. Cerebral vascular congestion and both perivascular and perineural cavities were enlarged and some of the enlarged cavities were filled with edema. Accumulation of edema and tissue loss in this group was obviously visible. In resveratrol group, morphological pathology was alleviated. Besides of the pyknotic neural cells, most of the neurons and glia cells were regular, in this group hemorrhagic parts almost disappeared and vascular structure were closer to control group except the existence of perivascular and perineural expanded cavity and accumulated edema reduced. Although some vessels were observed with congestion, most of the vascular structures were more similar to the control group compared to MCAO group. When we evaluated Riociguat group, it was possible to observe widespread pyknotic nuclear neurons and neuroglia. However, there were normal structured neurons and glial cells were visible as well. In this group, focal hemorrhage was disappeared, and vascular congestion down regulated. Tissue morphology and cellular structure in this group was partially closer to control group instead of MCAO group. When we consider MCAO + C group, morphology of cerebral sections was similar to the control group. Neuronal and glial cells were regular and cerebral hemorrhage, vascular congestion, perineural and perivascular edema and cavity were similar to the control group compared to MCAO group.

Immunohistochemistry results. Statistical analyses results of immunodensity are expressed in Table II. Our immunohistochemical analyses indicated that Control

group's immunodensity was the lowest for Bax and highest for Bcl-2 immunodensity. Our analysis indicated that Bax immunodensity was highest in MCAO group and result of this group significantly different ($p < 0.01$) than Control, MCAO + R, MCAO + BAY and MCAO + C groups. Bax immunodensity in MCAO + R and MCAO + BAY groups were similar ($p > 0.05$) to each other but significantly different ($p < 0.01$) than Control and MCAO + C groups. Immunodensity of Bax in MCAO + C group was similar ($p > 0.05$) to Control group. When we consider Bcl-2 immunodensity the lowest immunodensity was observed in MCAO group and result of this group was significantly different ($p < 0.01$) than the other groups. However, Bcl-2 immunodensity level in Control, MCAO + R, MCAO + BAY and MCAO + C groups were similar and there were not statistically different ($p > 0.05$) among these groups. The representative immunohistochemistry micrographs of Bax and Bcl-2 are shown in Figures 2 and 3, respectively.

Table II. Statistical analysis results of tissue IL-1 β and IL-6 levels.

| | IL-1 β (pg/mg) | IL-6 (pg/mg) |
|-----------|------------------------------------|-----------------------------------|
| Control | 1764,00 \pm 232,43 ^a | 102,96 \pm 16,51 ^a |
| MCAO | 6631,86 \pm 1709,24 ^c | 373,66 \pm 160,52 ^b |
| MCAO+ R | 2583,57 \pm 900,93 ^{ab} | 113,05 \pm 23,52 ^a |
| MCAO+ BAY | 3451,14 \pm 1052,35 ^b | 202,11 \pm 127,06 ^{ab} |
| MCAO+ C | 1822,00 \pm 533,86 ^{ab} | 108,67 \pm 26,35 ^a |

Different superscripts on the results between every group at the same column indicate statistical significance. ^{a-b} $P < 0.05$, ^{a-c} $P < 0.01$, ^{b-c} $P < 0.05$

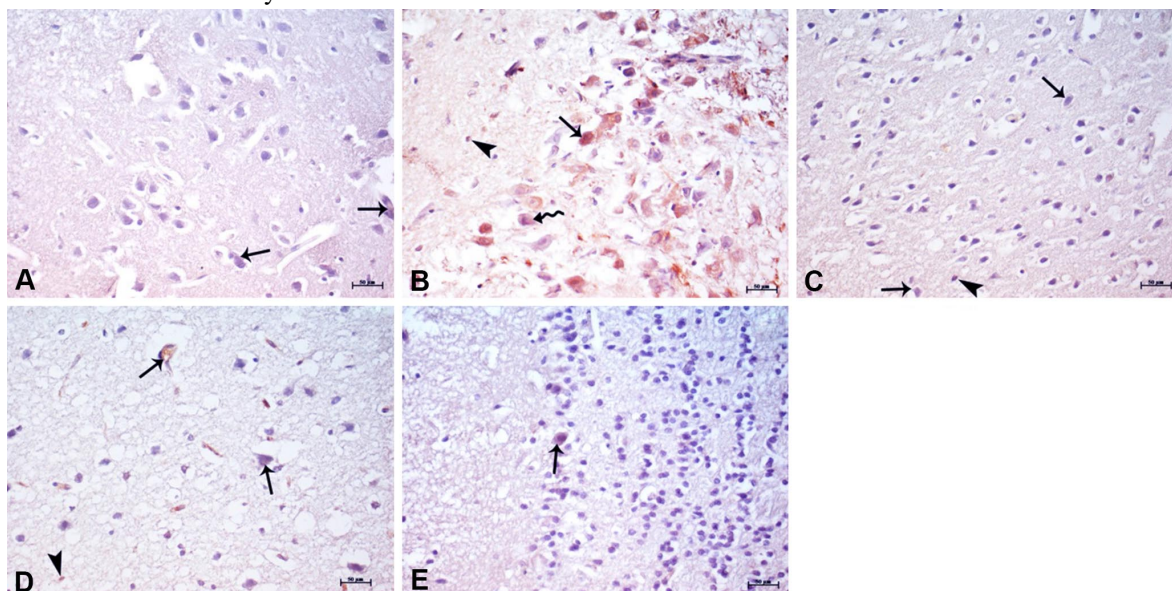


Fig. 2. Representative Bax immunohistochemistry micrographs of the Control (a), MCAO (b), MCAO + R (c), MCAO + BAY (d), MCAO + C (e) groups, and graphical demonstration of immunodensity statistical analysis. Dense Bax immunopositivity in cerebral neurons (arrow), mild immunopositivity in neuronal soma (curved arrow) and immunopositivity in neuroglia (arrow head). a; Control, b; MCA, c; MCA+Resveratrol, d; MCA+Riociguat, e; MCA+Resveratrol+Riociguat, f; Graphical demonstration of the statistical analyses. Staining: Bax immunohistochemistry, Bar: 50 μ m.

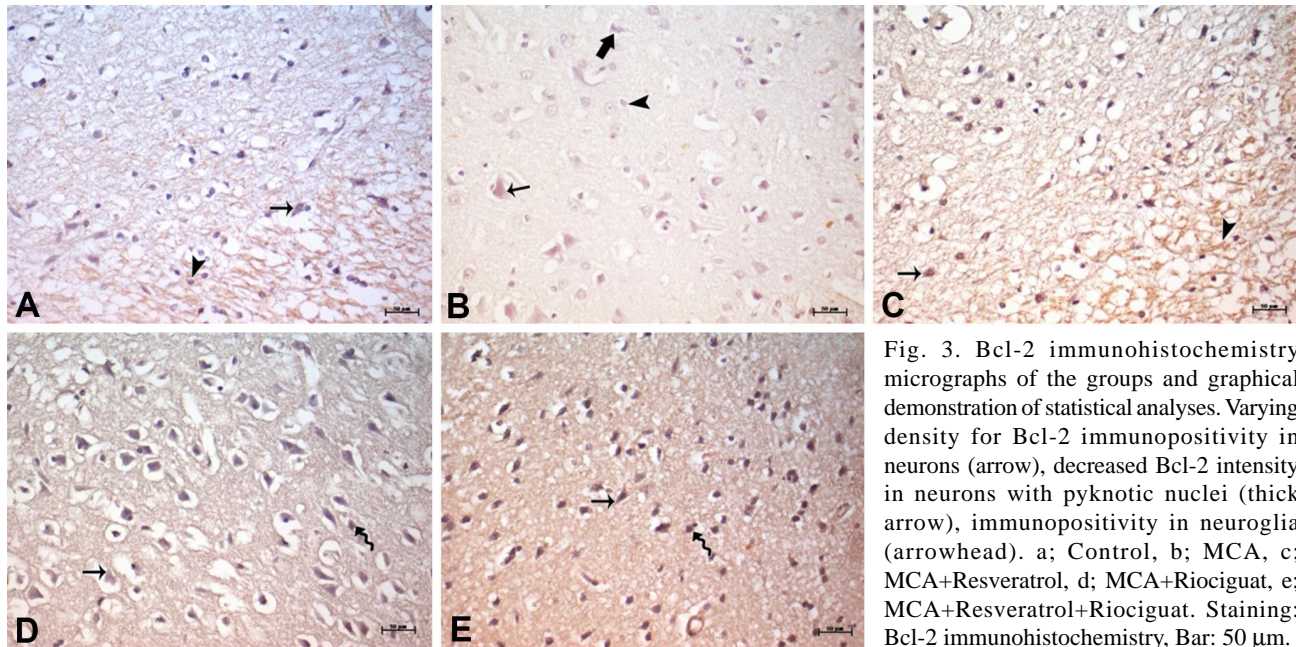


Fig. 3. Bcl-2 immunohistochemistry micrographs of the groups and graphical demonstration of statistical analyses. Varying density for Bcl-2 immunopositivity in neurons (arrow), decreased Bcl-2 intensity in neurons with pyknotic nuclei (thick arrow), immunopositivity in neuroglia (arrowhead). a; Control, b; MCA, c; MCA+Resveratrol, d; MCA+Riociguat, e; MCA+Resveratrol+Riociguat. Staining: Bcl-2 immunohistochemistry, Bar: 50 μ m.

DISCUSSION

Results of this study indicated that combined treatment of resveratrol and Riociguat significantly protect cerebral tissue and cellular structure of the cerebrum. When we reviewed the literature it was possible to conclude that numerous studies have been performed to explore potent modalities and drug administrations to improve neurodegeneration in cerebral stroke. Moreover, resveratrol-based studies covered much of the current literature, but the literature on Riociguat is very limited. It was also indicated that vasodilatory interventions through cGMP which is activated through nitric oxide pathway, is a reliable strategy in stroke (Wu *et al.*, 2023). In an experimental animal study, targeting sGC simulator drug CYR119 was reported with beneficial in modulation of inflammatory cytokine expression in the central nervous system (Correia *et al.*, 2021). Furthermore, the novel Riociguat was also reported to be successful in modulation of systemic hypertension and systolic heart activity (Geschka *et al.*, 2011). When the cardiac effect of this drug is considered, as a nitric oxide independent sGC-cGMP stimulator, the Riociguat, reported a successful protective effect in the vasodilation, improving the donor organ function in heart transplantation performed animals, it was even found to be effective on cardiac infarct size and post-infarct failure in animals (Benke *et al.*, 2020). Although the most vital and ischemia affected organs are brain, heart and lungs, similar studies reported protective potential of this drug in various organs not only due to vasodilatory properties but also potential anti-inflammatory and antioxidant properties (Seker *et al.*, 2022). Although the

novel Riociguat is a recently developed treatment strategy to reduce organ injury in ischemic conditions and stroke, there is plenty of literature based on the protective effect of resveratrol in ischemic organ injury in different organs even in stroke (Lan *et al.*, 2023). The administration of this polyphenolic compound is reported with success in numerous experimental studies (Nabavi *et al.*, 2014). In one of these studies, Sinha *et al.* (2002), examined the neuroprotective effect of resveratrol, and results indicated that pre-treatment with resveratrol alleviated cerebral infarct size and oxidative stress in MCAO induced experimental stroke model in rats. In another study, Ashafaq *et al.* (2021) indicated that nanoparticles of resveratrol administration downregulated neuronal injury with interfering on oxidative stress, intrinsic apoptotic signaling, and pro-inflammatory TNF- α , IL-1 β , and IL-6 levels (Arpa & Ozturk, 2022). In addition, Jackson *et al.* (2024) indicated that resveratrol preconditioning downregulated neuronal cell death both in vivo and in vitro with regulating cellular PARP1 level. As observed in pre-treated, post-treatment with resveratrol in MCAO induced stroke was also found to be beneficial. Shin *et al.* (2010) indicated that treatment of the experiment animals with resveratrol following MCAO induced stroke alleviated tissue oxidative stress, pro-inflammatory IL-1 β and TNF- α levels. Moreover, Wang *et al.* (2023) indicated that resveratrol is a potent modality even in varicella zoster virus-induced ischemic stroke. When we compared our observations with the literature, we observed consistent neuroprotective effect of resveratrol treatment with

regulating apoptotic and inflammatory protein expression levels. Although resveratrol is found to be effective in MCAO induced stroke model in rats, some studies reported more beneficial success with combined treatment in various vasodilatory, antioxidant or neuroprotective drugs (Saleh *et al.*, 2014; Faggi *et al.*, 2018). Results of the combined treatment studies commonly reported more successful effects of these drugs compared to resveratrol alone. In this aspect our examinations indicated that resveratrol treatment alone, was successful in reducing cerebral injury and neurodegenerations in MCAO induced stroke model, but the results in resveratrol treatment alone, was successful compared to the stroke group; the most success is observed in combination treated animals.

CONCLUSION

In conclusion, our observations indicated that sGC stimulator Riociguat is a potent novel drug to alleviate MCAO induced cerebral stroke associated neuroinjury in rats with regulating apoptosis and inflammation. Additionally, co-treatment was more successful than single treatment with either resveratrol or Riociguat. Although, Riociguat has shown promising results, more studies are required to explore the effects of this sGC stimulator in cerebral ischemia associated stroke.

ACKNOWLEDGEMENTS. This study was financially supported by Dicle University Scientific Research and Project Coordinatorship with grant no: TIP.21.013.

ASLANOGLU, B.; KAYA, S.; GUNARA, S.O.; ATLAS, B.; SEKER, U.; GUZEL, B.C. & TURAN, Y. Potencial neuroprotector del novedoso estimulador de guanilato ciclasa soluble, el Riociguat solo o en combinación con resveratrol en un modelo experimental de ataque cerebrovascular en ratas. *Int. J. Morphol.*, 42(4):984-990, 2024.

RESUMEN: En este estudio, nuestro objetivo fue examinar el efecto de la coadministración del nuevo fármaco vasodilatador Riociguat junto con resveratrol para recuperar la neurodegeneración en lesiones por ataques cerebrovasculares experimentales. Para ello, se dividieron 35 ratas hembras adultas en cinco grupos (Control, MCAO, MCAO + R, MCAO + BAY, MCAO + C) de siete animales en cada uno. Los animales del grupo control no fueron sometidos a ninguna aplicación durante el experimento y se sacrificaron al final del estudio. Las ratas de los grupos expuestas a la oclusión de la arteria cerebral media (MCAO) indujeron un ataque cerebrovascular isquémico. El grupo MCAO + R recibió 30 mg/kg de resveratrol y el grupo MCAO + BAY recibió 10 mg/kg de Riociguat. El grupo MCAO + C recibió ambos fármacos simultáneamente. Los fármacos se administraron antes de la reperusión y las dosis adicionales se administraron a las 24 y 48 horas de la reperusión. Todos los animales en este estudio fueron sacrificados a las 72 horas del

experimento. Se recibieron cerebros totales para su análisis. Los resultados indicaron que la MCAO provocaba lesiones graves en la estructura cerebral. Los niveles tisulares de Bax, IL-6 e IL-1 β estaban regulados positivamente, pero se suprimió la inmunexpresión antiapoptótica de Bcl-2 ($p < 0,05$). En los animales tratados con resveratrol y Riociguat, las neurodegeneraciones y las expresiones de proteínas asociadas a la apoptosis y la inflamación mejoraron en comparación con el grupo MCAO, sin embargo el mayor éxito se obtuvo en el tratamiento combinado de animales expuestos en el grupo MCAO + C. Este estudio indicó que el nuevo estimulador de guanilato ciclasa soluble Riociguat no solo es un fármaco neuroprotector potente en el ataque cerebrovascular inducido por MCAO, sino que también la administración sinérgica de Riociguat junto con resveratrol tiene el potencial para aumentar el efecto neuroprotector del resveratrol en ratas experimentales expuestas a un ataque cerebrovascular.

PALABRAS CLAVE: Ataque cerebrovascular; Resveratrol; Riociguat; Apoptosis; Inflamación.

REFERENCES

- Arpa, A. & Ozturk, P. A. Histopathological effects of nimodipine and pentoxifylline on the vessel wall in end-to-end anastomoses in rat carotid arteries. *J. Exp. Clin. Med.*, 39(3):879-83, 2022.
- Ashafaq, M.; Intakhab Alam, M.; Khan, A.; Islam, F.; Khuwaja, G.; Hussain, S.; Ali, R.; Alshahrani, S.; Antar Makeen, H.; Alhazmi, H. A.; *et al.*, Nanoparticles of resveratrol attenuates oxidative stress and inflammation after ischemic stroke in rats. *Int. Immunopharmacol.*, 94:107494, 2021.
- Benke, K.; Németh, B. T.; Sayour, A. A.; Stark, K. A.; Oláh, A.; Ruppert, M.; Szabó, G.; Korkmaz-Icöz, S.; Horváth, E. M.; Benko, R.; *et al.*, Stimulation of soluble guanylate cyclase improves donor organ function in rat heart transplantation. *Sci. Rep.*, 10(1):5358, 2020.
- Bromont, C.; Marie, C. & Bralet, J. Increased lipid peroxidation in vulnerable brain regions after transient forebrain ischemia in rats. *Stroke*, 20(7):918-24, 1989.
- Correia, S. S.; Liu, G.; Jacobson, S.; Bernier, S. G.; Tobin, J. V.; Schwartzkopf, C. D.; Atwater, E.; Lonie, E.; Rivers, S.; Carvalho A.; *et al.*, The CNS-penetrant soluble guanylate cyclase stimulator CYR119 attenuates markers of inflammation in the central nervous system. *J. Neuroinflammation*, 18(1):213, 2021.
- Cui, B.; Wang, Y.; Jin, J.; Yang, Z.; Guo, R.; Li, X. & Li, Z. Resveratrol treats UVB-induced photoaging by anti-MMP expression, through anti-inflammatory, antioxidant, and antiapoptotic properties, and treats photoaging by upregulating VEGF-B expression. *Oxid Med. Cell. Longev.*, 2022:6037303, 2022.
- Faggi, L.; Pignataro, G.; Parrella, E.; Porrini, V.; Vinciguerra, A.; Cepparulo, P.; Cuomo, O.; Lanzillotta, A.; Mota, M.; Benarese, M.; *et al.*, Synergistic Association of Valproate and Resveratrol Reduces Brain Injury in Ischemic Stroke. *Int. J. Mol. Sci.*, 19(1):172, 2018.
- Geschka, S.; Kretschmer, A.; Sharkovska, Y.; Evgenov, O. V.; Lawrenz, B.; Hucke, A.; Hocker, B. & Stasch, J. P. Soluble guanylate cyclase stimulation prevents fibrotic tissue remodeling and improves survival in salt-sensitive Dahl rats. *PLoS One*, 6(7):21853, 2011.
- Jackson, C. W.; Xu, J.; Escobar, I.; Saul, I.; Fagerli, E.; Dave, K. R. & Perez-Pinzon, M. A. Resveratrol preconditioning downregulates PARP1 protein to alleviate PARP1-mediated cell death following cerebral ischemia. *Transl. Stroke Res.*, 15(1):165-78, 2024.
- Johnston, S. C.; Mendis, S. & Mathers, C. D. Global variation in stroke burden and mortality: estimates from monitoring, surveillance, and modelling. *Lancet Neurol.*, 8(4):345-54, 2009.

- Lan, T.; Dun, R.; Yao, D.; Wu, F.; Qian, Y.; Zhou, Y.; Zhan, T. T.; Shao, M. H.; Gao, J. D. & Wang, C. Effects of resveratrol on renal ischemia-reperfusion injury: A systematic review and meta-analysis. *Front. Nutr.*, 4(9):1064507, 2023.
- Li, J.; Liu, W.; Ding, S.; Xu, W.; Guan, Y.; Zhang, J. H. & Sun, X. Hyperbaric oxygen preconditioning induces tolerance against brain ischemia-reperfusion injury by upregulation of antioxidant enzymes in rats. *Brain Res.*, 1210:223-29, 2008.
- Melani, A.; Cipriani, S.; Corti, F. & Pedata, F. Effect of intravenous administration of dipyridamole in a rat model of chronic cerebral ischemia. *Ann. N. Y. Acad. Sci.*, 1207:89-96, 2010.
- Nabavi, S.; Li, H.; Daglia, M. & Nabavi, S. Resveratrol and stroke: from chemistry to medicine. *Curr. Neurovasc. Res.*, 11(4):390-7, 2014.
- Pan, Y.; Wang, X.; Liu, X.; Shen, L.; Chen, Q. & Shu, Q. Targeting ferroptosis as a promising therapeutic strategy for ischemia-reperfusion injury. *Antioxidants (Basel)*, 11(11):2196 2022.
- Puig, B.; Brenna, S. & Magnus, T. Molecular communication of a dying neuron in stroke. *Int. J. Mol. Sci.*, 19(9):2834, 2018.
- Saleh, M. C.; Connell, B. J.; Rajagopal, D.; Khan, B. V.; Abd-El-Aziz, A. S.; Kucukkaya, I. & Saleh, T. M. Co-administration of resveratrol and lipoic acid, or their synthetic combination, enhances neuroprotection in a rat model of ischemia/reperfusion. *PLoS One*, 9(1):e87865, 2014.
- Seker, U.; Kavak, D. E.; Guzel, B. C.; Baygeldi, S. B.; Yuksel, M.; Unay Demirel, O.; Kandemir, S. I. & Sener, D. Targeting soluble guanylate cyclase with Riociguat has potency to alleviate testicular ischaemia reperfusion injury via regulating various cellular pathways. *Andrologia*, 54(11):e14616, 2022.
- Seker, U.; Kaya, S.; Kandemir, S. I.; Sener, D.; Demirel, O. U. & Nergiz, Y. Effects of black cumin seed oil on oxidative stress and expression of membrane-cytoskeleton linker proteins, radixin, and moesin in streptozotocin-induced diabetic rat liver. *Hepatol. Forum*, 3(1):21-6, 2021.
- Shin, J. A.; Lee, H.; Lim, Y. K.; Koh, Y.; Choi, J. H. & Park, E. M. Therapeutic effects of resveratrol during acute periods following experimental ischemic stroke. *J. Neuroimmunol.*, 227(1-2):93-100, 2010.
- Sinha, K.; Chaudhary, G. & Kumar Gupta, Y. Protective effect of resveratrol against oxidative stress in middle cerebral artery occlusion model of stroke in rats. *Life Sci.*, 71(6):655-65, 2002.
- Wang, X.; Chen, H.; Song, F.; Zuo, K.; Chen, X.; Zhang, X. & Li, J. Resveratrol: a potential medication for the prevention and treatment of varicella zoster virus-induced ischemic stroke. *Eur. J. Med. Res.*, 28(1):400, 2023.
- White, B. C.; Sullivan, J. M.; DeGracia, D. J.; O'Neil, B. J.; Neumar, R. W.; Grossman, L. I.; Rafols, J. A. & Krause, G. S. Brain ischemia and reperfusion: Molecular mechanisms of neuronal injury. *J. Neurol. Sci.*, 179(S 1-2):1-33, 2000.
- Wu, J.; Jia, J.; Ji, D.; Jiao, W.; Huang, Z. & Zhang, Y. Advances in nitric oxide regulators for the treatment of ischemic stroke. *Eur. J. Med. Chem.*, 262:115912, 2023.
- Yang, R.; Shen, Y. J.; Chen, M.; Zhao, J. Y.; Chen, S. H.; Zhang, W.; Song, J. K.; Li, L. & Du, G. H. Quercetin attenuates ischemia reperfusion injury by protecting the blood-brain barrier through Sirt1 in MCAO rats. *J. Asian. Nat. Prod. Res.*, 24(3):278-89, 2022.

Corresponding author:

Seval Kaya, PhD
Department of Histology and Embryology
Faculty of Medicine
Istanbul Aydin University
Istanbul
TURKEY

E-mail: kaya.svl@gmail.com