

# Prevalence of Occipital Emissary Foramen and Its Clinical Relevance in Human Adult Skulls

## Prevalencia del Foramen Emisario Occipital y su Relevancia Clínica en Cráneos Humanos Adultos

Rasha M. Salama<sup>1</sup>; Hamad Alsaykhan<sup>1</sup> & Walaa A. Fadda<sup>1</sup>

---

SALAMA, R. M.; ALSAYKHAN, H. & FADDA, W. A. Prevalence of occipital emissary foramen and its clinical relevance in human adult skulls. *Int. J. Morphol.*, 44(2):610-616, 2026.

**SUMMARY:** The occipital emissary foramen (OEF) represents an important anatomical channel that transmits the occipital emissary vein, forming a venous communication between the extracranial suboccipital tissues and the intracranial occipital sinus. The prevalence and morphological variability of the OEF differ considerably across populations, reflecting developmental, genetic, and geographical influences. This descriptive observational study aimed to determine the incidence, laterality patterns, and morphometric characteristics of the OEF in 92 adult human dry skulls and to clarify its potential clinical implications. Skulls were systematically examined to document the presence or absence of the foramen, its position relative to the external occipital crest, side distribution, and total number of foramina per specimen. The study revealed that most skulls (81.5 %) exhibited at least one OEF, predominantly located on the squamous part of the occipital bone. Bilateral presentation represented the most frequent pattern, followed by unilateral and midline forms. A single OEF occurred most commonly, whereas double and multiple foramina were less frequent. This substantial variability underscores the relevance of understanding OEF anatomy, particularly in neurosurgical and neurointerventional procedures involving the posterior fossa and suboccipital region, where unanticipated emissary veins may increase the risk of bleeding or facilitate the spread of infection. These findings reinforce the importance of careful preoperative planning to minimize complications associated with emissary venous channels.

**KEY WORDS:** Occipital emissary foramen; Occipital emissary vein; Prevalence; Skulls; External occipital crest.

---

## INTRODUCTION

Emissary foramina of the skull represent anatomically variable channels that accommodate emissary veins, which serve as valveless venous conduits between the intracranial dural venous sinuses and the extracranial venous networks. Among these structures, the occipital emissary foramen (OEF) holds particular clinical relevance due to its communication with the occipital sinus and its position within the suboccipital surgical field. The anatomy of emissary veins is increasingly recognized as a major consideration in modern neurosurgical and neurointerventional approaches, particularly in the posterior cranial fossa, where inadvertent injury may result in significant venous bleeding or provide routes for infection spread (Keskil *et al.*, 2003).

The OEF exhibits considerable variation in prevalence, size, laterality, and morphology among different populations. These variations have been attributed to

differences in cranial development, vascular remodeling, genetic background, and environmental influences (Freire *et al.*, 2013).

As emissary veins lack valves, they permit bidirectional blood flow, contributing to thermoregulation and venous pressure equalization, but they may also facilitate transmission of pathological processes from superficial tissues into the cranial cavity (McGonnell & Akbareian, 2019). Consequently, detailed anatomical knowledge of the OEF is crucial for clinicians managing suboccipital surgical interventions.

Anatomical studies have shown that the prevalence of OEF ranges broadly from rare to frequent depending on the population studied, highlighting the need for region-specific morphometric data (Singh, 2024). Variations in number—whether single, double, or multiple foramina—

<sup>1</sup> Department of Anatomy and Histology, College of Medicine, Qassim University, Saudi Arabia.

also carry implications for surgical exposure and risk of venous injury. Moreover, the laterality of the OEF introduces additional complexity since unilateral and bilateral forms may differ in their venous drainage patterns, affecting surgical landmarks and procedural planning (Cohen *et al.*, 2025).

Emissary veins can become clinically significant by providing collateral circulation, which must be preserved during surgical approaches. Despite this clinical importance, studies on the OEF remain relatively limited compared with investigations of other cranial foramina. Many anatomical reports highlight gaps in the literature (Singhal & Ravindranath, 2013). The lack of standardized morphometric data poses potential risks for neurosurgeons and anatomists working in diverse clinical settings.

Therefore, the present study was designed to investigate the prevalence, distribution, and morphometric features of the OEF in adult human skulls from an anatomical collection in Saudi Arabia. By documenting its incidence and variability, this study provides essential anatomical data that can support safe surgical practice, guide radiological interpretation, and contribute to a broader understanding of cranial venous anatomy. The findings also enhance current knowledge regarding population-based differences in emissary foramina, supporting future anatomical and clinical investigations.

## MATERIAL AND METHOD

### Study Design

Descriptive observational study was conducted for approximately two months; October and November 2025 in 92 adult human dry skulls from the osteology collection of the anatomy laboratory, Anatomy and Histology department, College of Medicine, Qassim University, Saudi Arabia.

The study was approved by the Research Ethics Committee, Deanship of Graduate Studies and Scientific Research, Qassim University, Saudi Arabia (Approval No 26-13-4).

**Inclusion/exclusion criteria:** exclude juvenile skulls (open sutures), severely damaged occipital region.

### Procedures

Two independent observers examine each skull under good illumination. OEF defined as an identifiable foramen in the squamous part of the occipital bone.

Recording presence/absence; position and proximity

to external occipital crest; side (L/R/midline); number per skull (0, 1, >1). Also, measuring maximum foraminal diameter using digital calipers was done.

Specimens were photographed by a digital single-lens reflex camera (Canon D6 DSLR, Canon, Japan) equipped with a 100 mm macro lens (Canon EF 100mm f2.8 USM Macro Lens, Canon, Japan) in a Lightbox Mini Photo Studio Light Box with 6 Color Backdrops Photo Tent Kit 80Pcs LED Light Room Foldable Photography Lighting.

### Prevalence of OEF based on its anatomical position, was assigned into four groups as follows:

- Group 1 (n=17): No OEF on squamous part of occipital bones.
- Group 2 (n=34): There is unilateral (left/right) OEF on squamous part of occipital bones
- Group 3 (n=28): There is Bilateral OEF on squamous part of occipital bones
- Group 4 (n=13): There is midline solitary OEF on external occipital crest.

### Prevalence of OEF based on its number, was assigned into four groups as follows:

- Group 1 (n=17): No OEF.
- Group 2 (n=39): Single OEF.
- Group 3 (n=12): Double OEF.
- Group 4 (n=24): Multiple OEF.

### Statistical analysis

All quantitative data were subjected to descriptive statistical analysis using the mean, standard deviation, and range. Conversely, frequency and percentage were used to display qualitative data. The data was analyzed using IBM Corp.'s Statistical Package for the Social Sciences software, version 26 (SPSS 26.0) (Armonk, NY, USA).

## RESULTS

In this study, prevalence of OEF was examined in 92 human adult dry skulls free from any apparent pathological alterations before documentation. OEF were defined in the squamous part of the occipital bone.

### Prevalence of OEF based on its anatomical position

In Figure 1, it was observed that 75 human adult skulls (squamous part of the occipital bones) (81.5 %) have OEF and 17 human adult skulls (squamous part of the occipital bones) (18.5 %) have no OEF (Fig. 2).

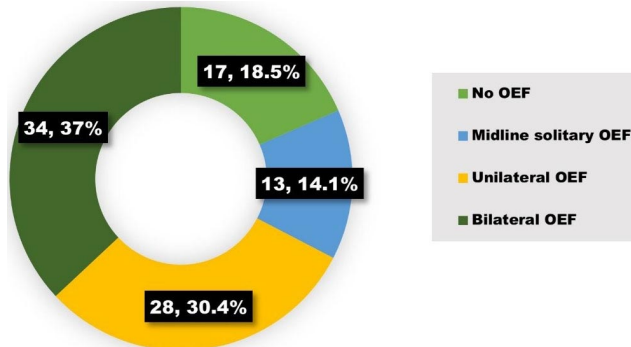


Fig. 1. Prevalence of OEF based on its anatomical position (n= 92 skulls).

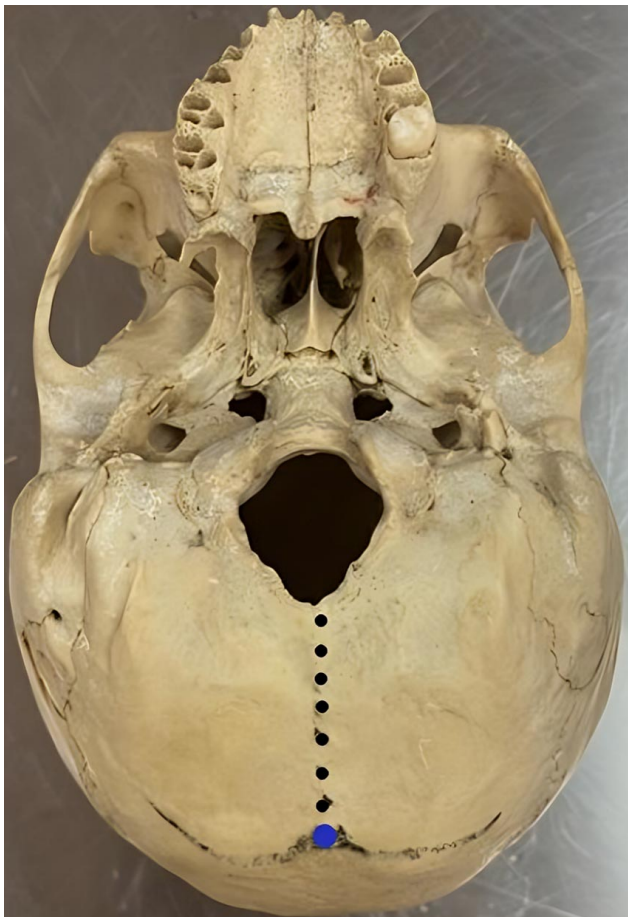


Fig. 2. Base of the skull depicting the absence of OEF on the squamous part of the occipital bone. Note; EOP (blue dot), and EOC (black dots).

Moreover, 13 human adult skulls (squamous part of the occipital bones) (14.1 %) have midline solitary OEF lying on external occipital crest (EOC), that extends from the external occipital protuberance (EOP) down to the foramen magnum (Fig. 3).

Regarding laterality of OEF, there were 28 human adult skulls (squamous part of the occipital bones) (30.4 %) have unilateral (right/left) OEF (Figs. 4 and 5), and 34 human adult skulls (squamous part of the occipital bones) (37 %) with bilateral OEF (Figs. 6 to 8).

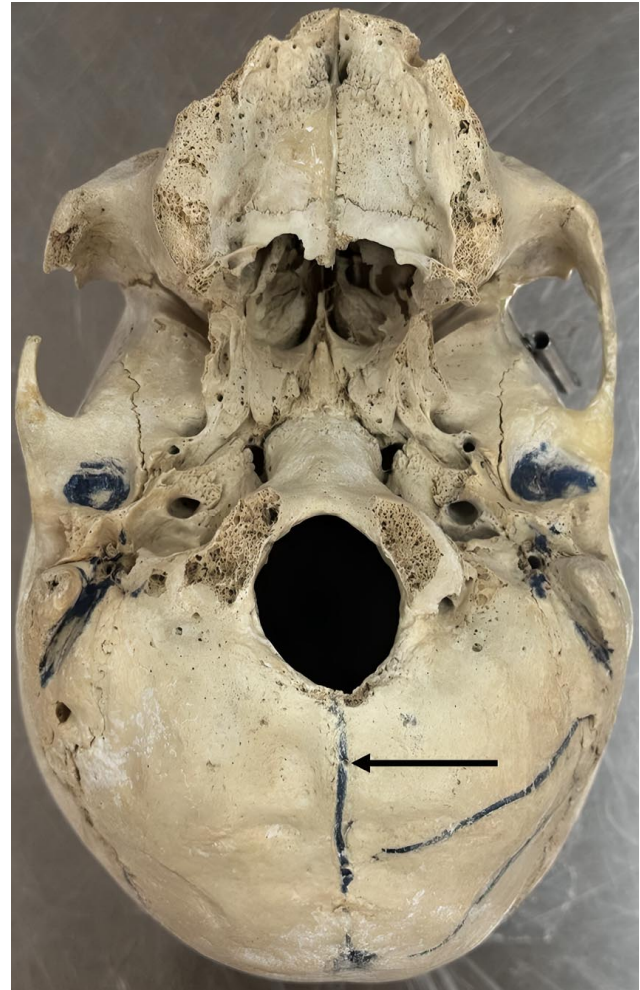


Fig. 3. Base of the skull illustrating the presence of a midline solitary OEF on the EOC (black arrow).

#### Prevalence of OEF based on its number

In Figure 9 there were 75 human adult skulls (squamous part of the occipital bones) (81.5 %) have OEF and 17 human adult skulls (squamous part of the occipital bones) (18.5 %) with no OEF (Fig. 2), 39 human adult skulls (squamous part of the occipital bones) (42.4 %) have single OEF (Figs. 4 and 5). 12 human adult skulls (squamous part of the occipital bones) (13 %) with double OEF (Fig. 6), and 24 human adult skulls (squamous part of the occipital bones) (16.1 %) have multiple OEF (Figs. 7 and 8).

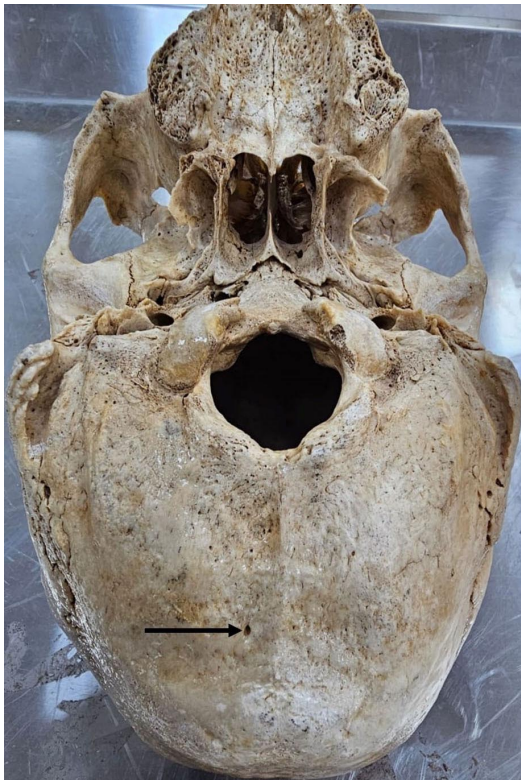


Fig. 4. Base of the skull displaying the presence of a unilateral single OEF on the right side of EOC (black arrow).

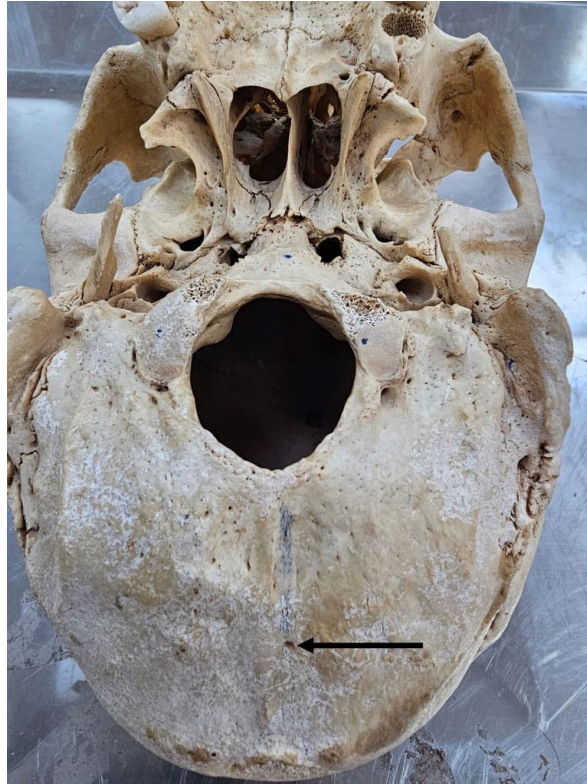


Fig. 5. Base of the skull displaying the presence of a unilateral single OEF just on the left side of EOC (black arrow).

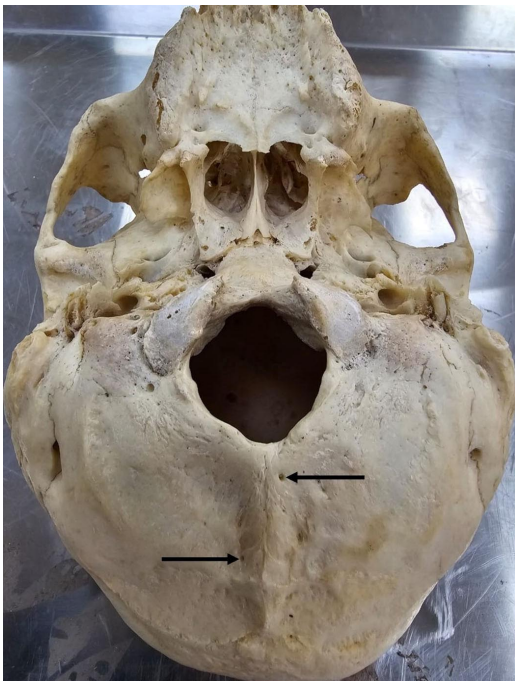


Fig. 6. Base of the skull demonstrating the presence of a bilateral double OEF on both sides of EOC (black arrow).

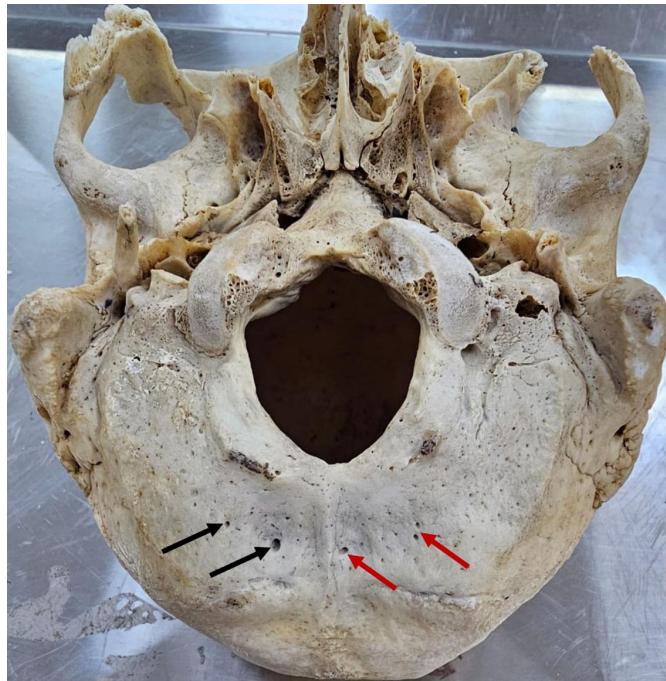


Fig. 7. Base of the skull showing the presence of a bilateral multiple OEF on right side (black arrow) and on left side (red arrow) of EOC.

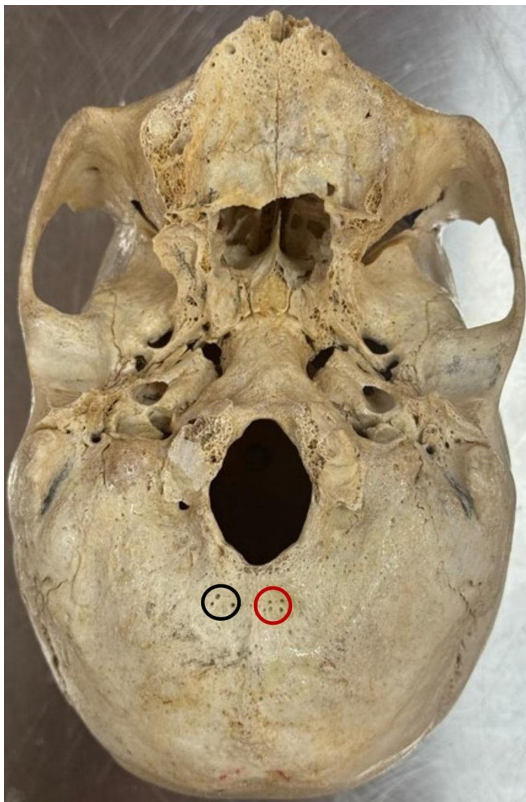


Fig. 8. Base of the skull depicting the presence of a bilateral multiple OEF on right side (black circle) and on left side (red circle) of EOC.

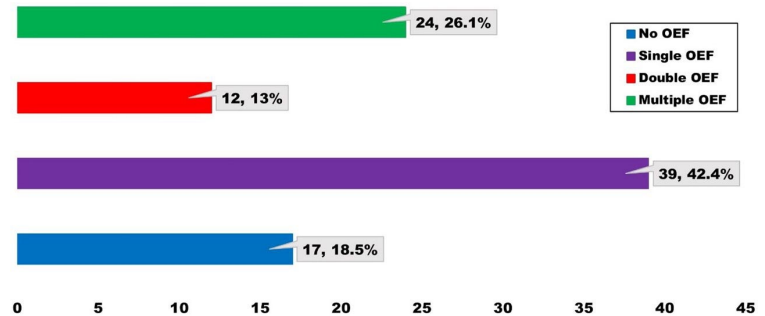


Fig. 9. Prevalence of OEF based on its number (n= 92 skulls).

The high prevalence of OEF identified in this study aligns with other anatomical investigations showing appreciable emissary foramen incidence in various populations. The predominance of skulls exhibiting the foramen, with bilateral forms more common than unilateral or midline variants, suggests a tendency toward symmetrical venous patterns in the posterior cranial region. Comparable findings have been documented by Murlimanju *et al.* (2011), who studied OEF in South-Indian skulls, and Jelev & Malinova, (2020) who proposed a classification of occipital venous anastomoses based on bilateral venous channels.

The lower frequency of midline foramina likely reflects developmental closure patterns of the occipital bone, where the external occipital crest may not consistently maintain a channel for venous transmission. Similar observations were reported by Alghamdi *et al.* (2022), who found that midline OEFs were less frequent than lateral ones, suggesting that lateral emissary routes provide more stable venous communication during cranial maturation.

When considering the number of foramina, the predominance of single OEF per skull is consistent with previous osteological studies, including those of Kwiatkowska *et al.* (2014) and Barbosa *et al.* (2022), which documented single foramina as the most common pattern in diverse populations. The presence of double or multiple foramina, although less frequent, remains clinically important, as multiple venous channels may indicate either developmental persistence of embryonic venous plexuses or adaptive collateral pathways in response to intracranial venous pressure variations.

The clinical implications of these findings are particularly relevant for surgical approaches to the posterior fossa. Emissary veins passing through the OEF can be a source of substantial bleeding, especially in cases where the veins are enlarged or form major collateral pathways. Therefore, preoperative identification of OEFs through imaging or careful anatomical assessment is crucial for preventing intraoperative complications.

## DISCUSSION

Skeletal morphological differences, which are the focus of extensive anatomical investigations, possess tangible relevance for ensuring the successful execution of contemporary diagnostic and therapeutic clinical procedures (Mudhol *et al.*, 2022; Magcaba *et al.*, 2024). Full comprehension of these variations is a fundamental prerequisite for minimizing potential risks during specialized interventions.

The present study documents significant anatomical variability in the OEF, a structure increasingly recognized for its clinical relevance in posterior fossa neurosurgery and neurointerventional procedures. Emissary veins transmitted through these foramina constitute important venous channels connecting intracranial and extracranial systems. Their valveless nature allows bidirectional blood flow, which is beneficial for thermoregulation and venous decompression but also introduces potential routes for infection spread and venous complications during surgical manipulation (Louis Jr. *et al.*, 2009).

Moreover, the presence of multiple or bilateral OEFs may alter patterns of venous drainage in patients with conditions such as sigmoid sinus stenosis, venous hypertension, or dural arteriovenous fistulas. In such scenarios, emissary veins can become enlarged and assume a vital compensatory role, as reported by Ruíz *et al.* (2022), reinforcing the need for meticulous radiological evaluation.

The study's findings also provide insight into variability across populations. Cranial anatomical differences have been attributed to a combination of genetic, environmental, and developmental factors. Comparative research by Alaftan *et al.* (2023), demonstrates population-specific patterns in cranial foramina morphology, highlighting the importance of localized anatomical reference data. The high prevalence observed in this Saudi Arabian sample contributes valuable information to the global dataset, supporting more precise clinical planning for regional populations.

Mechanistically, the occurrence and distribution of OEF can be explained by persistence or regression of embryonic emissary venous pathways. During cranial development, multiple venous channels exist before most regress in favor of major sinuses. Persistence of certain channels leads to formation of emissary foramina. The greater incidence of bilateral and single foramina in this study suggests that bilateral venous pathways may be developmentally more stable.

Overall, the study underscores the importance of anatomical awareness regarding OEF during neurosurgical, orthopedic, and interventional radiological procedures. Differences in morphology and number of foramina observed here reinforce the need for comprehensive anatomical knowledge to minimize surgical risks. The findings align with previous literature supporting the clinical relevance of emissary foramina and provide additional population-specific data to inform safe surgical practice.

## CONCLUSION

The knowledge of skull emissary foramina, especially OEF is important because of the recent advances in neurointerventional and neurosurgical techniques. The present study was therefore undertaken with respect to its clinical relevance and the objectives of the study were to find the incidence and topography of the occipital emissary foramina in human skulls.

**ACKNOWLEDGMENTS.** The authors express their sincere gratitude to the unlimited support provided by the deanship of higher education and research at Qassim

University to facilitate this research and providing access to the osteological collection and necessary laboratory facilities that enabled the completion of this study.

## Limitations of the study

Although this study provides valuable anatomical insights into the prevalence and morphological variations of the OEF, several limitations should be recognized. First, the analysis was conducted exclusively on dry skulls, which prevented correlation with soft-tissue venous structures, such as the caliber and patency of the occipital emissary vein or its functional role in intracranial–extracranial venous drainage. Second, demographic details such as age, sex, and ethnic background of the specimens were unavailable, limiting the ability to evaluate population-specific or sex-related differences. Third, the cross-sectional design did not permit assessment of inter-individual variability related to developmental, physiological, or pathological factors. Future studies integrating advanced imaging, larger multicenter samples, and clinical correlations are recommended to enhance the anatomical and surgical relevance of these findings.

---

SALAMA, R. M.; ALSAYKHAN, H. & FADDA, W. A. Prevalencia del foramen emisario occipital y su relevancia clínica en cráneos humanos adultos. *Int. J. Morphol.*, 44(2):610-616, 2026.

**RESUMEN:** El foramen emisario occipital (FEO) constituye un importante canal anatómico que transmite la vena emisaria occipital, estableciendo una comunicación venosa entre los tejidos suboccipitales extracraneales y el seno occipital intracraneal. La prevalencia y la variabilidad morfológica del FEO difieren considerablemente entre poblaciones, reflejando influencias evolutivas, genéticas y geográficas. Este estudio observacional descriptivo tuvo como objetivo determinar la incidencia, los patrones de lateralidad y las características morfométricas del FEO en 92 cráneos humanos adultos secos y dilucidar sus posibles implicaciones clínicas. Se examinaron sistemáticamente los cráneos para documentar la presencia o ausencia del foramen, su posición con respecto a la protuberancia occipital externa y/o cresta occipital externa, su distribución lateral y el número total de forámenes por espécimen. El estudio reveló que la mayoría de los cráneos (81,5 %) presentaban al menos un foramen emisario occipital (FEO), predominantemente ubicado en la porción escamosa del hueso occipital. La presentación bilateral fue el patrón más frecuente, seguida de las formas unilaterales y de la línea mediana. Un solo FEO fue el más común, mientras que los forámenes dobles y múltiples fueron menos frecuentes. Esta considerable variabilidad subraya la importancia de comprender la anatomía del FEO, particularmente en procedimientos neuroquirúrgicos y neurointervencionistas que involucran la fosa posterior y la región suboccipital, donde las venas emisarias imprevistas pueden aumentar el riesgo de hemorragia o facilitar la propagación de infecciones. Estos hallazgos refuerzan la importancia de una planificación preoperatoria cuidadosa para minimizar las complicaciones asociadas con los canales venosos emisarios.

**PALABRAS CLAVE:** Foramen emisario occipital; Vena emisaria occipital; Prevalencia; Cráneos; Cresta occipital externa.

## REFERENCES

- Alaftan, M.; Alkhater, S.; Alhaddad, F.; Alfaraj, A.; Alrashed, N.; Hiware, S.; Alghnimi, I.; Algowiez, R. & Ismail, E. Morphological variations and morphometry details of the foramen ovale in the Saudi population: a retrospective radiological study. *J. Med. Life*, 16(3):458-62, 2023.
- Alghamdi, M. A.; Honnegowda, T. M.; Nautiyal, A. & Deepanjan, M. Radiological and morphometric study of the emissary foramina and canal in the posterior cranial fossa of the human skull with its neurosurgical significance. *Asian J. Neurosurg.*, 17(4):588-94, 2022.
- Barbosa, D. A. F.; De Mendonça, D. S.; De Carvalho, F. S. R.; Kurita, L. M.; Silva, P. G. B.; Neves, F. S. & Costa, F. W. G. Systematic review and meta-analysis of lingual foramina anatomy and surgical-related aspects on cone-beam computed tomography: a PROSPERO-registered study. *Oral Radiol.*, 38(1):1-16, 2022.
- Cohen, A.; Kim, C. Y.; Raeburn, K.; Bubb, K.; Tabira, Y.; Iwanaga, J. & Tubbs, R. S. A review of the ethmoidal foramina and their clinical application. *Anat. Cell Biol.*, 58(1):1-7, 2025.
- Freire, A. R.; Rossi, A. C.; De Oliveira, V. C. S.; Prado, F. B.; Caria, P. H. F. & Botacin, P. R. Emissary foramina of the human skull: anatomical characteristics and its relations with clinical neurosurgery. *Int. J. Morphol.*, 31(1):287-92, 2013.
- Jelev, L. & Malinova, L. Occipital emissary foramina in human skulls: review of literature and proposal of a classification scheme of the occipital venous anastomoses in the posterior cranial fossa. *Anatomy*, 14(1):11-5, 2020.
- Keskil, S.; Gözil, R. & Calgüner, E. Common surgical pitfalls in the skull. *Surg. Neurol.*, 59(3):228-31, 2003.
- Kwiatkowska, B.; Szczerkowski, J. & Nowakowski, D. Variation in foramina transversaria of human cervical vertebrae in the medieval population from Sypniewo (Poland). *Anthropol. Rev.*, 77(2):175-88, 2014.
- Louis Jr., R. G.; Loukas, M.; Wartmann, C. T.; Tubbs, R. S.; Apaydin, N.; Gupta, A. A.; Spentzouris, G. & Ysique, J. R. Clinical anatomy of the mastoid and occipital emissary veins in a large series. *Surg. Radiol. Anat.*, 31(2):139-44, 2009.
- Magcaba, N.; Olojede, S. O.; Lawal, S. K.; Rennie, C.; Azu, O. O. & Naidu, E. C. Morphology and morphometry of the anterior clinoid process in a select South African population. *J. Anat. Soc. India*, 73(2):167-71, 2024.
- McGonnell, I. M. & Akbareian, S. E. Like a hole in the head: development, evolutionary implications and diseases of the cranial foramina. *Semin. Cell Dev. Biol.*, 91:23-30, 2019.
- Mudhol, R.; Narahari, S. & Havaladar, R. Morphological and anthropometrical features of human ear ossicles: a 1-year cadaveric observational study. *J. Anat. Soc. India*, 71(2):88-92, 2022.
- Murlimanju, B. V.; Prabhu, L. V.; Pai, M. M.; Jaffar, M.; Saralaya, V. V.; Tonse, M. & Prameela, M. D. Occipital emissary foramina in human skulls: an anatomical investigation with reference to surgical anatomy of emissary veins. *Turk. Neurosurg.*, 21(1):36-8, 2011.
- Ruíz, D. S. M.; Gailloud, P.; Rüfenacht, D. A.; Delavelle, J.; Henry, F. & Fasel, J. H. D. The craniocervical venous system in relation to cerebral venous drainage. *AJNR Am. J. Neuroradiol.*, 23(9):1500-8, 2002.
- Singh, R. Prevalence and morphometry of occipital foramen in dry skulls and its clinical implications. *J. Craniofac. Surg.*, 35(4):e391-4, 2024.
- Singhal, S. & Ravindranath, R. Occipital emissary foramina in South Indian modern human skulls. *ISRN Anat.*, 2013:727489, 2013.

Corresponding author:  
Department of Anatomy and Histology  
College of Medicine  
Qassim University  
SAUDI ARABIA

E-mail: H.ALSAYKHAN@qu.edu.sa