Int. J. Morphol.,
44(4):1149-1156, 2026.

http://dx.doi.org/10.4067/s0717-95022026000401149

Development of an Artificial Intelligence–Assisted Photogrammetric Method for Three-Dimensional Modeling of the Human Fetal Lower Limb Skeleton

Desarrollo de un Método Fotogramétrico Asistido por Inteligencia Artificial para la Modelización Tridimensional del Esqueleto del Miembro Inferior Fetal Humano

Jelen Vanessa López-Patiño[1]; Julián Guevara Realpe[1]; Francisco Luis Hernández[2] & María Carolina Pustovrh[1]

LÓPEZ-PATIÑO, J. V.; GUEVARA REALPE, J.; HERNÁNDEZ, F. L. & PUSTOVRH, M. C. Development of an artificial intelligence–assisted photogrammetric method for three-dimensional modeling of the human fetal lower limb skeleton. *Int. J. Morphol., 44(4)*:1149-1156, 2026.

SUMMARY: Fetal anatomy provides essential information for documenting and understanding human prenatal development and the anatomical bases of congenital anomalies. However, access to human fetal specimens for teaching and research purposes has progressively become more restricted due to ethical, legal and logistical limitations. This has resulted in a significant reduction in the availability of cadaveric material. In this context, traditional educational resources such as two-dimensional atlases and synthetic physical models are inadequate for accurately representing the three-dimensional complexity of fetal morphology. These limitations emphasize the necessity of developing realistic, accessible, and ethically acceptable digital alternatives. The left lower limb of a male fetus at 28 weeks of gestation was prepared using an osteotechnical protocol that included glycerin preservation, controlled heating, soft tissue removal, bleaching and microdissection. This was in order to preserve the delicate fetal ossification centers. A total of 576 high-resolution images were acquired using an iPhone 11 Pro and processed using Specimen Cloner®, an AI-based photogrammetric system developed specifically for this study. The AI algorithm optimized texture detection, segmentation and three-dimensional reconstruction. The resulting model was then exported to the Sketchfab platform for interactive online visualization. The osteotechnical preparation made it possible to clearly identify the osseous, cartilaginous and ligamentous components of the fetal lower limb. The AI-assisted photogrammetric model accurately reproduced the relevant anatomical structures, such as the interosseous membrane, the epiphyses of the femur and tibia, ligament insertions and cartilaginous regions. The digital model preserved the morphology, colour and surface texture of the original, and was made available via a QR code for educational purposes. A high-fidelity fetal skeletal model can be generated using a precise, cost-effective and ethically sound method that integrates photogrammetry and artificial intelligence. This approach is a valuable alternative to the limited availability of fetal cadavers, helps to develop digital anatomy repositories and increases access to high-quality anatomical resources for teaching and biomedical research.

KEY WORDS: Anatomy; Fetus; Lower limb bones; Photogrammetry; Artificial Intelligence.

INTRODUCTION

Human fetal anatomy is a fundamental field in medicine and developmental biology because it provides essential insight into how anatomical structures form, differentiate, and mature during life in the womb. A deep knowledge of fetal morphology is vital. This knowledge is necessary to understand normal embryonic and fetal development. It is also necessary in order to explain the anatomical basis of congenital anomalies. Finally, this knowledge is required to comprehend the long-term clinical implications of these anomalies.

However, there are significant limitations to the study and teaching of fetal anatomy. Traditional educational approaches rely heavily on two-dimensional (2D) resources such as anatomical atlases, histological sections, and schematic illustrations, as well as physical models made from synthetic materials. While these tools are useful for beginners, they cannot show the full 3D complexity and spatial relationships of fetal structures. Accurately interpreting such materials often requires advanced anatomical training, which can hinder effective

[1] Department of Morphology, School of Basic Sciences, Faculty of Health, Universidad del Valle, Cali, Colombia.
[2] School of Civil Engineering and Geomatics, Faculty of Engineering, Universidad del Valle, Cali, Colombia.
FUNDING. This study was funded by the 2020 Call for Support for Doctoral Students (Grant Code 1918), Vice-Rectory for Research, Universidad del Valle, Cali, Colombia.

Received: 2026-02-16 Accepted: 2026-06-14

learning in the early stages of medical education (Nicholson *et al*., 2006).

Access to human cadaveric material for teaching and research purposes is becoming increasingly restricted due to ethical considerations, legal regulations, and limited availability. These restrictions are particularly pronounced in the case of fetal specimens, which are rare and highly sensitive from an ethical standpoint. Consequently, opportunities for direct anatomical observation are limited, and repeated handling of fragile specimens may compromise their structural integrity. These constraints emphasize the importance of developing alternative strategies that can accurately visualize fetal anatomy while mitigating ethical and practical challenges (Morar *et al*., 2008).

In this context, the fetal skeleton is an invaluable model for studying 3D anatomy. The skeleton provides the body with its structural framework and plays a central role in forming and enabling the function of the limbs. During early development, mesenchymal cell condensations arise within the limb bud and subsequently differentiate into cartilage to form primary ossification centers. Skeletal development follows well-defined proximodistal, anteroposterior, and dorsoventral patterns. In the lower limb, this process begins with the formation of the pelvic girdle and progresses distally towards the phalanges (Long & Ornitz, 2013). These sequential, spatially coordinated events make the fetal skeleton ideal for 3D modeling and educational visualization.

A series of 2D images captured from multiple angles can be used to create 3D models using photogrammetry, an emerging technology in anatomy. Photogrammetry is defined as the collection of methods and procedures used to deduce the shape and dimensions of an object from a series of 2D photographs taken from various perspectives (Mikhail *et al*., 2001; de Jesús-Luis *et al*., 2019). Compared to conventional techniques such as computed tomography, photogrammetry has been shown to be a low-cost and efficient method of acquiring 3D data, offering a practical alternative for generating surface models in contexts where traditional imaging is expensive or inaccessible (Rivera & Salinas, 2025).

Furthermore, as a non-invasive technique, photogrammetry is well-suited to biomedical applications (Ey-Chmielewska *et al*., 2015). It has a wide range of applications, including in the biomedical sciences. Its most notable attributes are its non-invasive nature and remarkable economic efficiency — features that have sparked growing interest in its use for anatomical purposes. This preference is rooted in comparisons with traditional methods of generating three-dimensional models in biomedical contexts. Techniques such as laser scanning, computed tomography and magnetic resonance imaging have commonly been used in the past; however, these typically require more expensive, larger and heavier equipment than photogrammetry (Struck *et al*., 2019).

Nevertheless, photogrammetry poses certain technical challenges that limit its application in certain contexts. These include the need for high-capacity computing equipment to accurately render 3D models, as well as the requirement for professional-grade cameras and controlled lighting conditions to ensure optimal results. The technique also requires the sample to be precisely positioned during image acquisition, as inadequate control may lead to variations in model quality. Furthermore, rendering times may be prolonged, necessitating advanced computational resources to efficiently process large volumes of data (Tóth *et al*., 2021; Talevi *et al*., 2023).

These limitations can be overcome using artificial intelligence (AI). Advanced AI-based approaches have been shown to improve the precision and efficiency of 3D reconstruction workflows in medical imaging (Nikhita *et al*., 2025).

This study aims to develop and evaluate an AI-based model for generating 3D models of the fetal skeleton. By integrating advances in photogrammetry with AI algorithms, the model provides an accessible and effective educational solution that overcomes the ethical and practical limitations associated with studying fetal specimens.

MATERIAL AND METHOD

The anatomical specimen analyzed in this study was obtained from the collection of the Anatomy Laboratory at the Department of Morphology at the Universidad del Valle in Cali, Colombia. The sample consisted of the left lower limb of a male fetus, disarticulated at the sacroiliac joint. The fetus had a crown–rump length of 271 mm, weighed 2560 g, and was estimated to be 28 weeks old.

The dissected limb measured 97 mm for both the femur and the tibia, and 76 mm for the foot. The total weight of the limb was recorded as 326 g. No macroscopic evidence of congenital anomalies, trauma or pathological alterations that could compromise skeletal morphology was observed in the specimen.

All procedures were conducted in compliance with national legislation and international ethical standards

governing research involving human anatomical material. Ethical approval was granted by the Institutional Committee for Human Ethics Review (CIREH) of Universidad del Valle (Approval Code: 010-020).

Osteotechnical preparation

Skeletal preparation of the specimen was performed using a modified osteotechnical protocol that was designed to preserve delicate fetal ossification centers while ensuring complete removal of soft tissues.

Initial preservation

The limb was immersed in 99.8 % glycerine for seven days. This enhanced the tissue's hydration and elasticity, making it easier to manipulate and reducing the risk of structural damage during processing.

Thermal maceration

Following glycerin preservation, the specimen was exposed to controlled heating. The temperatures ranged between 90°C and 100°C. This reduced the viscosity of the glycerin and increased molecular mobility, promoting deeper penetration into tissues and facilitating the separation of soft tissues without altering developing bone structures.

Mechanical soft tissue removal

Any residual soft tissues were carefully removed using fine dissection instruments. Gentle mechanical friction was applied to prevent damage to the immature skeletal elements.

Bleaching process

The specimen was subjected to progressive bleaching using a commercial aqueous solution of hydrogen peroxide and sodium carbonate. The concentration was increased sequentially (from 30 % to 50 % to 70 %) to achieve adequate whitening and the complete removal of organic residues.

Final cleaning and drying

The skeletal elements were immersed in isopropyl alcohol for 24 hours to promote dehydration and degreasing. Final cleaning was performed using a MEIJI TECHNO stereoscopic microscope (Meiji Techno CO., Ltd., Saitama, Japan). Any remaining tissue fragments were removed using a #3 scalpel handle with a #11 blade, toothless Adson forceps, and blunt-tip scissors. The bone surfaces were then gently refined using 360-grit wet sandpaper to eliminate any residual debris while preserving the surface morphology.

Image Acquisition

Digital image capture was conducted to support 3D reconstruction. A total of 576 high-resolution images were acquired using an iPhone 11 Pro (Apple Inc., Cupertino, CA, USA), equipped with a triple-camera system comprising a wide-angle lens (f/1.8), an ultra-wide-angle lens (f/2.4 with a 120° field of view), and a telephoto lens (f/2.0 with 2× optical zoom).

The photographs were taken from an approximate distance of 50 cm in uniform natural lighting conditions. Images were captured in both JPEG and RAW formats to preserve maximum detail. The specimen was suspended using nylon monofilament lines to allow unrestricted 360° rotation and consistent surface coverage during image acquisition. The camera was mounted on a fixed tripod, and photographs were taken sequentially as the specimen was manually rotated through small angles. Although no strict control over overlap was enforced, the small rotational steps between captures resulted in adequate visual overlap between consecutive frames. This approach ensured sufficient stereoscopic redundancy for 3D reconstruction using structure-from-motion (SfM) photogrammetry, while minimizing occluded areas.

Image processing and three-dimensional reconstruction

Image processing and 3D reconstruction were performed using Specimen Cloner®, a photogrammetric artificial intelligence system that was developed specifically for this study in order to generate anatomical digital replicas at a scale of 1:1.

The images were processed through an automated workflow that identified morphological reference points and established precise photogrammetric correspondences. The system operates using a supervised learning architecture based on the extraction of spatial and textural patterns from anatomical data. Through machine learning techniques, the system optimizes the spatial alignment of images and preserves anatomical geometry during digital reconstruction. The resulting 3D anatomical model was exported to the Sketchfab® web platform for interactive visualization, morphological analysis and academic dissemination.

RESULTS

Anatomical osteotechnical model of the left fetal lower limb

This study employed an osteotechnical protocol to create a detailed anatomical model of the left fetal lower

limb, resulting in a well-preserved skeletal specimen with excellent structural integrity (Fig. 1). This process allowed for the consistent differentiation of osseous, cartilaginous and ligamentous components, enabling precise anatomical identification without distortion of spatial relationships.



Fig. 1. Bones of the left fetal lower limb following osteotechnic preparation. IL: ilium; IS: ischium; Ci: iliac crest; Fe: femur; Cf: femoral head; Ti: tibia; Fi: fibula; MIO: interosseous membrane; M: lateral malleolus; C: calcaneus; MTS: metatarsals. Scale bar = 40 mm.

Within the pelvic girdle, the ilium, ischium and pubis could be clearly identified. The iliac crest remained predominantly cartilaginous, which is consistent with the gestational age of the specimen. The acetabular region retained its anatomical configuration, maintaining spatial integration between the pelvic elements.

The femur had an ossified diaphysis with clearly defined cortical contours; however, the femoral head and distal condyles were still cartilaginous. Both the greater and lesser trochanters were distinguishable. The ligament of the femoral head could be clearly visualized, with its anatomical insertion and orientation preserved.

At the knee joint, the medial and lateral menisci, along with the anterior and posterior cruciate ligaments, were identified. The tibial and fibular collateral ligaments, as well as the patellar ligament, were also preserved. The patellar ligament was observed to insert into a cartilaginous patella, thus maintaining native anatomical relationships and enabling accurate visualization of joint organization.

In the leg, the tibia and fibula had ossified diaphyses that were separated by a clearly defined interosseous membrane that extended along their shafts. In the foot, the tarsal bones were still cartilaginous, while the metatarsals and phalanges showed different levels of ossification, which is typical of fetal skeletal development at this stage.

Figure 2 shows the knee joint in a slightly flexed position and highlights the patella, patellar ligament, lateral femoral condyle, lateral meniscus, tibial tuberosity and proximal interosseous membrane. This preparation demonstrates a high degree of structural resolution, enabling the precise identification of joint components and soft tissue attachments.

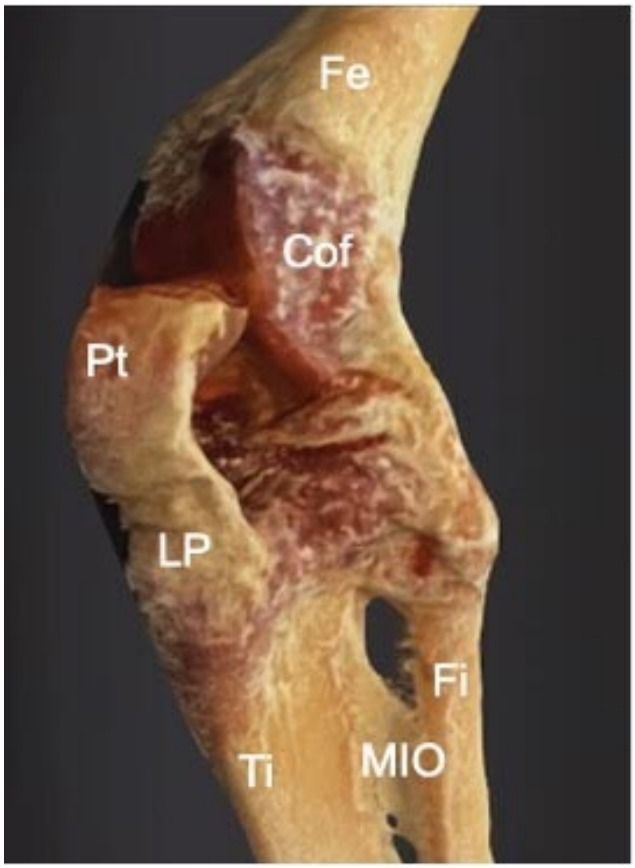

Fig. 2. Anterolateral view of the left fetal knee joint following osteotechnic preparation. Fe: femur; Cof: femoral condyle; Pt: patella; Lp: patellar ligament; Ti: tibia; Fi: fibula; MIO: interosseous membrane.

Three-dimensional digital model

The AI-enhanced photogrammetric workflow produced a high-resolution, 3D digital model of the left fetal lower limb. The model accurately reproduced the surface morphology, color and texture, faithfully reflecting the anatomical features observed in the physical osteotechnical preparation.

Clear differentiation between osseous, cartilaginous and ligamentous tissues was achieved. Fine anatomical details, including ligament insertions, epiphyseal cartilage and the interosseous membrane, were preserved with high fidelity. The digital model enabled unrestricted visualization from multiple angles, facilitating the assessment of the spatial relationships between the skeletal elements and improving 3D anatomical understanding.

Figure 3 shows the 3D model from the front, demonstrating how the pelvic girdle, femur, leg bones and foot structures are organized and aligned.

Digital dissemination and accessibility

The finalized 3D model was exported to the Sketchfab® web platform to enable interactive visualization and open access dissemination. A quick response (QR) code was generated to provide direct access to the model, thereby increasing its availability as a digital resource for the education of fetal anatomy and morphological research (Fig. 4).



Fig. 3. Anterior view of the three-dimensional digital model of the left fetal lower limb. IL: ilium; Pb: pubis; IS: ischium; Fe: femur; Cf: femoral head; Ti: tibia; Pt: patella; MTS: metatarsals.

Fig. 4. Quick response (QR) code providing access to the interactive three-dimensional model of the left fetal lower limb hosted on the Sketchfab platform.

DISCUSSION

This study highlights the benefits of combining an osteotechnical protocol with an artificial intelligence-enhanced photogrammetric workflow for the faithful preservation, high-resolution visualization, and digital dissemination of the fetal lower limb skeleton. This approach addresses two long-standing issues in anatomical education and research: the ethical and practical limitations of using fetal specimens and the limitations of two-dimensional teaching resources. By creating both a physical osteotechnical preparation and a high-fidelity 3D digital model, this study provides an ethical, reusable alternative for the study of fetal morphology.

The osteotechnical preparation yielded a specimen of remarkable structural integrity. This preserved the delicate ossification centers, cartilaginous epiphyses, and ligamentous attachments. Such a high level of detail is rarely achieved in fetal material due to the fragility of the developing skeletal elements. The clear differentiation between the ossified and cartilaginous components reflects the chronology of known skeletal development in the lower limb. In this process, diaphyseal ossification occurs before epiphyseal maturation, with the distal elements remaining largely cartilaginous at the mid-gestation stage (Long & Ornitz, 2013). Preservation of the spatial relationships between the pelvic girdle, femur, leg bones, and foot structures provides a morphologically accurate representation of proximodistal and regional patterning, which is essential for understanding limb development and congenital anomalies.

Traditional anatomical instruction relies heavily on atlases, histological sections, and schematic diagrams. While these resources are invaluable, they have limited ability to convey true three-dimensional relationships, especially in complex developmental contexts (Azer & Azer, 2016; Fahrni & Sabatasso, 2025). Cadaveric material remains the gold standard for anatomical education. However, access to fetal specimens is increasingly restricted by ethical and legal frameworks, and

repeated handling accelerates structural degradation (Morar *et al*., 2008). In this context, creating a digital surrogate from a real specimen is a compelling solution. The 3D model generated in this study faithfully reproduced the specimen's surface morphology, color and texture, enabling unrestricted exploration from multiple angles. Such immersive visualization supports spatial cognition and bridges the gap between abstract representations and real anatomy.

In this context, the present findings are strongly supported by the comprehensive review conducted by Bui *et al*., (2021). They analyzed the role of various 3D visualization modalities in medical education, including 3D-printed models, augmented reality, and virtual reality. They demonstrated that traditional slide-based instruction predominantly promotes passive learning, which limits students' ability to understand spatial relationships, particularly in subjects such as embryology and anatomy that are anatomically complex. In contrast, three-dimensional modalities encourage active learning, enhancing spatial cognition and improving long-term knowledge retention (Hoyek *et al*., 2014; Bui *et al*., 2021). Allowing learners to manipulate, rotate and explore structures from multiple perspectives strengthens their understanding of form and spatial organization. These advantages are particularly relevant for fetal anatomy, where ethical and logistical constraints restrict access to cadaveric material. The digital fetal skeletal model presented in this study embodies these principles, providing an interactive, reusable, and ethically sound resource that transforms a rare specimen into a permanent educational asset.

Zuñiga *et al*. (2024a) developed a 3D model of the tracheobronchial tree for teaching macroscopic anatomy. They demonstrated that modelling promotes 'learning to learn', enhances spatial comprehension, and facilitates the integration of form, relationships, and function. Similarly, Zuñiga *et al*. (2024b) showed that meaningful learning in macroscopic anatomy depends on students' ability to mentally rotate and contextualize structures in three dimensions. Unlike adult- or animal-based models, the present study applies these principles to human fetal morphology, a field in which ethical constraints and a lack of specimens severely limit access. Transforming a single fetal specimen into a durable digital resource is consistent with the pedagogical framework proposed by these authors, in which modelling acts as a bridge between observation, reasoning and anatomical comprehension.

The educational value of 3D visualization is well documented. Studies have shown that 3D models and virtual reconstructions improve spatial understanding and knowledge retention in undergraduate and postgraduate medical education (Bui *et al*., 2021; Silén *et al*., 2022). In the field of musculoskeletal anatomy, for instance, 3D representations can clarify complex spatial arrangements that would otherwise be challenging to discern from 2D images alone (Li *et al*., 2015; Lim *et al*., 2016). While previous studies have primarily focused on adult anatomy or pathological conditions such as fractures, the present study applies these principles to fetal morphology, an area where ethical constraints severely restrict direct access. This approach provides an anatomically accurate, manipulable digital model that enables repeated observation without risk to the original specimen or ethical concerns.

Photogrammetry has emerged as a cost-effective alternative to computed tomography and laser scanning for 3D reconstruction in anatomical contexts (de Jesús-Luis *et al*., 2019; Struck *et al*., 2019). However, conventional workflows often require extensive manual intervention and are computationally demanding, which limits scalability (Tóth *et al*., 2021; Talevi *et al*., 2023). The AI-enhanced platform used in this study optimized the detection of reference points, camera alignment and mesh reconstruction, thereby reducing operator dependence and improving consistency. This is consistent with recent findings that artificial intelligence can significantly enhance the efficiency and accuracy of 3D reconstruction pipelines in biomedical imaging (Nikhita *et al*., 2025). The resulting model preserved fine anatomical details, including ligament insertions, epiphyseal cartilage, and the interosseous membrane. This shows that AI-assisted photogrammetry can meet the high morphological standards needed in anatomical science.

Beyond visualization, digital dissemination is a critical aspect of this work. Hosting the model on an open-access platform and providing a QR code transforms a single fetal specimen into an educational resource accessible worldwide. This approach is in line with current thinking in morphological education, where anatomical modeling is recognized as a means of making complex structures more accessible and reducing reliance on fragile or scarce specimens. Similar approaches in clinical contexts have demonstrated that 3D visualization can enhance understanding, trust, and engagement among patients and healthcare providers (Lee & Shin, 2025). In education, freely accessible 3D models can support self-directed learning and be integrated into various curricula, particularly in institutions with limited access to cadaveric material.

CONCLUSION

Despite its strengths, this study has limitations. The full spectrum of developmental variability cannot be captured as it is based on a single specimen. Future work should

therefore expand the sample size to include specimens of different gestational ages and sexes, enabling comparative morphometric analyses and the construction of developmental series. Additionally, while the AI-assisted workflow improved efficiency, it still requires high-quality images and computational resources. Continued refinement of automated pipelines may further reduce technical barriers and encourage wider adoption.

This study demonstrates the effectiveness and ethics of combining osteotechnical preparation with AI-enhanced photogrammetry in the study and teaching of fetal anatomy. This approach addresses the educational and ethical challenges inherent in fetal anatomical research by preserving morphological fidelity, enabling immersive 3D exploration and facilitating open-access dissemination. This study redefines 3D modelling as a transformative pedagogical strategy with the power to revolutionize the teaching and study of developmental morphology for learners of all generations.

ACKNOWLEDGEMENT. The authors thank the Department of Morphology, Universidad del Valle, Cali, Colombia, for granting access to the fetal specimens under institutional custody. The specimens used in this study belong to the institutional anatomical collection established prior to current regulatory frameworks. The authors also express their respect and gratitude to the anonymous donors whose contributions support anatomical education and research.

LÓPEZ-PATIÑO, J. V.; GUEVARA REALPE, J.; HERNÁNDEZ, F. L. & PUSTOVRH, M. C. Desarrollo de un método fotogramétrico asistido por inteligencia artificial para la modelización tridimensional del esqueleto del miembro inferior fetal humano. *Int. J. Morphol., 44(4)*:1149-1156, 2026.

RESUMEN: La anatomía fetal proporciona información esencial para documentar y comprender el desarrollo prenatal humano y las bases anatómicas de las anomalías congénitas. Sin embargo, el acceso a especímenes fetales humanos con fines docentes y de investigación se ha restringido progresivamente debido a limitaciones éticas, legales y logísticas. Esto ha resultado en una reducción significativa de la disponibilidad de material cadavérico. En este contexto, los recursos educativos tradicionales, como los atlas bidimensionales y los modelos físicos sintéticos, son inadecuados para representar con precisión la complejidad tridimensional de la morfología fetal. Estas limitaciones resaltan la necesidad de desarrollar alternativas digitales realistas, accesibles y éticamente aceptables. El miembro inferior izquierdo de un feto masculino de 28 semanas de gestación se preparó mediante un protocolo osteotécnico que incluyó conservación con glicerina, calentamiento controlado, eliminación de tejido blando, blanqueamiento y microdisección. Esto se hizo para preservar los delicados centros de osificación fetal. Se adquirieron un total de 576 imágenes de alta resolución con un iPhone 11 Pro y se procesaron con Specimen Cloner®, un sistema fotogramétrico basado en IA desarrollado específicamente para este estudio. El algoritmo de IA optimizó la detección de texturas, la segmentación y la reconstrucción tridimensional. El modelo resultante se exportó a la plataforma Sketchfab para su visualización interactiva en línea. La preparación osteotécnica permitió identificar claramente los componentes óseos, cartilaginosos y ligamentosos del miembro inferior fetal. El modelo fotogramétrico asistido por IA reprodujo con precisión las estructuras anatómicas relevantes, como la membrana interósea, las epífisis del fémur y la tibia, las inserciones de ligamentos y las regiones cartilaginosas. El modelo digital conservó la morfología, el color y la textura superficial del original, y se puso a disposición mediante un código QR con fines educativos. Se puede generar un modelo esquelético fetal de alta fidelidad utilizando un método preciso, rentable y éticamente responsable que integra fotogrametría e inteligencia artificial. Este enfoque constituye una valiosa alternativa ante la limitada disponibilidad de cadáveres fetales, contribuye al desarrollo de repositorios de anatomía digital y facilita el acceso a recursos anatómicos de alta calidad para la docencia y la investigación biomédica.

PALABRAS CLAVE: Anatomía; Feto; Huesos de los miembros inferiores; Fotogrametría; Inteligencia artificial.

REFERENCES

Azer, S. A. & Azer, S. 3D anatomy models and impact on learning: A review of the quality of the literature. *Health Prof. Educ., 2(2)*:80-98, 2016.

Bui, I.; Bhattacharya, A.; Wong, S. H.; Singh, H. R. & Agarwal, A. Role of three-dimensional visualization modalities in medical education. *Front. Pediatr., 9*:760363, 2021.

De Jesús-Luis, A. S.; Ordóñez-Velázquez, S.; Pineda-Martínez, D.; Brenes-Solano, B. & González-Fernández, J. Fotogrametría: Cómo crear modelos tridimensionales de bajo costo, con características realistas y fácil manipulación, para su uso en la enseñanza y el diagnóstico médico. *Investig. Educ. Med., 8(32)*:100-11, 2019.

Ey-Chmielewska, H.; Chrusciel-Nogalska, M. & Fraczak, B. Photogrammetry and its potential application in medical science on the basis of selected literature. A*dv. Clin. Exp. Med., 24(4)*:737-41, 2015.

Fahrni, S. & Sabatasso, S. 3D modelling in anatomy teaching: State of the art and pilot investigations for its application. *Transl. Res. Anat., 41*:100444, 2025.

Hoyek, N.; Collet, C.; Di Rienzo, F.; De Almeida, M. & Guillot, A. Effectiveness of three-dimensional digital animation in teaching human anatomy in an authentic classroom context. *Anat. Sci. Educ., 7(6)*:430-7, 2014.

Lee, Y. & Shin, D. Patient-specific 3D modeling for improved understanding of complex fractures and treatment outcomes. *Int. J. Morphol., 43(6)*:1920-6, 2025.

Li, Z.; Yu, J.; Li, Y.; Wang, J. & Wang, C. Three-dimensional printing models improve understanding of spinal fracture—A randomized controlled study. *Spine, 40(15)*:E1041-7, 2015.

Lim, K. H. A.; Loo, Z. Y.; Goldie, S. J.; Adams, J. W. & McMenamin, P. G. Use of 3D printed models in medical education: A randomized control trial comparing 3D prints versus cadaveric materials for learning external cardiac anatomy. *Anat. Sci. Educ., 9(3)*:213-21, 2016.

Long, F. & Ornitz, D. M. Development of the endochondral skeleton. *Cold Spring Harb. Perspect. Biol., 5(1)*:a008334, 2013.

Mikhail, E. M.; Bethel, J. S. & McGlone, J. C. *Introduction to modern photogrammetry.* New York, John Wiley & Sons, 2001.

Morar, S.; Perju-Dumbrava, D. & Cristian, A. Ethical and legal aspects of the use of the dead human body for teaching and scientific purposes. *Rom. J. Bioeth., 6(4)*:75-83, 2008.

Nicholson, D. T.; Chalk, C.; Funnell, W. R. J. & Daniel, S. J. Can virtual reality improve anatomy education? A randomized controlled study of a computer-generated three-dimensional anatomical ear model. *Med. Educ., 40(11)*:1081-7, 2006.

Nikhita; Bannur, D.; Cerdas, M. G.; Saeed, A. Z.; Imam, B. & Thandi, R. S. Efficiency of artificial intelligence in three-dimensional reconstruction of medical imaging. *Cureus, 17(11)*:e96580, 2025.

Rivera, J. & Salinas, P. AutoScan3D: A low-cost, portable photogrammetry system for automated 3D digitization of anatomical specimens. *PLoS One, 20(11)*:e0336996, 2025.

Silén, C.; Karlgren, K.; Hjelmqvist, H.; Meister, B.; Zeberg, H. & Pettersson, A. Three-dimensional visualisation of authentic cases in anatomy learning – An educational design study. *BMC Med. Educ., 22*:477, 2022.

Struck, R.; Cordoni, S.; Aliotta, S.; Pérez-Pachón, L. & Gröning, F. *Application of photogrammetry in biomedical science*. In: Rea, P. (Ed.). Biomedical visualisation. Cham, Springer, pp. 91-101, 2019.

Talevi, G.; Pannone, L.; Monaco, C.; Russo, G.; Rinaldi, A. & Santoro, A. Evaluation of photogrammetry for medical application in cardiology. *Front. Bioeng. Biotechnol., 10*:1044647, 2023.

Tóth, D.; Petrus, K.; Heckmann, V.; Simon, G. & Poór, V. S. Application of photogrammetry in forensic pathology education of medical students in response to COVID-19. *J. Forensic Sci., 66*:1533-7, 2021.

Zuñiga, J.; Barragán-Acosta, A.; Solís, R. D.; Calvo, P. & Osorio, T. S. Construction of a 3D model of the tracheobronchial tree for teaching learning human gross anatomy. *Int. J. Morphol., 42(6)*:1793-800, 2024a.

Zuñiga, J. R.; Osorio-Toro, S. & Pérez, L. E. How medicine and surgery students learn human macroscopic anatomy. *Int. J. Morphol., 42(5)*:1382-93, 2024b.

Corresponding author:
Jelen Vanessa López-Patiño
Calle 4B # 36 – 00
Department of Morphology
School of Basic Sciences
Universidad del Valle
Cali
COLOMBIA

E-mail: Jelen.lopez@correounivalle.edu.co